



Radiology Techniques Department

Radiographic imaging

Principle of radiography

Lecture 1

د. حيدر سعيد شندل


M.B.CH.B MSc. RAD. (ASU)

The discovery of x-ray

The X-Ray was discovered in November of **1895** by **Wilhelm Konrad Roentgen**.

With a few weeks he was able to characterize the nature of x-ray to nearly the level of understanding that we have today, this early work gained him the first **Nobel prize** for physics in **1902**.

Roentgen immediately recognized the potential diagnostic medical applications of his new "**X-Light**". He produced first radiography, that of his **wife's hand**.

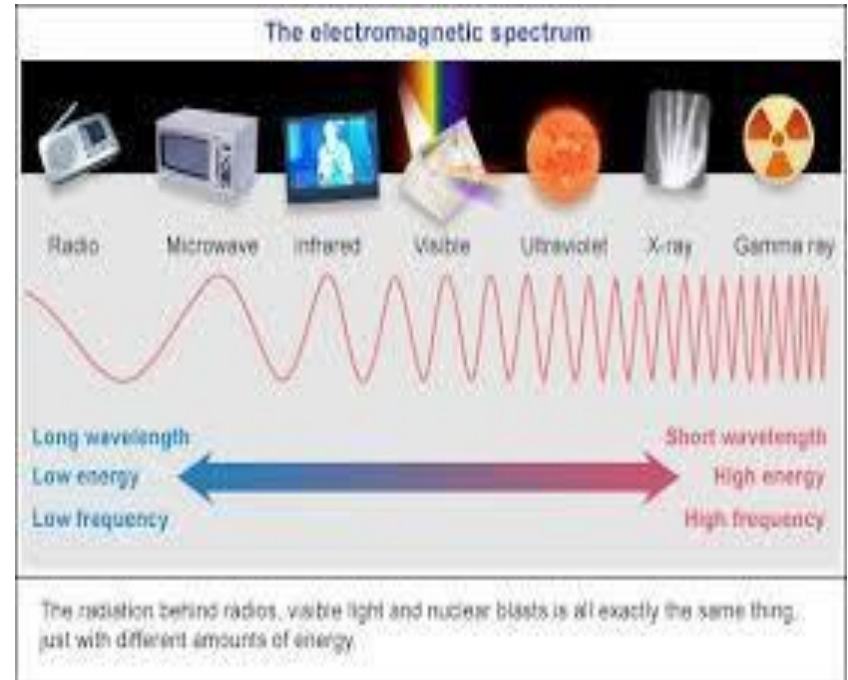


P.P

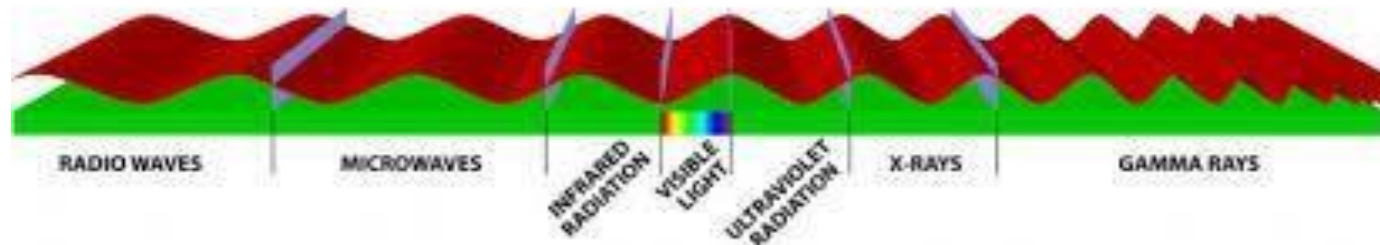
Wilhelm Konrad Röntgen.

Nature of x-ray

x-ray from a part of the spectrum of electromagnetic radiation. Where the long waves electric and radio waves are found at the one end. The infrared, visible light and ultraviolet light waves in the middle. X-ray, gamma ray and cosmic at the short wave length end.

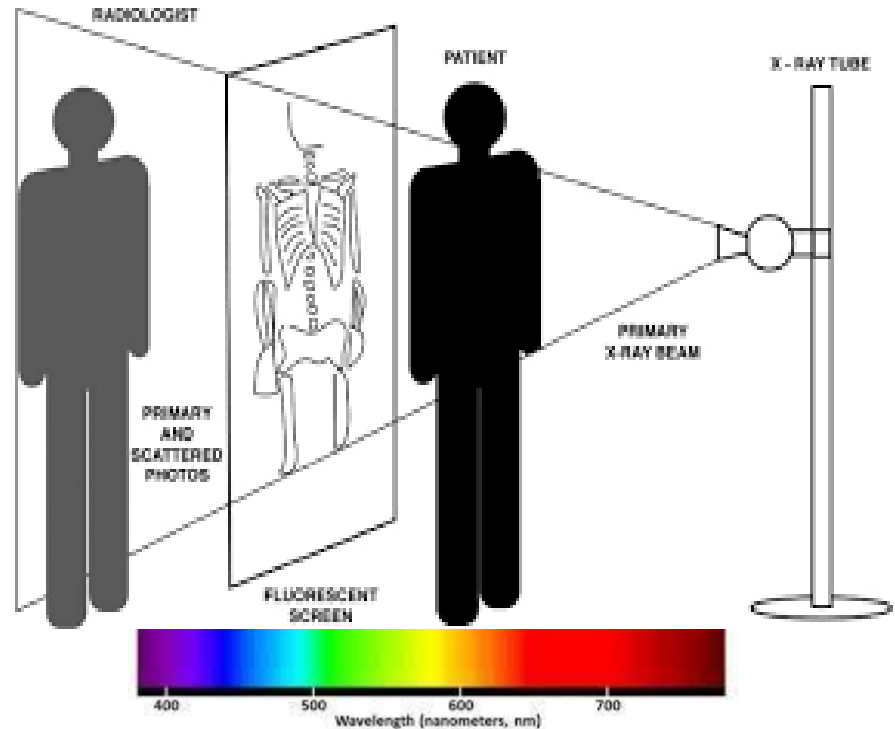


ELECTROMAGNETIC SPECTRUM



Different between x-ray and visible light

x-ray resemble visible light rays, but have **very short wave**, the x-ray wave is only about **1/10000** the wave length of the visible light, with this characteristic. The x-ray is **able to penetrate material** with visible light cannot penetrate.



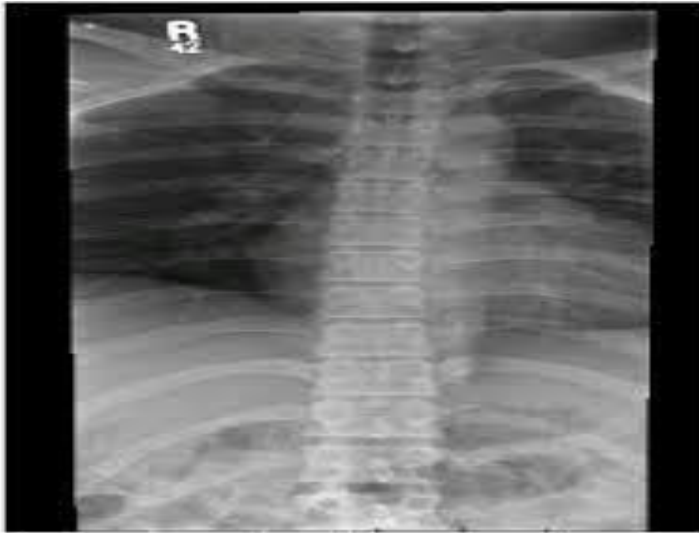Radiolucency and Radiopacity

X-ray cannot penetrate all materials with same ability. Some substances such as **fats** and **gases** are more readily penetrated than other such as heavy metals such as **bone**.

Radiolucency and Radiopacity

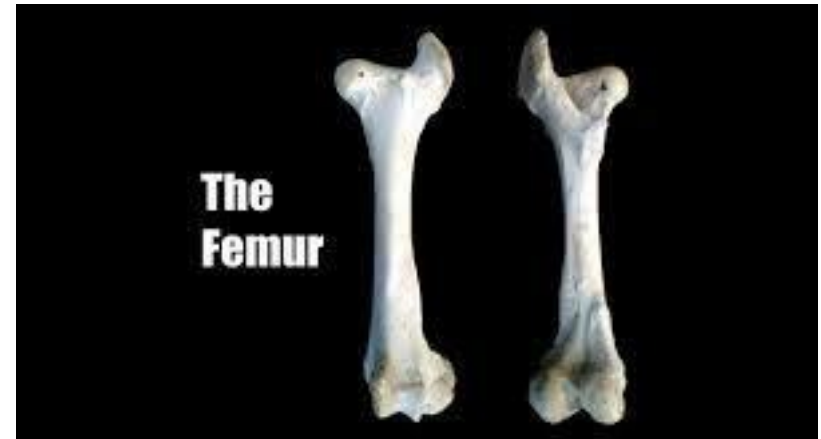Radiolucency

Radiolucency: refers to matter which is penetrate easily by x-ray, thus appear **black** on the x-ray film.



Radiopacity (Radio-opaque)

Radiopacity (Radio-opaque): is descriptive of matter in which x-ray absorbed, thus appear **white** on the x-ray film.

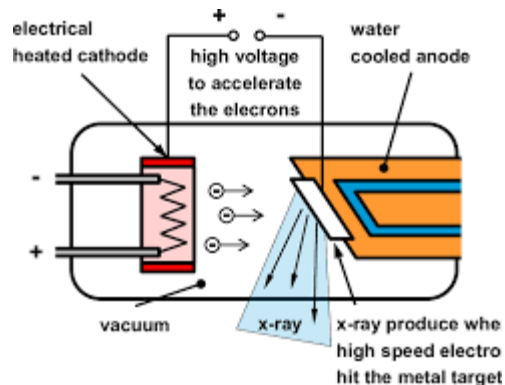


The production of x-ray

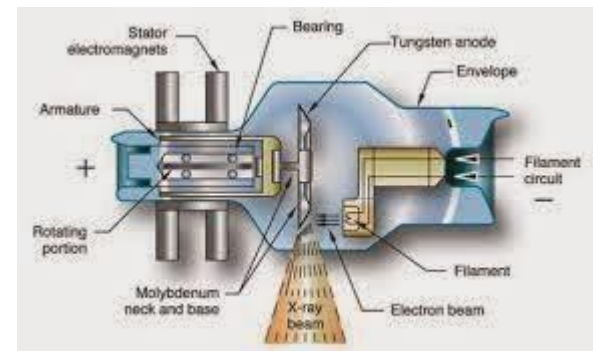
In order to produce x-ray one must obtain electrons, and allows these electrons to strike a target with sufficient energy, this is a complex physical process in which most of the electrons produce x-ray and heat.

-**X-ray** is less than one percent (**1%**).

-**Heat** is about ninety percent (**99%**).



1. The device in which x-ray is produced, called the **x-ray tube**.
2. The x-ray tube consist of:
3. An evacuated glass bulb.
4. A negative electrode called; **Cathode**.
5. A positive electrode called; **Anode**.
6. A spiral wire of Tungsten called; **Filament**, which when heated emit electrons.
7. A means of cooling the heat produced when the electrons made strike their target (Anode).





Radiology Techniques Department

Radiographic imaging

Principles of planes

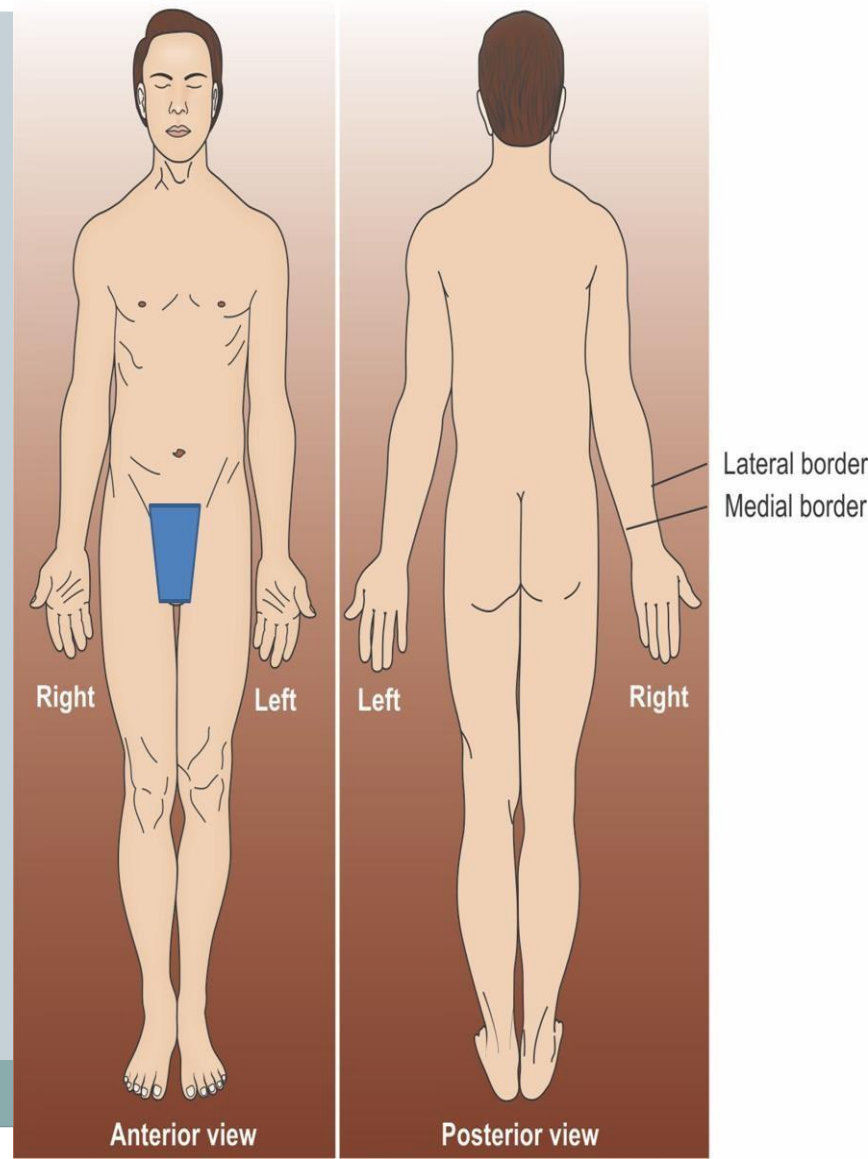
Lecture 2

د. حيدر سعيد شندل

M.B.CH.B MSc. RAD. (ASU)

ANATOMICAL POSITION

The **anatomical position** is a standardized method for observing or imaging the body.



ANATOMICAL POSITION



1. Usual bipedal erect position
2. Upper limbs hangs adducted and palms faces anteriorly.
3. Eyes facing forwards.
4. Feet remain parallel on the same level

Imaging



❖ *Scanning :*

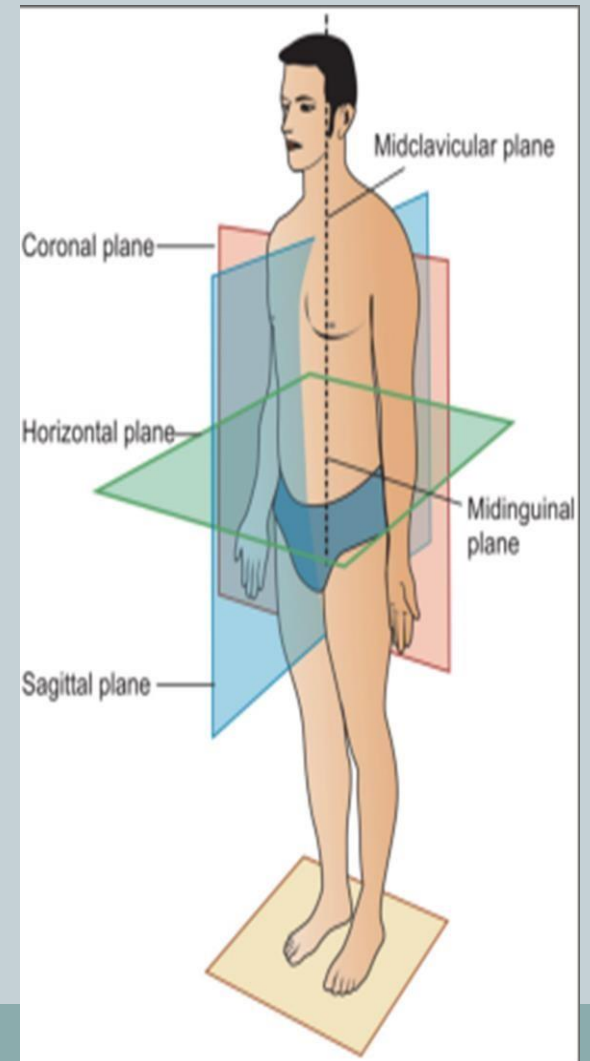
- ✓ Ultrasonography
- ✓ Echocardiography
- ✓ Computerized Axial Tomography
(CAT or CT Scan)
- ✓ PET Scan
- ✓ Magnetic Resonance Imaging (MRI)

Planes of the Body



Planes:

are imaginary flat surfaces that are used to divide the body or organs into definite areas.

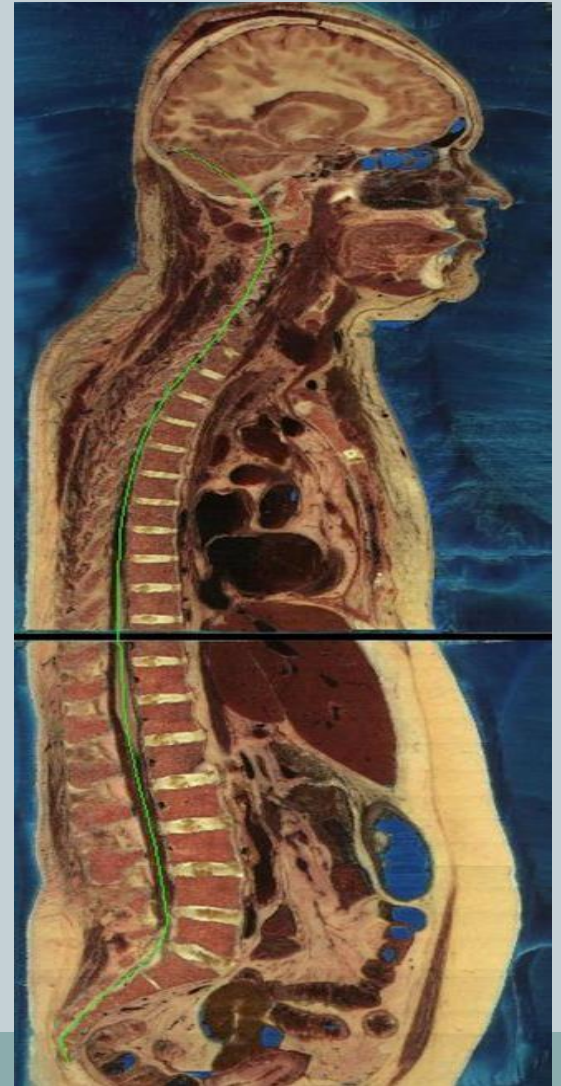


Planes of the Body

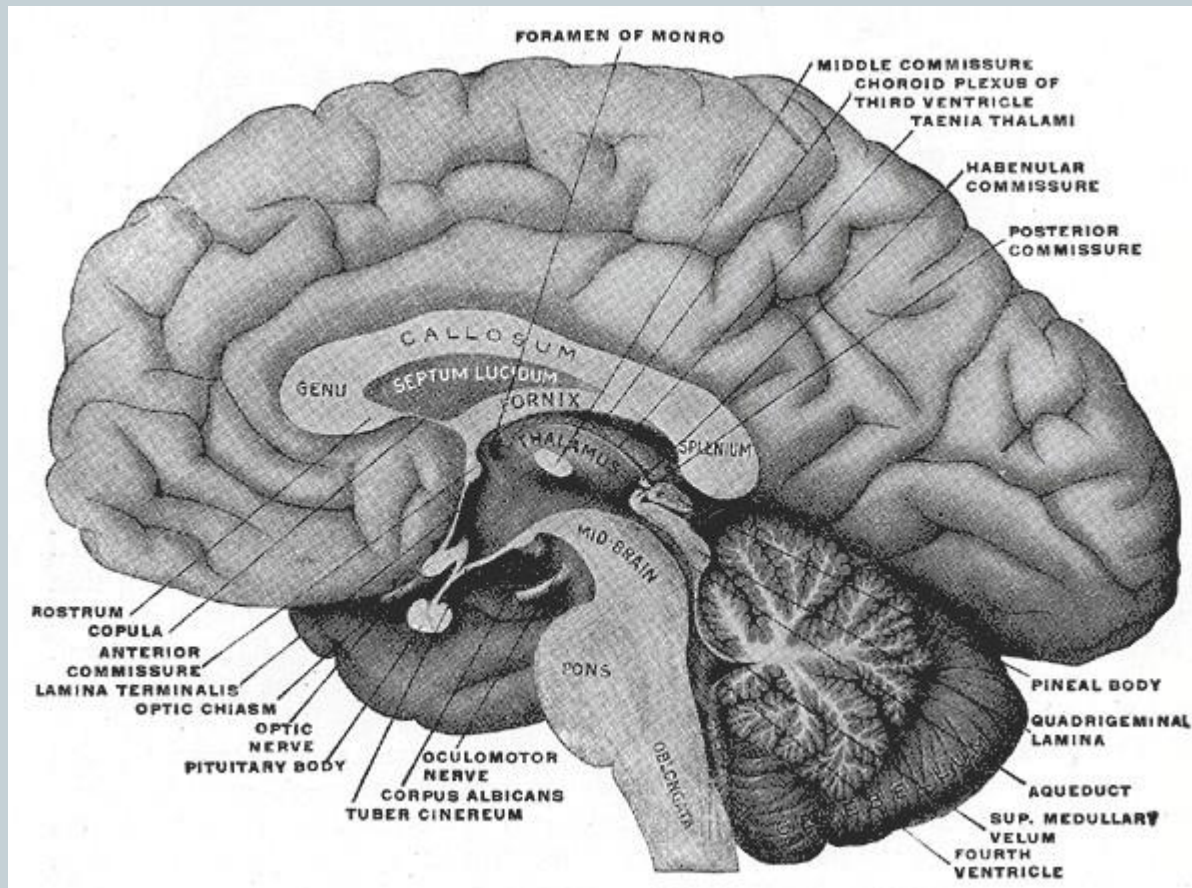


1. **Median plane:** **(Sagittal plane)**

It divides the body vertically into equal right and left halves



Planes of the Body

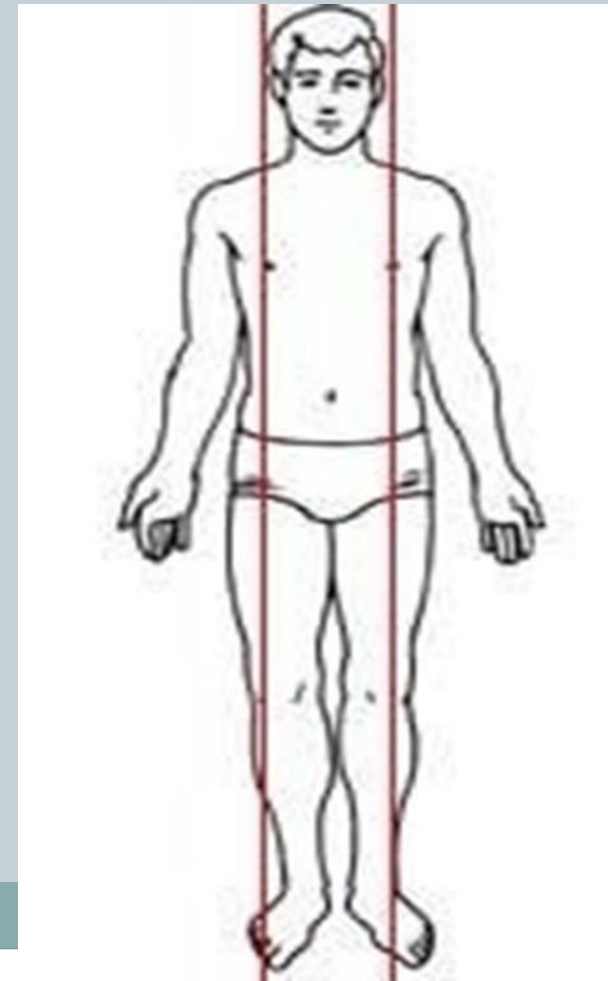


Planes of the Body



2. Paramedian or parasagittal plane:

Any vertical plane, parallel to the median plane of the body. It divides the body into unequal right and left portions.




Planes of the Body



3. Coronal plane: (frontal plane)

It is the vertical plane at right angle to the median plane.

Divides the body into anterior and posterior parts.

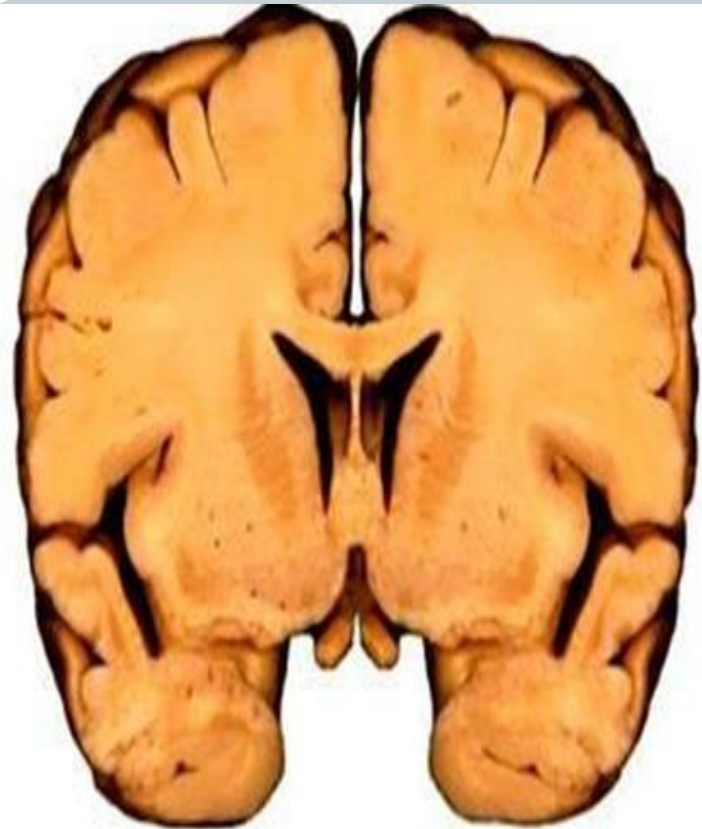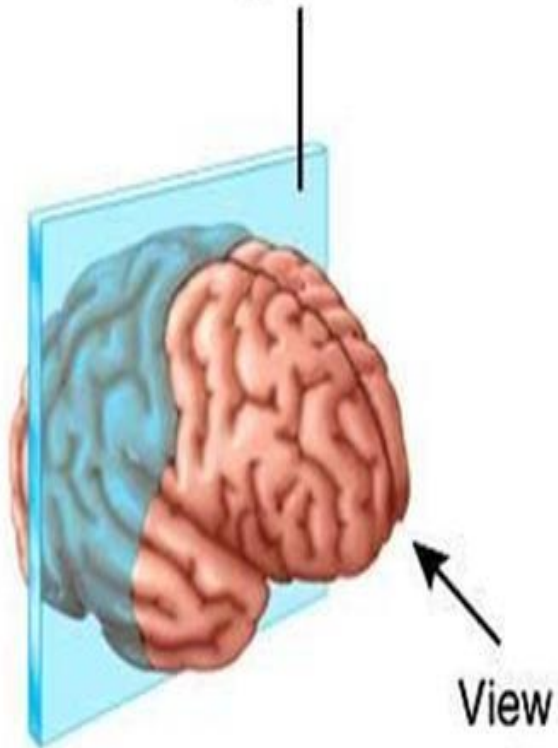


Planes of the Body



(b)

Frontal plane



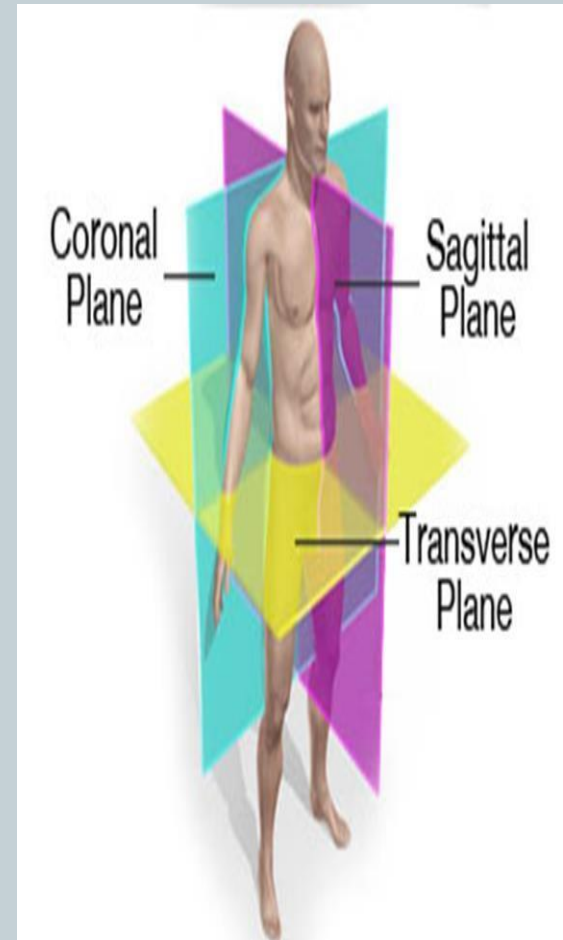
Frontal section

Planes of the Body

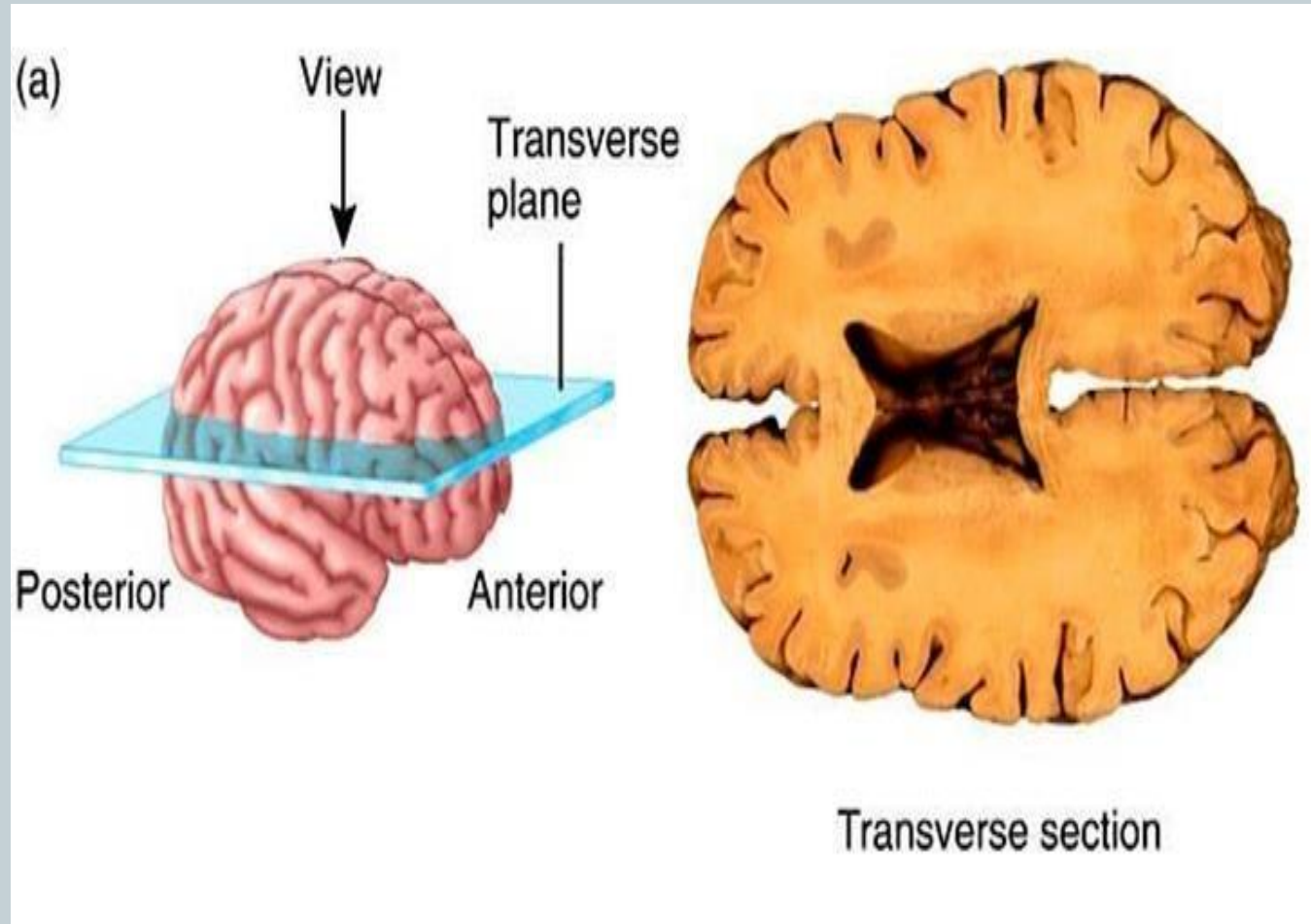
4. **Horizontal plane: (Transverse plane)**

It is the transverse plane of the body at right angle to the (sagittal) and coronal planes.

It divides the body into upper and lower parts.



Planes of the Body

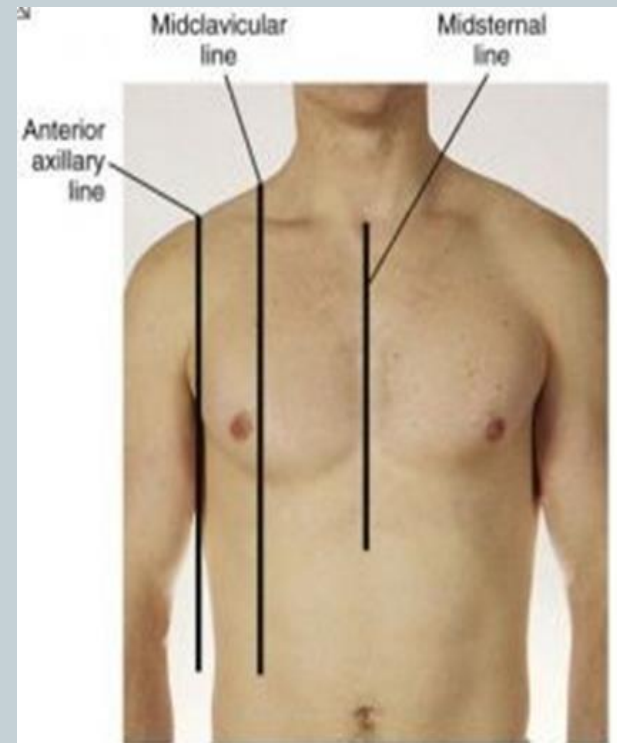


Planes of the Body

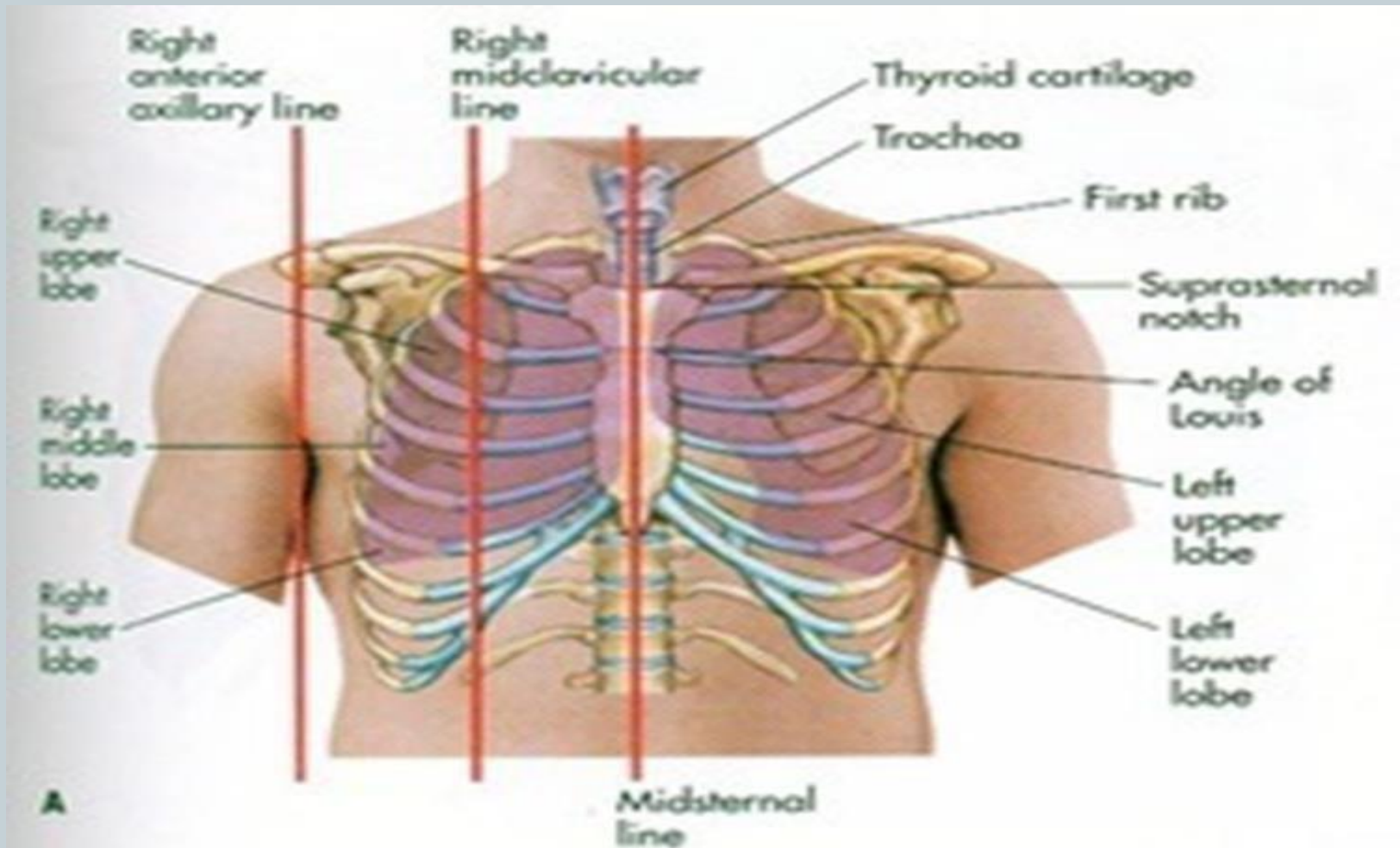


5. **Midclavicular plane or midmammary line:**

It is the line that passes through the midpoint of clavicle downwards



Planes of the Body

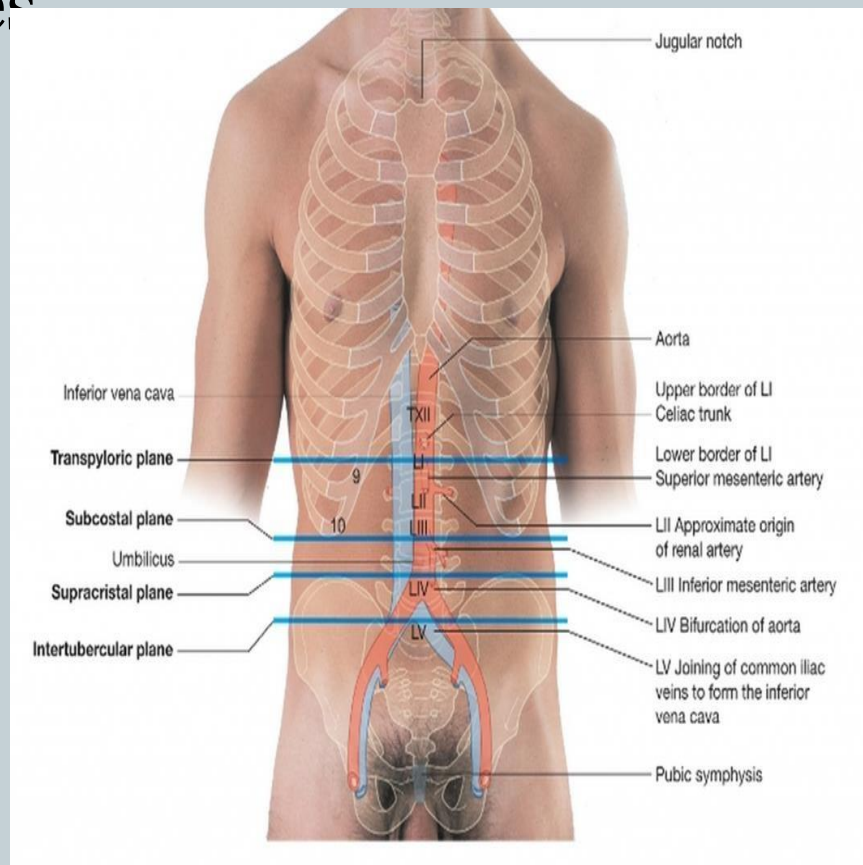


Planes of the Body

6. Transpyloric plane: It is the line passing through the tips of 9th costal cartilages

It lies at the level of pylorus of stomach.

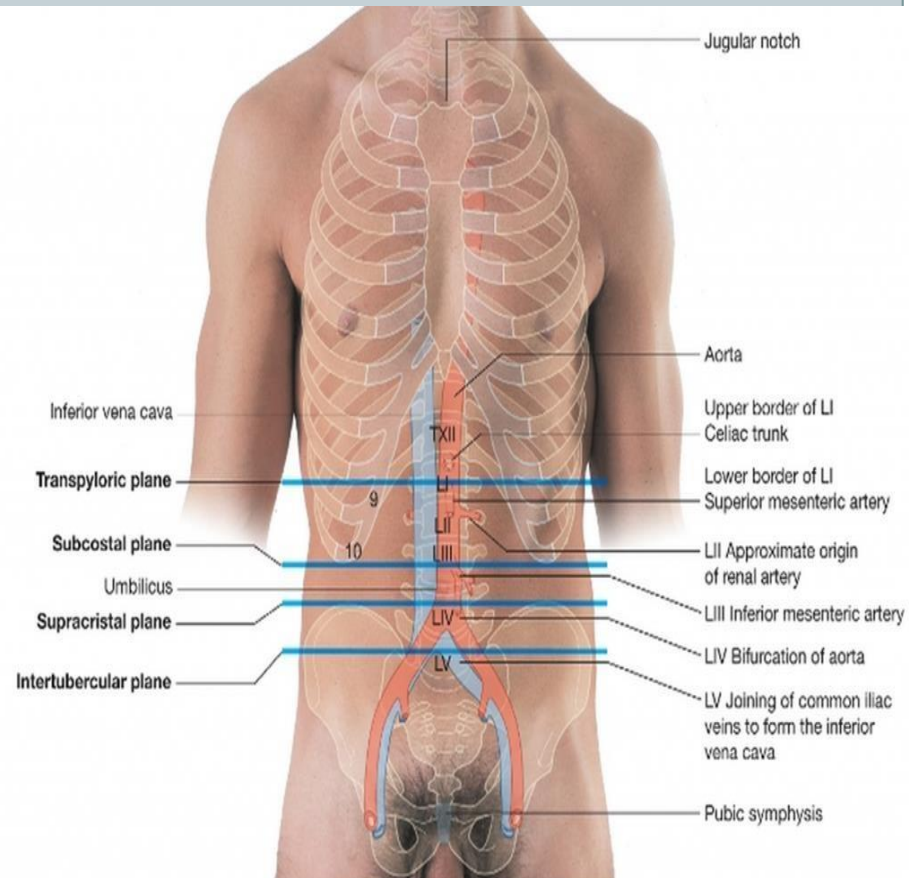
Vertebral level: L1



Planes of the Body

7. **subcostal plane:** It is the line passing through the lowest point of costal margin.

It lies at the level of 3rd lumbar vertebra

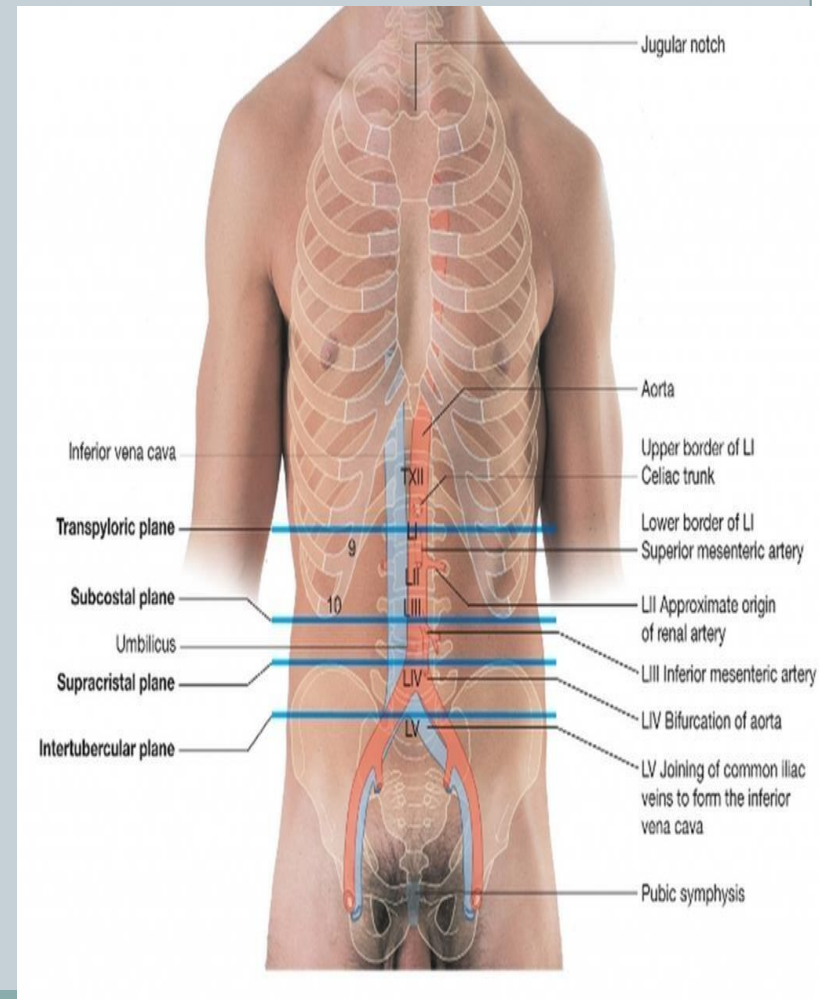


Planes of the Body

8. **supracristal plane:**

It is the line joining the highest point of iliac crests.

It lies at the level of 4th lumbar vertebra

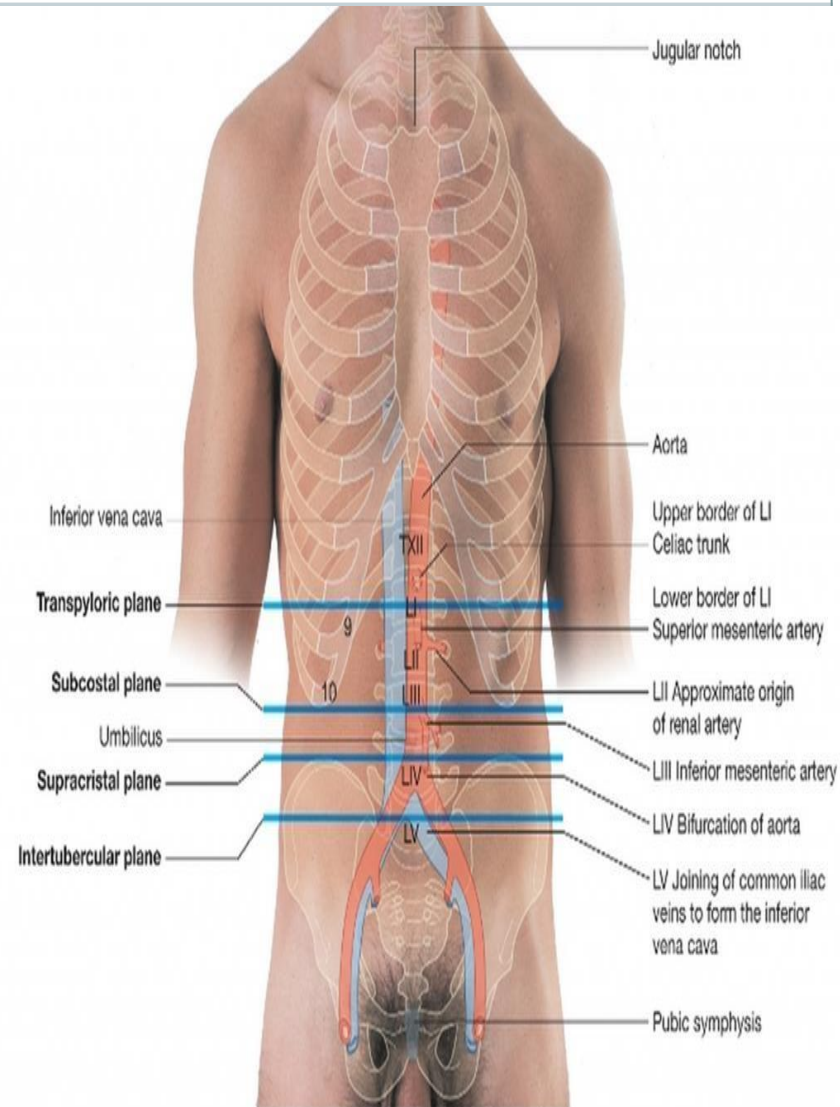


Planes of the Body

9. **Transtubercular plane:**

It is the line passing through the abdomen joining the tuberosities of iliac crest

- Vertebral level :
Body of L5







Radiology Techniques Department

Radiographic imaging

MSC Positions and body movement

Lecture 4

د. حيدر سعيد شندل

M.B.CH.B MSC. RAD. (ASU)



General Terms

- **Radiograph:** An image of a patient's anatomic part(s), as produced by the action of x-rays on an image receptor
- If the radiograph is produced with the use of film-screen technology, the image is stored traditional and displayed on film, if the radiograph is produced via digital technology, the image is viewed and stored with the use of computers.
- **Radiography:** The process and procedures of producing a radiograph
- Radiograph versus x-ray film: In practice, the terms radiograph and x-ray film (or just film) are often.



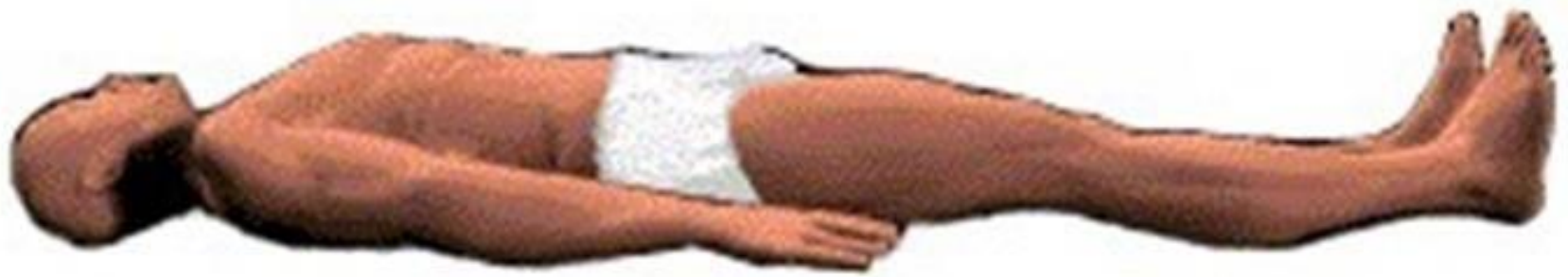- **Image receptor (IR):** The device that captures the radiographic image that exits the patient refers to
- both film-screen cassettes and digital acquisition devices.
- **Central ray (CR):** Refers to the center-most portion of the x-ray beam emitted from the x-ray tube.

TERMINOLOGY

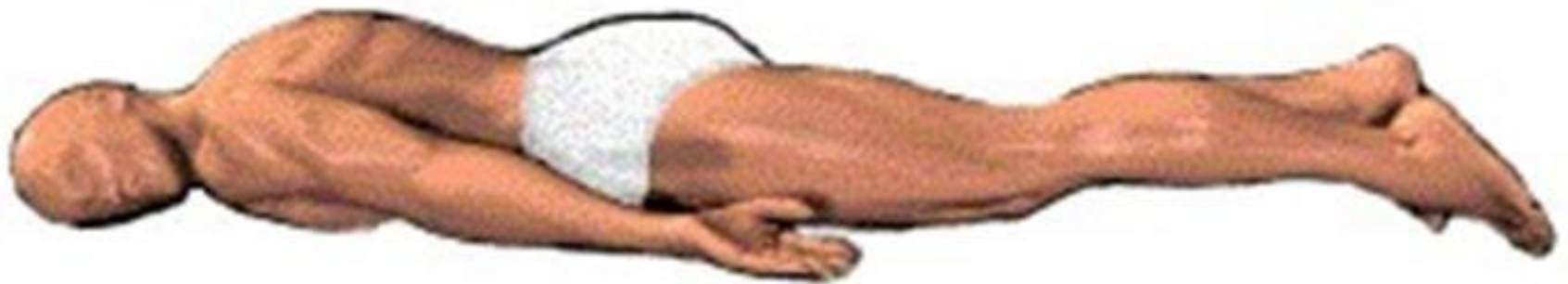

➤ Reclining Position

- If the body is lying face down, it is in the *prone* position.
- If the body is lying face up, it is in the *supine* position.



Supine



Prone

TERMINOLOGY



Erect:

the projection is taken with the patient sitting or In the erect position, the patient may be standing or sitting

- with the **posterior aspect** against the Cassette or
- with the **anterior aspect** against the cassette
- with the **right or left side** against the cassette.





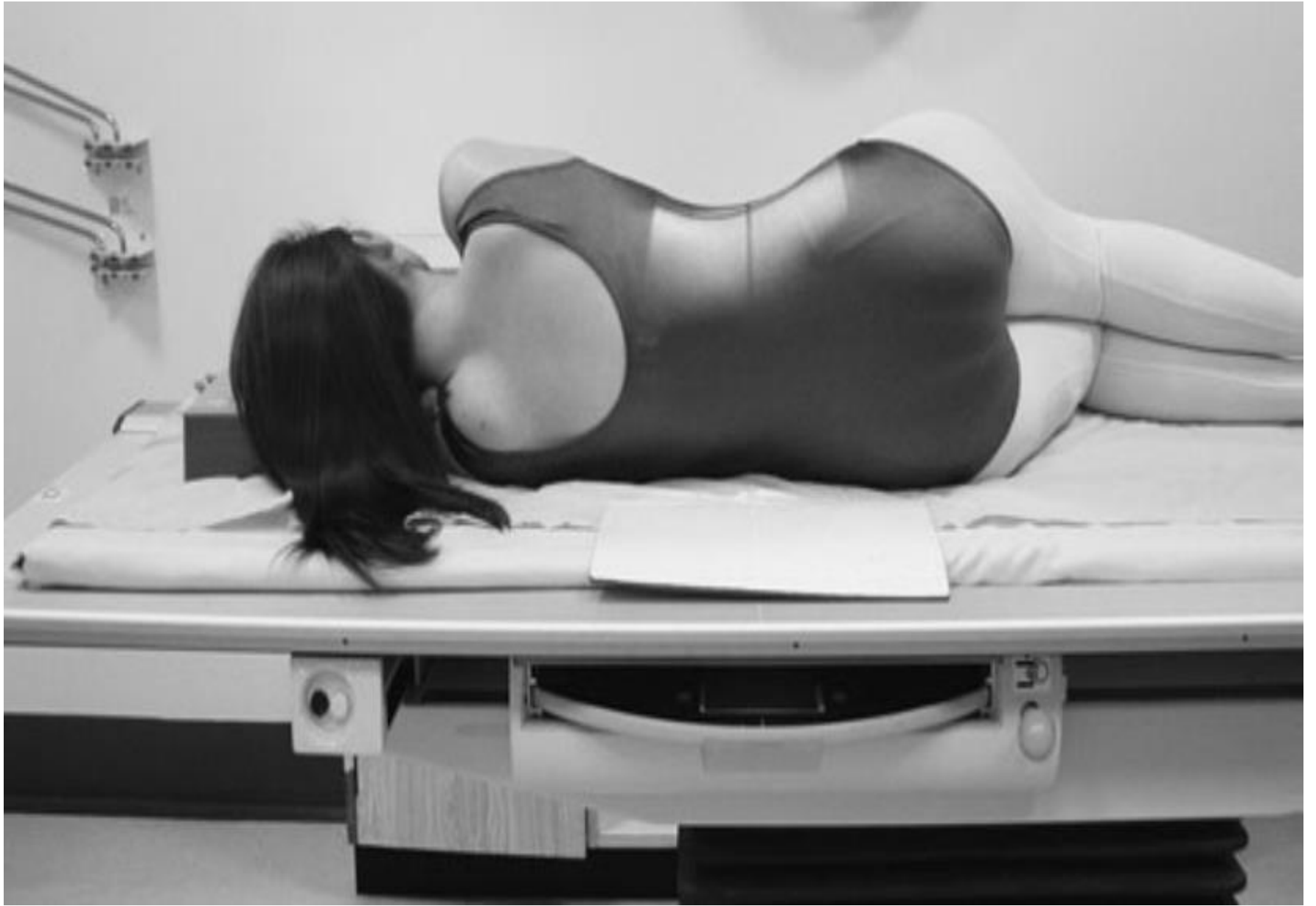Decubitus:

The patient is lying down. In the decubitus position the patient may be lying in any of the following positions:

- **Supine** (dorsal decubitus): lying on the back.
- **Prone** (ventral decubitus): lying face down
- **Lateral decubitus**: lying on the side.

Right lateral decubitus  lying on the right side.

Left lateral decubitus  lying on the left side.





Anterior oblique

The central ray enters the posterior aspect, passes along a transverse plane at some angle to the median sagittal plane, and emerges from the anterior aspect.

The projection is also described

by the side of the torso closest to the cassette.

the left side is closest to the cassette, and therefore the projection is described as a left anterior oblique





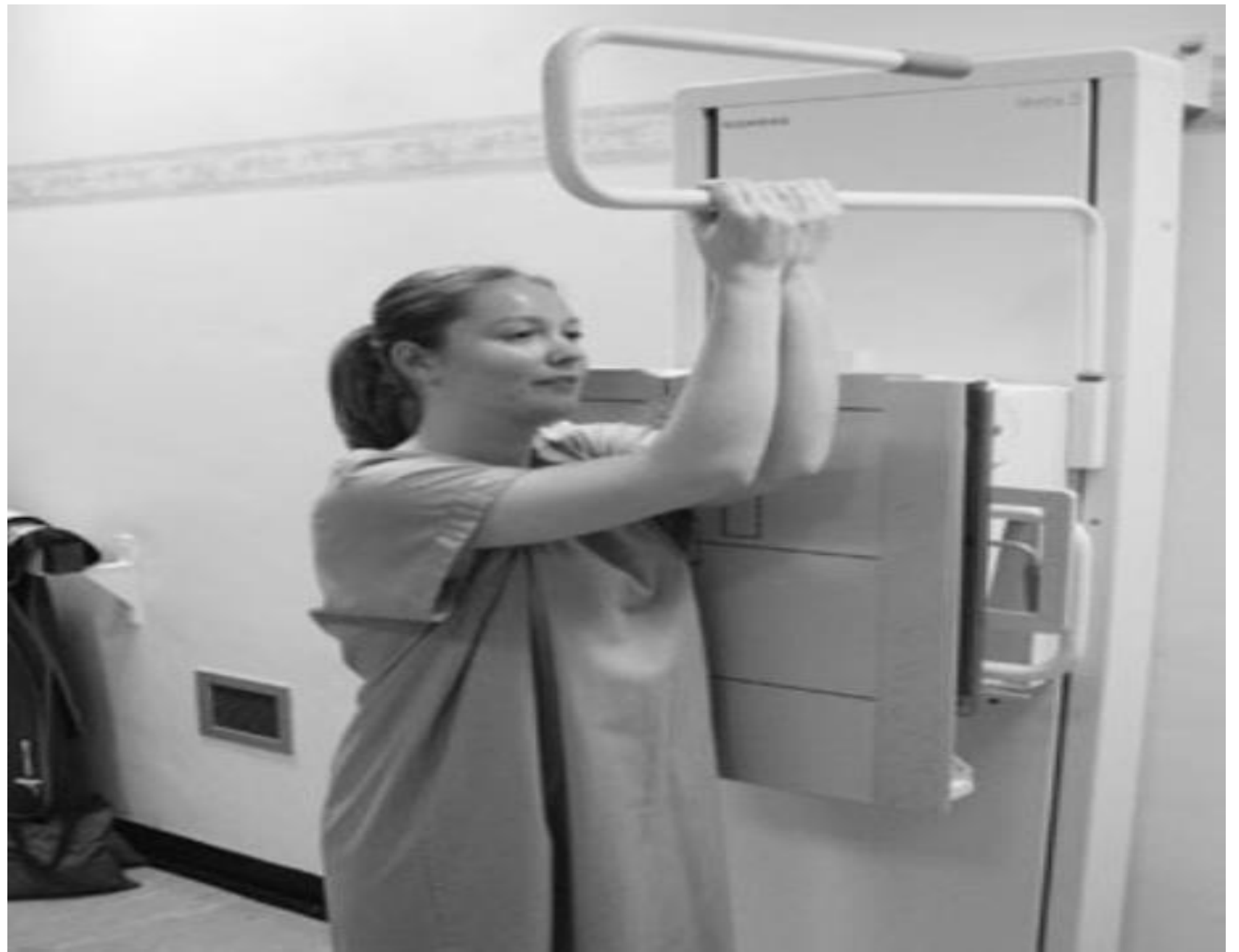Projection: left lateral

Position erect

Left side against the cassette and
median sagittal plane parallel to the cassette

Direction and centring of X ray beam:

the central ray is directed horizontally
(at right angles to the median sagittal plane)





Projection: postero anterior (PA)

Position: erect

Anterior aspect facing the cassette and median sagittal plane at right angles to the film Direction

Centring of X ray beam: the central ray is directed horizontally (along the median sagittal plane)



REGIONAL NAMES



- Are names given to specific **regions** of the body for reference.
- Examples: include
 - cranial (skull),
 - thoracic (chest),
 - brachial (arm),
 - patellar (knee),
 - cephalic (head),
 - gluteal (buttock)

Review directional terminology

Anterior x Posterior
Medial x Lateral
Superior x Inferior
Proximal x Distal
Superficial x Deep
Cephalic x Caudal



Film sizes in inches: ●

1-8 x 10 inches ●

2-10 x 12 inches ●

3-12 x 15 inches ●

4 14 x 14 inches ●

5 14 x 17 inches ●

6-6 x 15 inches ●

DIRECTIONAL TERMS



1. *Anterior* : Towards the front
2. *Posterior* : Towards the back
3. *Superior* : Towards above
4. *Inferior* : Towards below
5. *Medial* : Towards midline or median plane
6. *Lateral* : Away from median plane

DIRECTIONAL TERMS



7. *Ventral* : Front of the body, i.e. toward abdomen
8. *Dorsal* : Towards the back
9. *Cranial* : Towards the Head
10. *Rostral* : Same as cranial
11. *Caudal* : Towards the Tail
12. *Proximal* : Close to the center (origin)
13. *Distal* : Away from the center (origin)

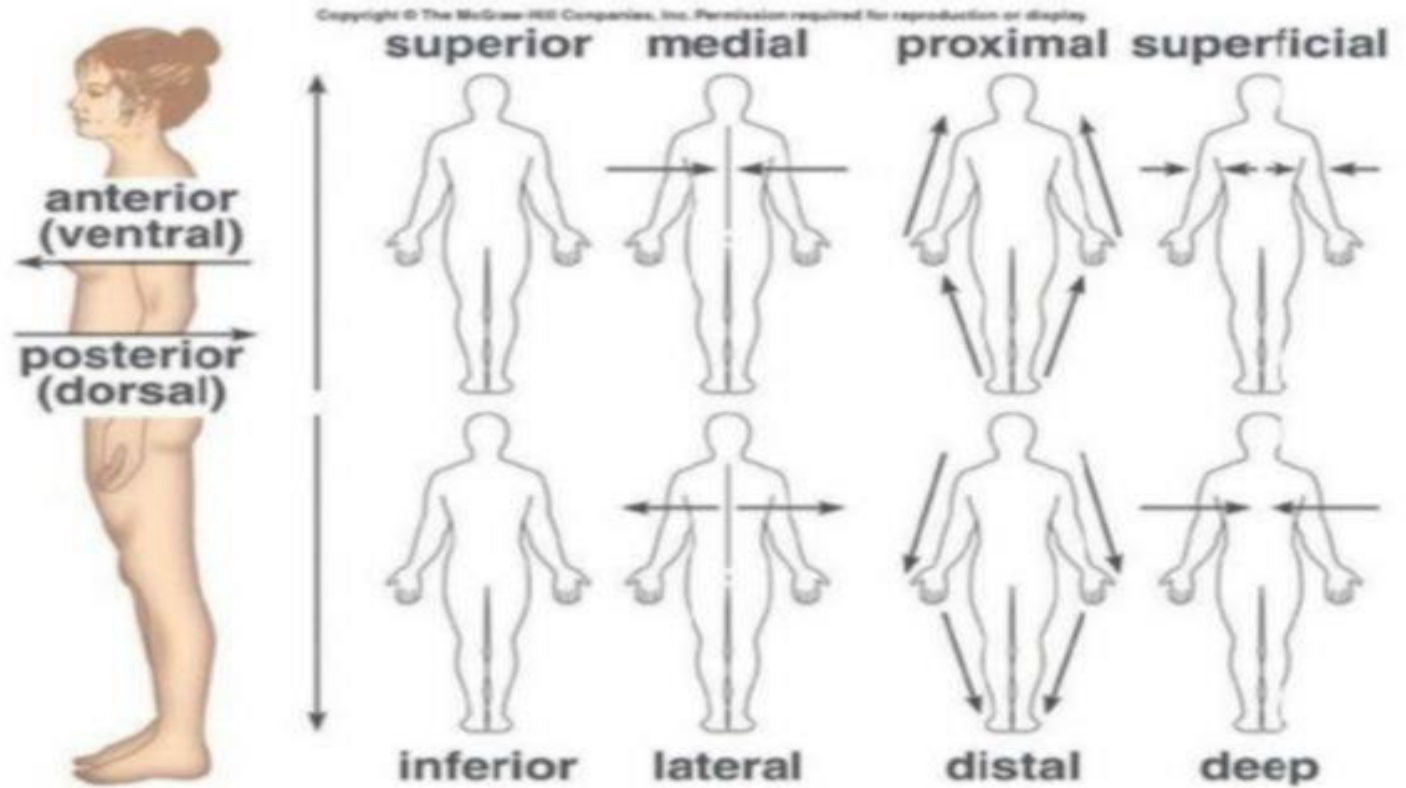
DIRECTIONAL TERMS



14. *Intermediate*: between 2 points
15. *Ipsilateral*: same side
16. *Contralateral*: opposite side
17. *External* (Outer)
18. *Internal* (Inner)
19. *Central*
20. *Peripheral*

Describe the directional terminology

Fig. 1.2



Terms of movement



- *Flexion:*

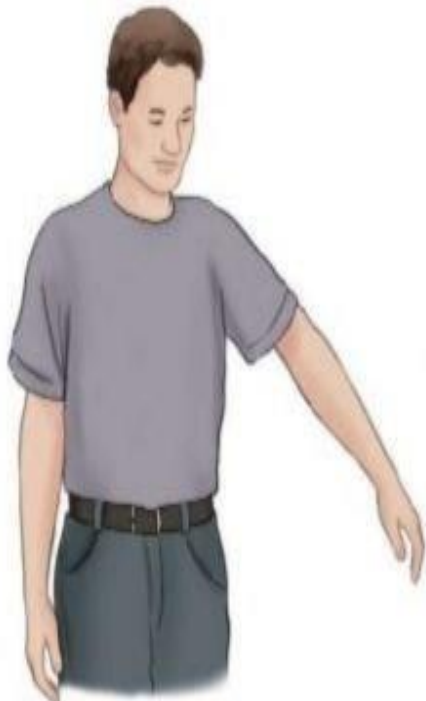
A bending movement around a joint in a limb (as the knee or elbow) that decreases the angle between the bones of the limb at the joint.

- *Extension:*

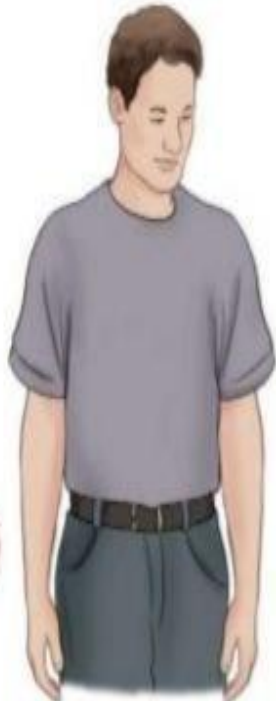A distending movement around a joint in a limb (as the knee or elbow) that increases the angle between the bones of the limb at the joint.

- *Inversion:*

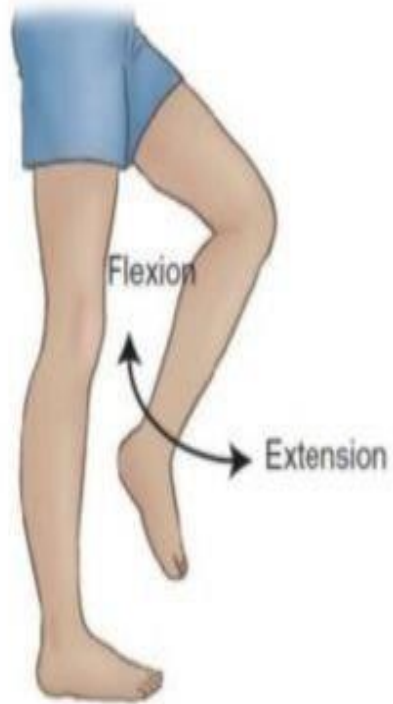
The condition (as of the foot) of being turned or rotated inward.



Abduction
(away from)



Adduction
(toward)



Flexion

Extension



Flexion

Extension



- *Eversion:*

The condition (as of the foot) of being turned or rotated outward.

- *Supination:*

rotation of the forearm and hand so that the palm faces forward or upward and the radius lies parallel to the ulna

- *Pronation:*

rotation of the hand and forearm so that the palm faces backwards or downwards.

- *Circumduction:*

movement of a limb or extremity so that the distal end describes a circle while the proximal end remains fixed



- *Abduction:*

Lateral movement away from the midline of the body.

- *Adduction:*

Movement towards the median plane of the body.

- *Protraction:*

Gliding motion anteriorly

- *Retraction:*

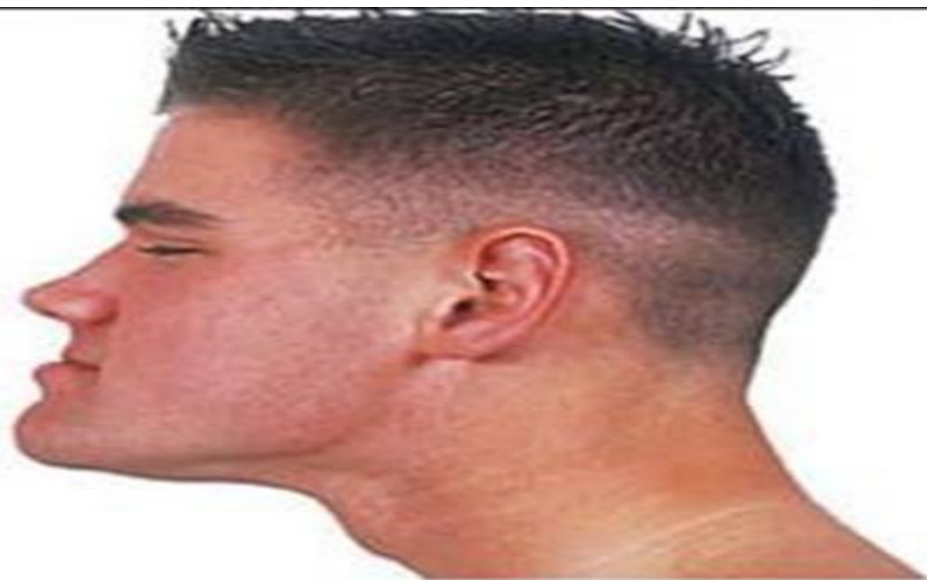Moving structure back to anatomical position.

- *Elevation: raising*


- *Depression: lowering*

- *Rotation:*

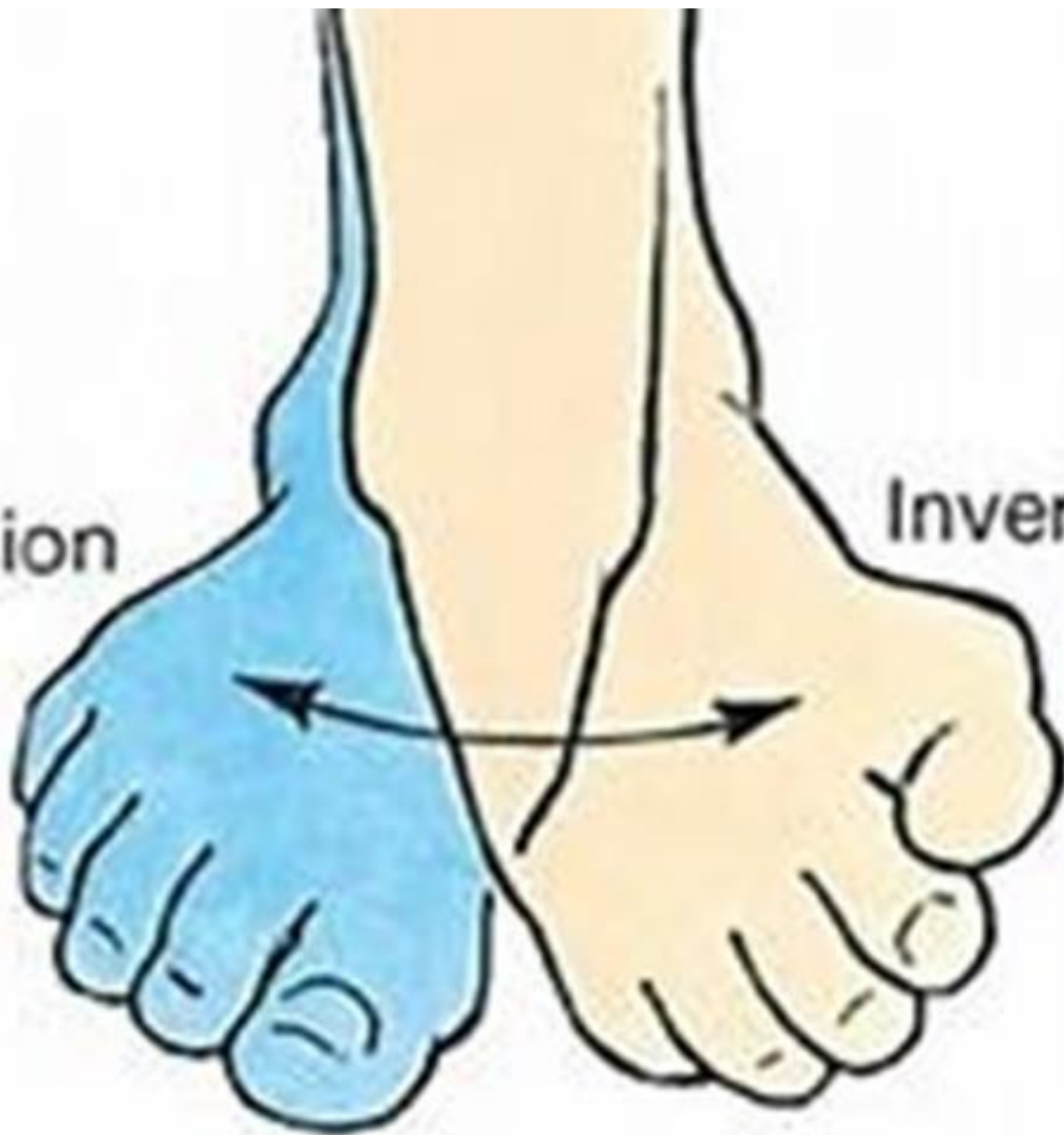
Protraction



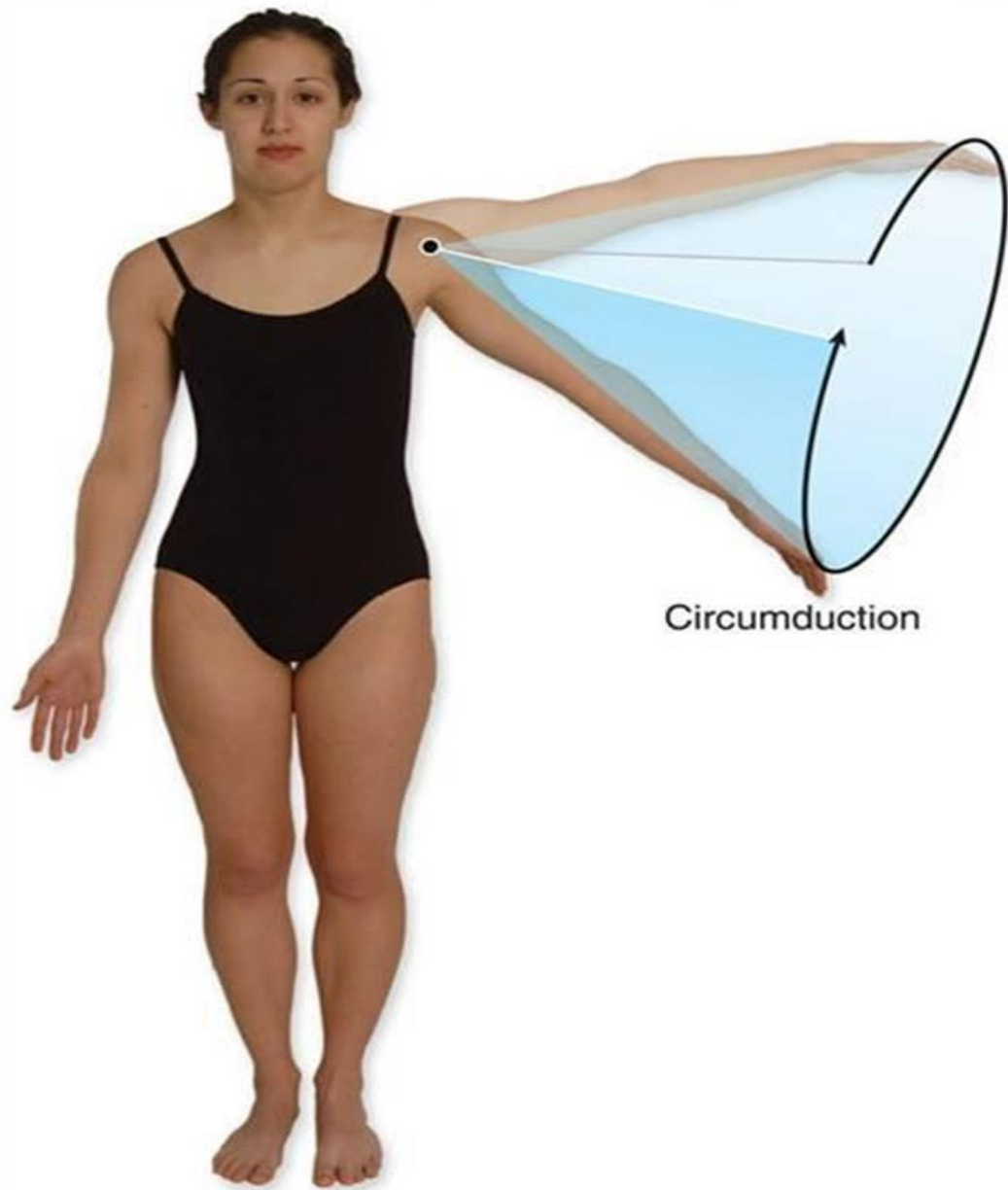Retraction



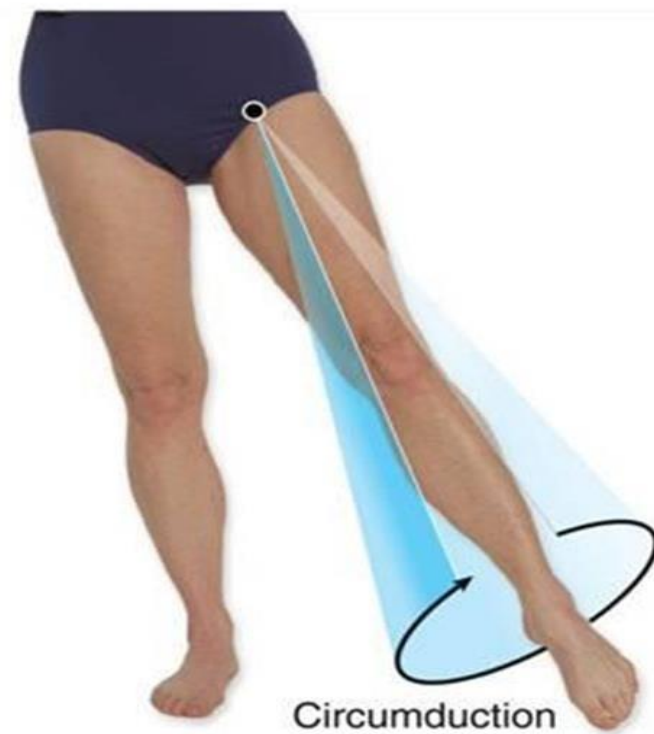Eversion



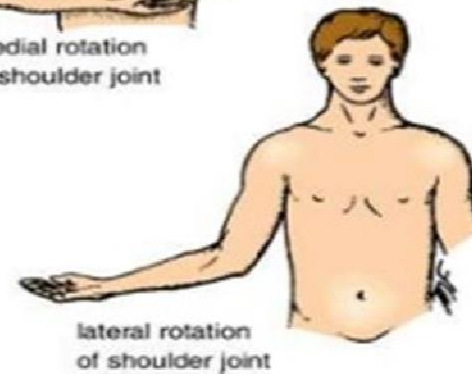
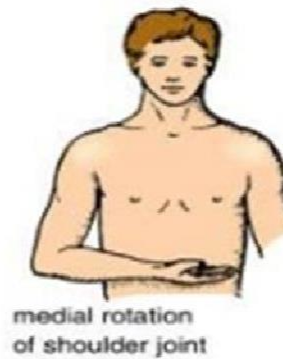
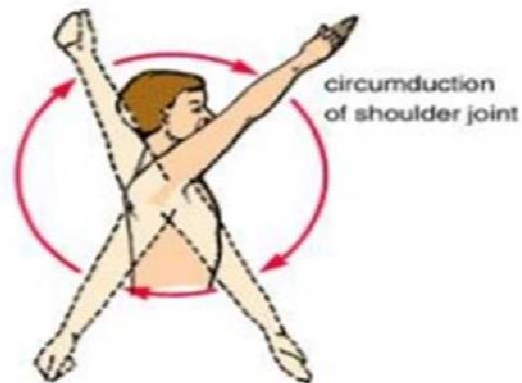
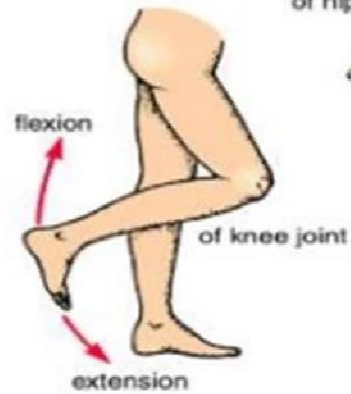
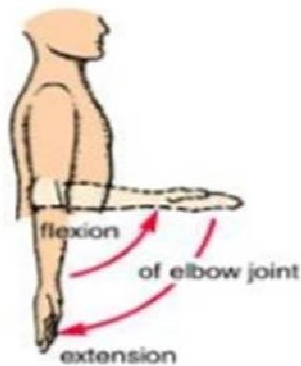
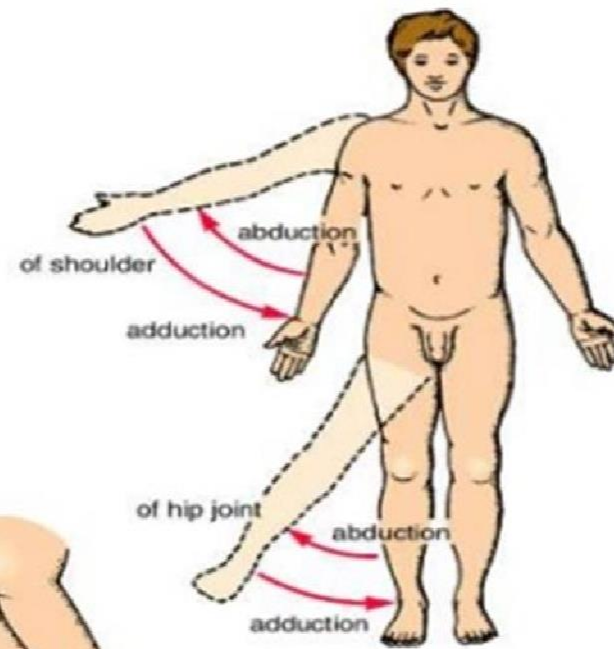
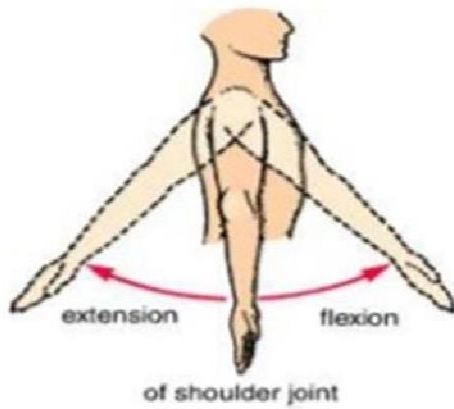
Inversion

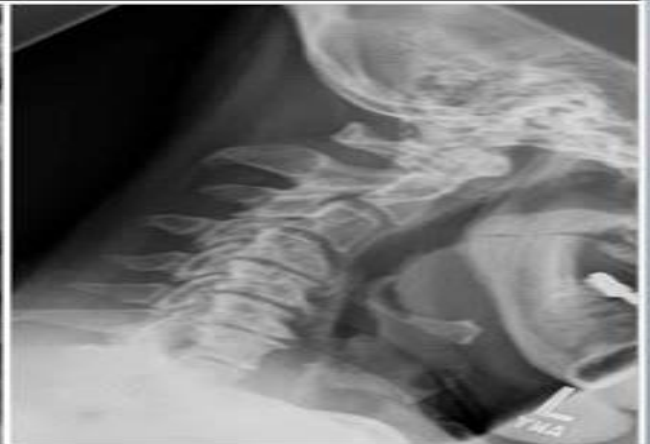
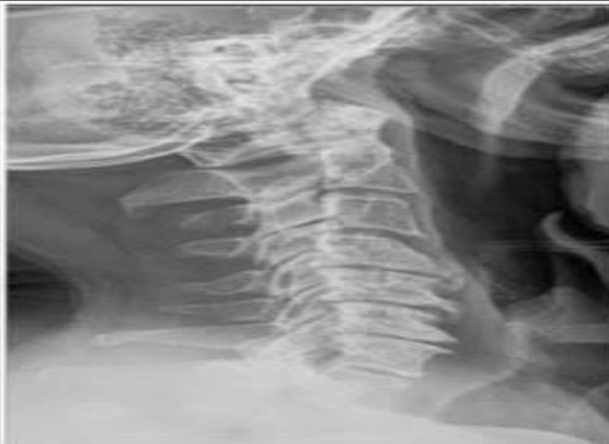
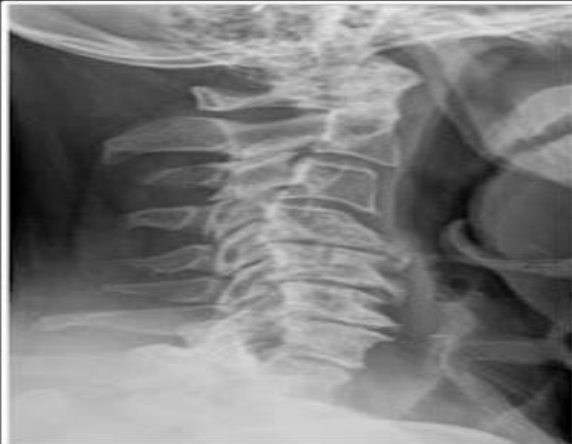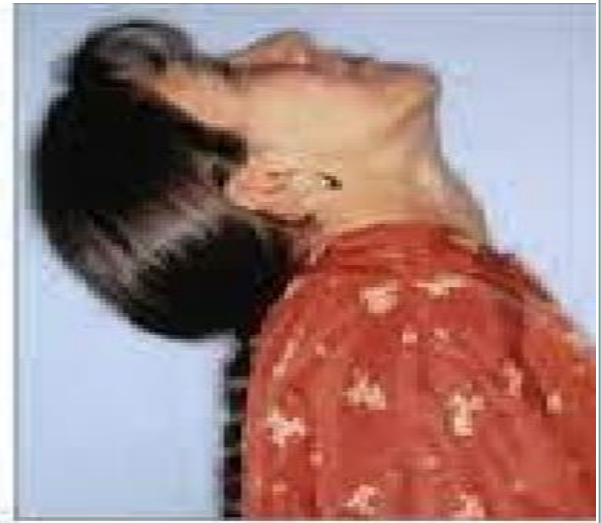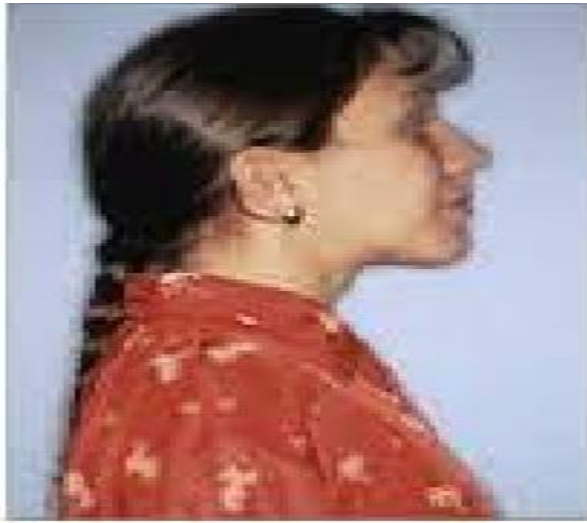(a)



(b)





Thank
you!





Radiology Techniques Department

Radiographic imaging

Conventional imaging technology

Lecture 4

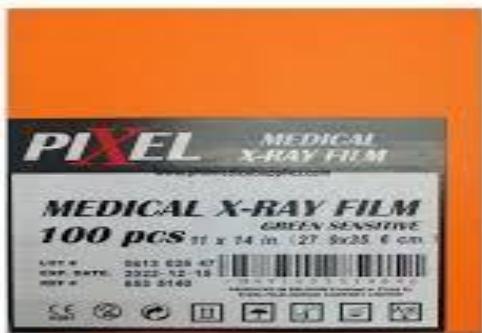د. حيدر سعيد شندل

M.B.CH.B MSc. RAD. (ASU)

Analog (Conventional Imaging Technology)

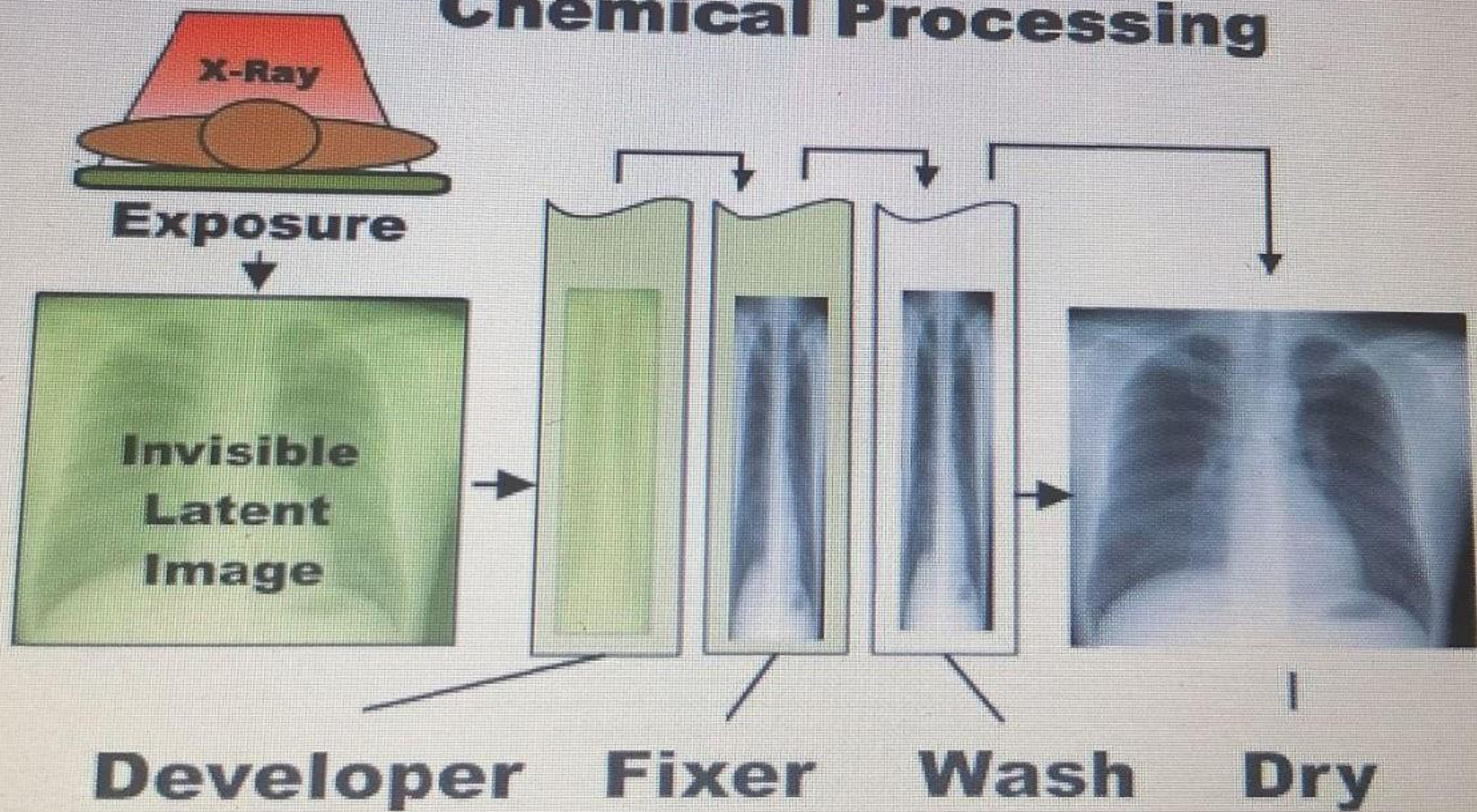


This is the traditional method that is often referred to film-based radiography the need for processing chemicals, the use of a **dark room**, the need for human resources, as well as the difficulty to maintain high quality images are all factors that limit the wide-scale use of this method



Analog Technology

Chemical Processing



Digital (Computed) Imaging Technology

- This technology eliminates the need for dark-room and chemical processing of the film , since reusable phosphor plates are used as image receptors and are scanned by CR reader (digitizer with laser scanner) laser scanner (CR-reader) convert the stored information into digital



Exposure factor

a set of exposure factors has to be chosen to give the type of image required.

The choice of these factors will depend on the region being examined, including its **thickness, density, pathology, etc.**

The exposure factors to be selected are:

- 1- milliamperere second(mAs)
- 2 kilovoltage(KV)
- 3 focus film distance(FFD)

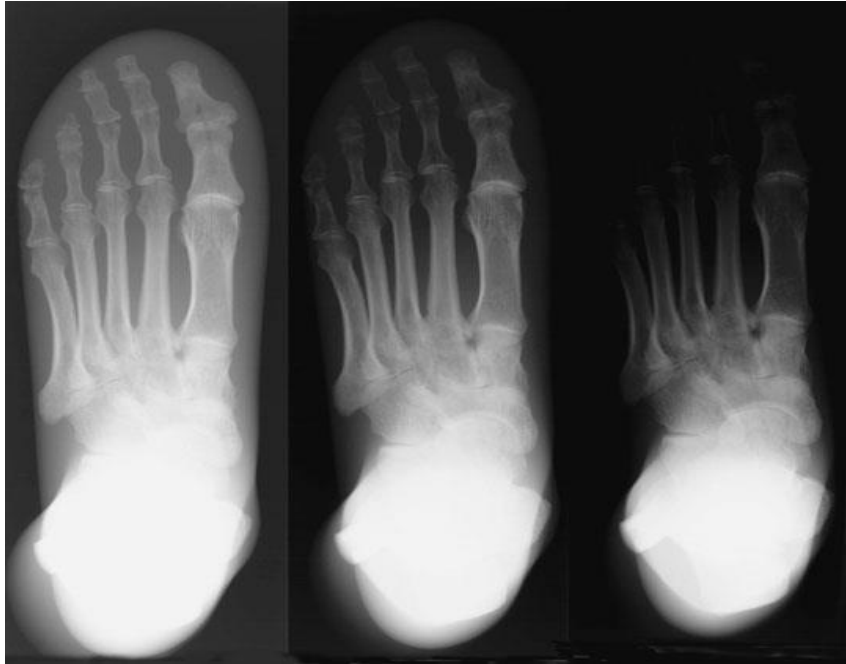mAs

is a product of the X ray tube current (**mA**) and exposure time (**seconds**). The mA should be as high as possible with a short time, to reduce the risk of movement un sharpness

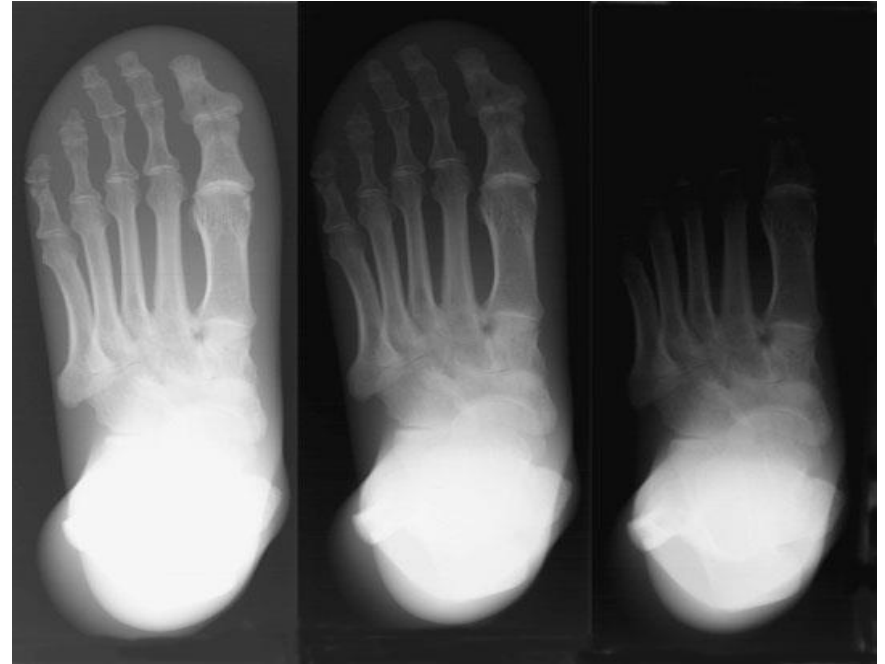The X ray generator will automatically select the highest mA and lowest time that is consistent with an acceptable amount of thermal stress upon the tube.

If insufficient mA is used, then a photographic film will be underexposed and will lack photographic density and therefor will show reduced contrast.

If an electronic image acquisition device is used, then an insufficient **mAs** will manifest itself as noise or mottle, even though the image processing software will have produced a computer screen brightness (**image**) density that appears adequate . **A mAs** level that is too high will result in an overexposed film with excessive density and, again, a lack of contrast. In the case of a digitized electronic image acquisition system, an increasing **mAs** will produce images that are of increasing quality with progressively less noise and improved signal to noise ratio.



Effect of changing mAs on film density for the same kv



Effect of changing kV on film density for the same mAs

Kilovoltage

- This indicates how the X-ray beam will penetrate the body. The range of kilovoltages used in diagnostic radiography is normally between **50 and 120** kVp , although a kilovoltage as low as **25** kVp may be used for certain soft tissue examinations, such as mammography.
- High kVp techniques, such as those used in chest radiography, employ a kilovoltage in excess of **120** kVp
- The kilovoltage will have a profound effect

FFD

For a given kVp and mAs , the greater the FFD, the lower the intensity of radiation reaching the film
Therefore, to obtain the same film blackening, if the FFD is increased the mAs must also be increased. When choosing the FFD, the following factors are taken into consideration:

- .

FFD

1The X ray tube must not be too close to the patient's skin, otherwise radiation damage could be caused.

2Short FFDs could give unacceptable geometric unsharpness

3The FFD must not be excessive, otherwise the large increase in mAs required would mean high tube loading.

Most radiographic examinations are carried out with an FFD of 100 cm

Image quality

Image quality is a term used to describe the appearance of the image and its fitness (suitability) for purpose.

There are two basic descriptors

1- contrast

2- resolution

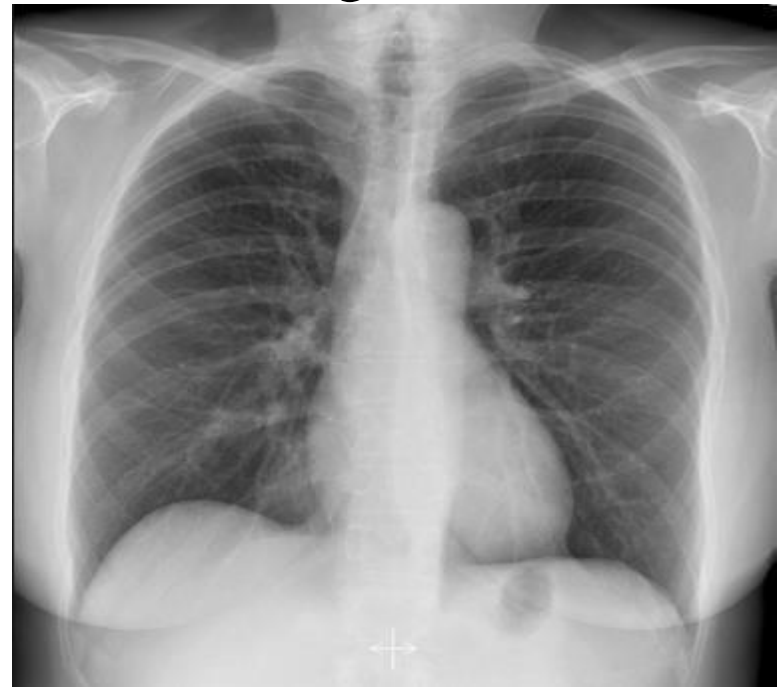contrast

- Is the ability to distinguish between adjacent areas in the image (large regions)

Image is presented as shades of grey from black to white.
i.e., the contrast between the region of the lung and the mediastinum is very marked.

It depends on;

- 1 Properties of tissue.
- 2 The method of image formation

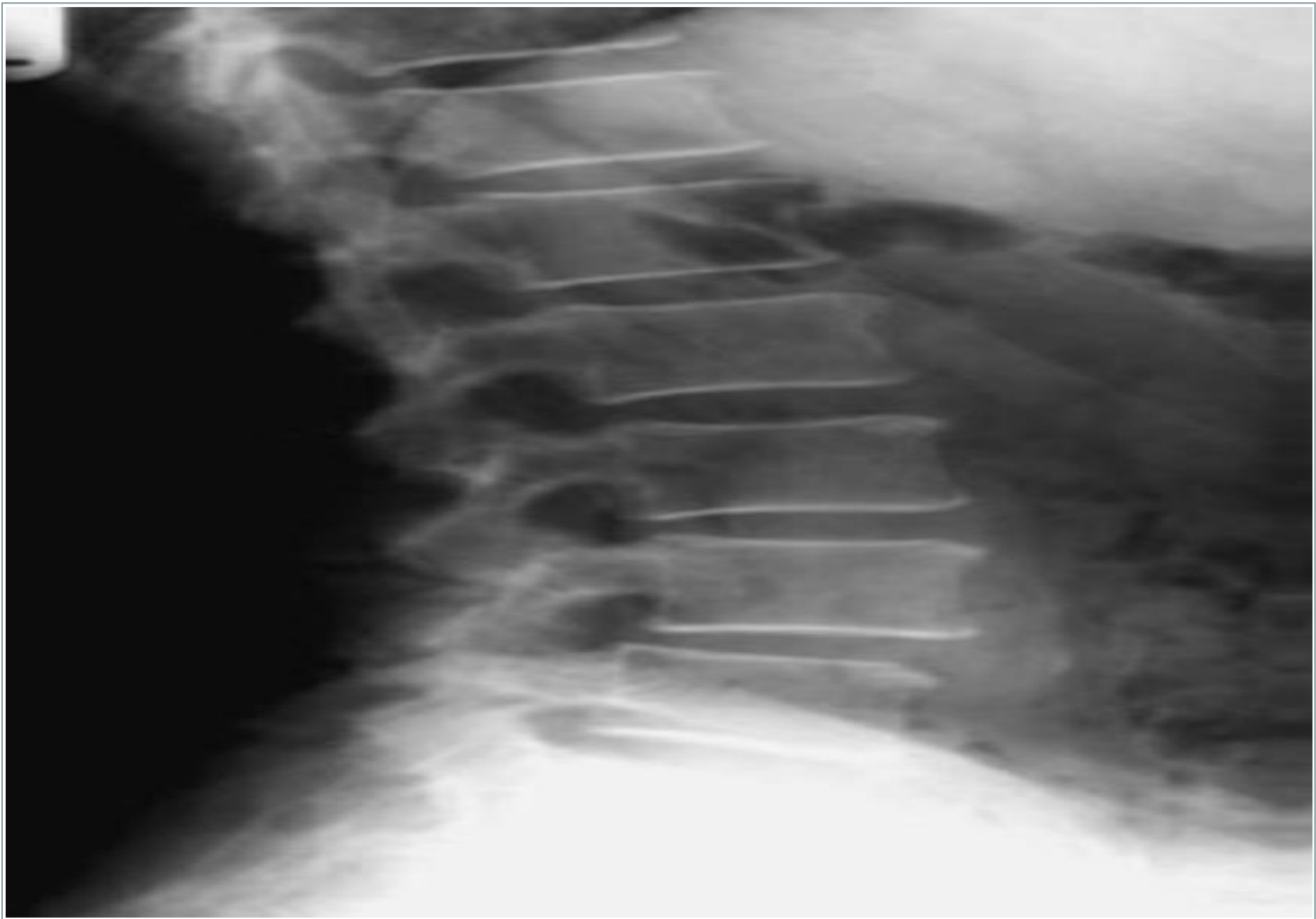

contrast

Is the difference in density between structures of interest within the image. a **low-contrast** image will show little difference in density between structures of interest, whereas a **high-contrast** image will show a larger difference in density between structures.

contrast

- Factors that influence subject contrast include the following:
 - 1- **The region of the body under examination:** there is less subject contrast if all parts of the region have a similar linear attenuation coefficient.
 - Soft tissue structures such as the **breast** have a **low subject contrast**, whereas the subject contrast increases if the region includes **bone** or large differences in the thickness of tissue



contrast

2 Contrast media: if high or low density/ atomic number substances are introduced into cavities in a region, then there will be a greater difference in absorption of X rays by different parts of that region and thus an increase in subject contrast.

3 Pathology: if the density of a structure is changed due to pathology, then there will be a change in subject contrast; for instance, it will be reduced if the bone density reduces, as in osteoporosis.

Spatial resolution

- It is the ability to detect fine detail.
- Fine detail is clearly seen when the contrast between feature and its background is high.

Distortion

Distortion = difference between the shape of a structure in the image and in the object.

Distortion depends on;

a. Object thickness: thick objects are more distorted than thin objects.

b. Object position.

c. Object shape.

Distortion can be reduced by using a longer FFD.

Un sharpness or blurring

is difficult to resolve a small object in the image.

Three types of un sharpness:

- 1) Geometrical
- 2) Movement
- 3) Absorption

1) Geometrical Un sharpness:

That blurring is reducing by:

- a. Using a small focal spot.
- b. Decreasing the object-film distance (OFD) or using a longer focal-film distance (FFD).

2) Movement Un sharpness

Movement of the patient or X-ray tube (X-ray source) during exposure results in blurring the radiographic image.

Patient motion in two types may occur:

- a. Voluntary motion is controlled by immobilization.
- b. Involuntary motion is controlled by short exposure time.

3) Absorption Un sharpness

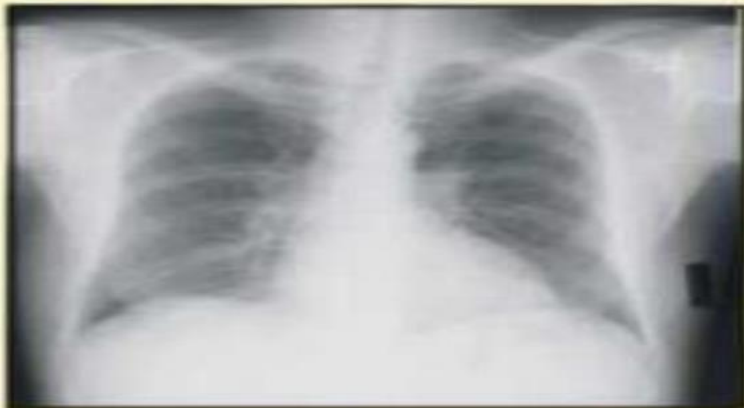A gradual change in absorption near the edge of a tapered or rounded structure (e.g. a blood vessel) produces absorption blurring.

This is inherent in the objects being imaged, although the effect can sometimes be careful patient positioning.

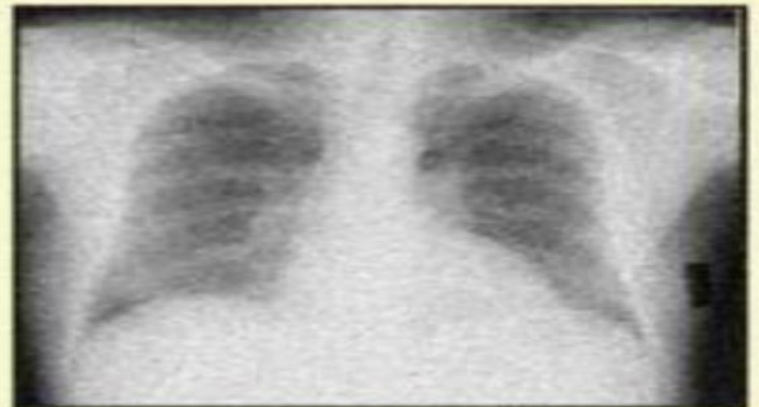
Noise

It is the variation in the levels of grey in the image that are distributed over the area but unrelated to the structures

IMAGE NOISE



LOW



HIGH

Magnification

Some important aspects of a radiological image arise simply from the fact that X-rays travel in straight lines.

The entire (full or complete) image on the radiograph is larger than objects they represent, a condition called magnification.

Magnification $M = \text{image size} / \text{object size}$

Magnification

Magnification is reduced by using a longer FFD (increasing the object distance or size).

Also, **to decrease magnification;**

a. When positioning the patient, the film is placed close to the structures of interest (decreasing the image distance or size).

b. Tissues compression, this will also reduce patient dose

Thank
you!





Radiology Techniques Department

Radiographic imaging

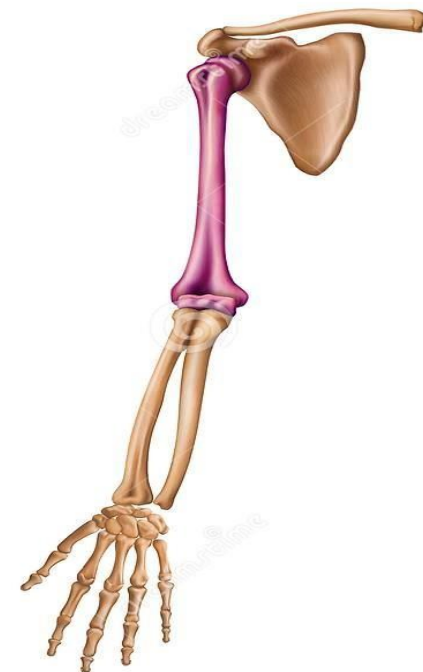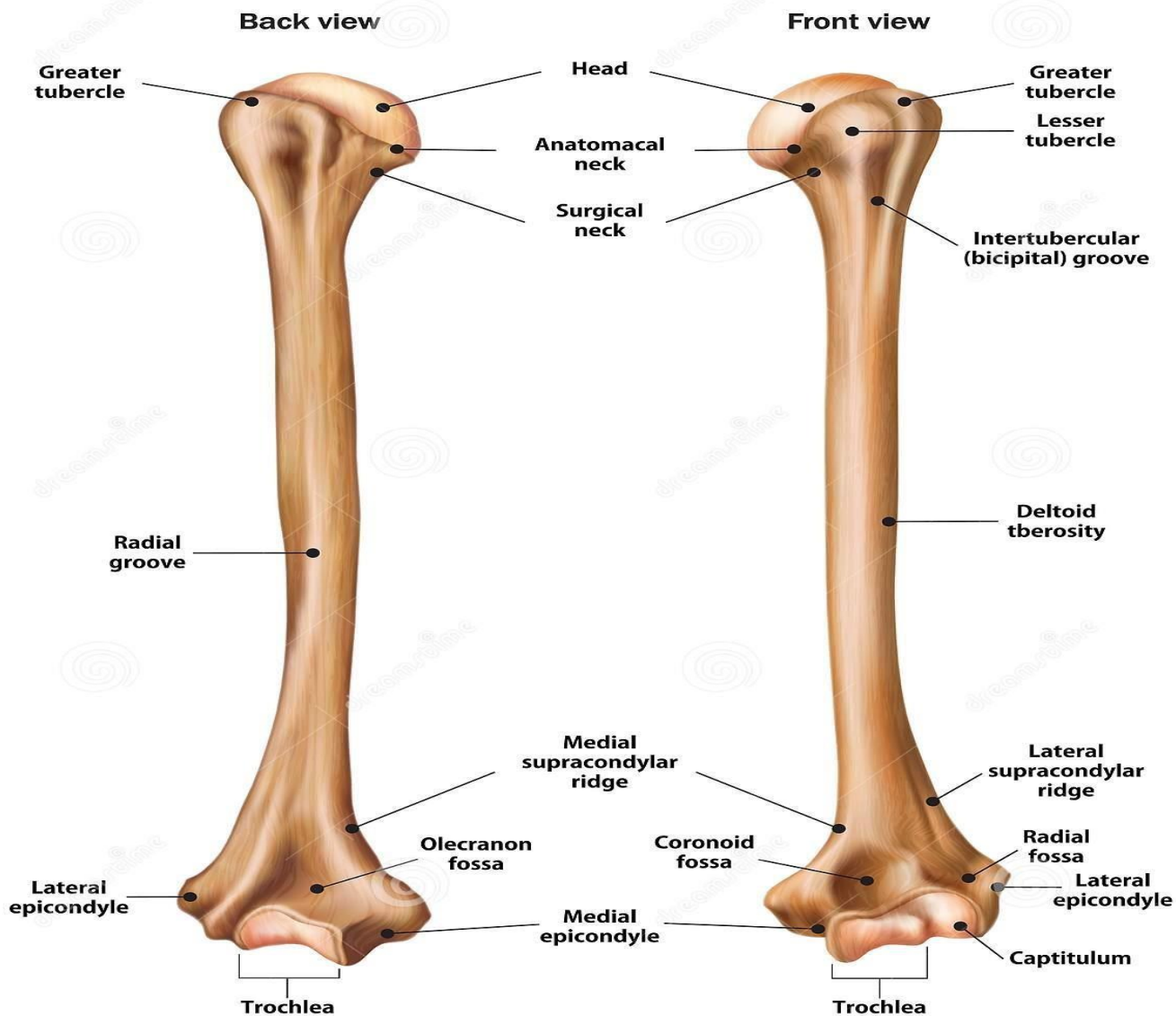
Radiographic position of humerus

Lecture 5

د. حيدر سعيد شندل

M.B.CH.B MSc. RAD. (ASU)

Humerus bone



Humerus

Anatomy of the humerus

- A . Head of humerus
- B. Greater tubercle
- C. Intertubercular- groove
- D. Lesser tubercle
- L. Anatomic neck
- G. Body
- F. Surgical neck

Basic Projection of Humerus

- 1 Antero-posterior
- 2 Lateral

Antero-posterior – supine

- Position of patient and cassette
- The patient lies supine on the X-ray table, with the unaffected side raised and supported on pads.
- The cassette 35 x 43-cm(14x17) cassette is positioned out bucky under the affected limb and adjusted to include the shoulder and elbow joints.
- The arm is slightly abducted and the elbow joint is fully extended, so that the posterior aspect of the upper arm is in contact with the cassette.
- The arm is adjusted to ensure that the medial and lateral epicondyles are equidistant from the cassette.
- The forearm is immobilized using a sandbag

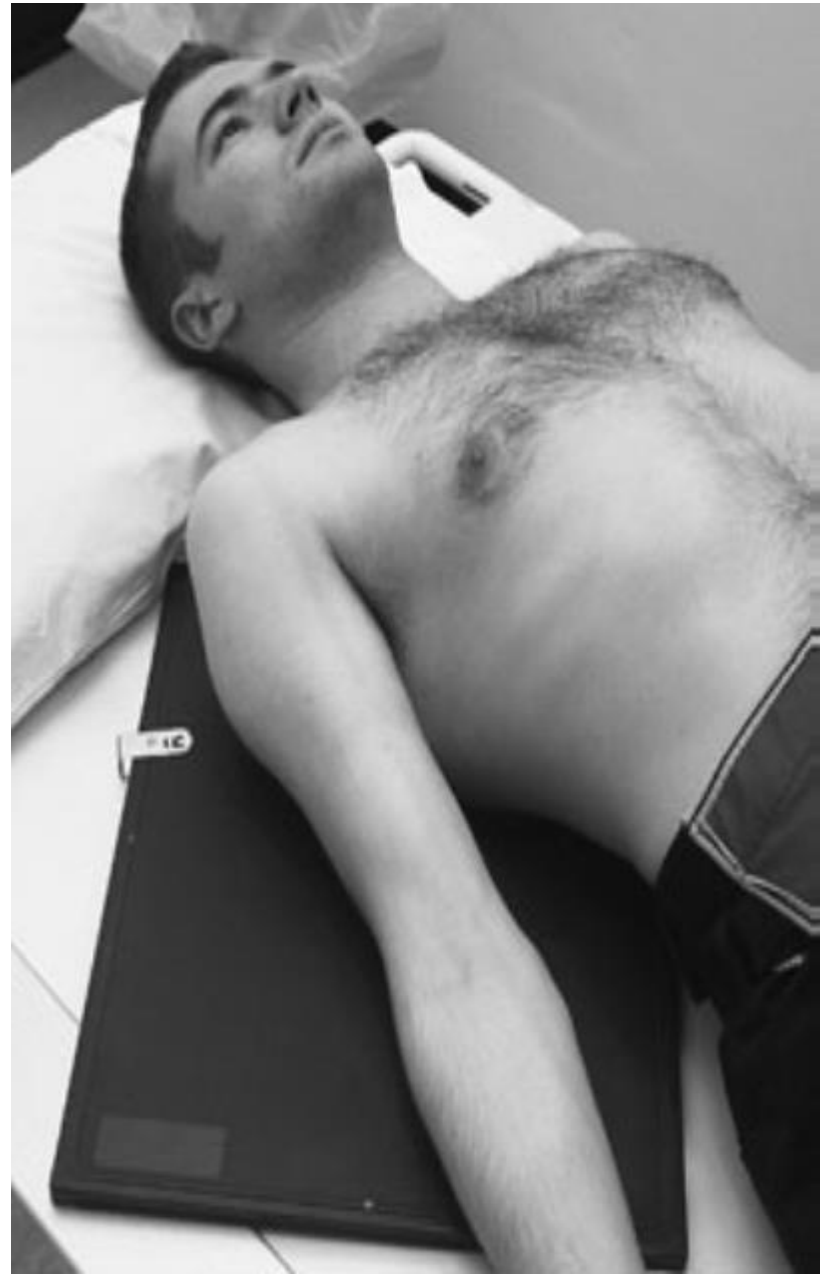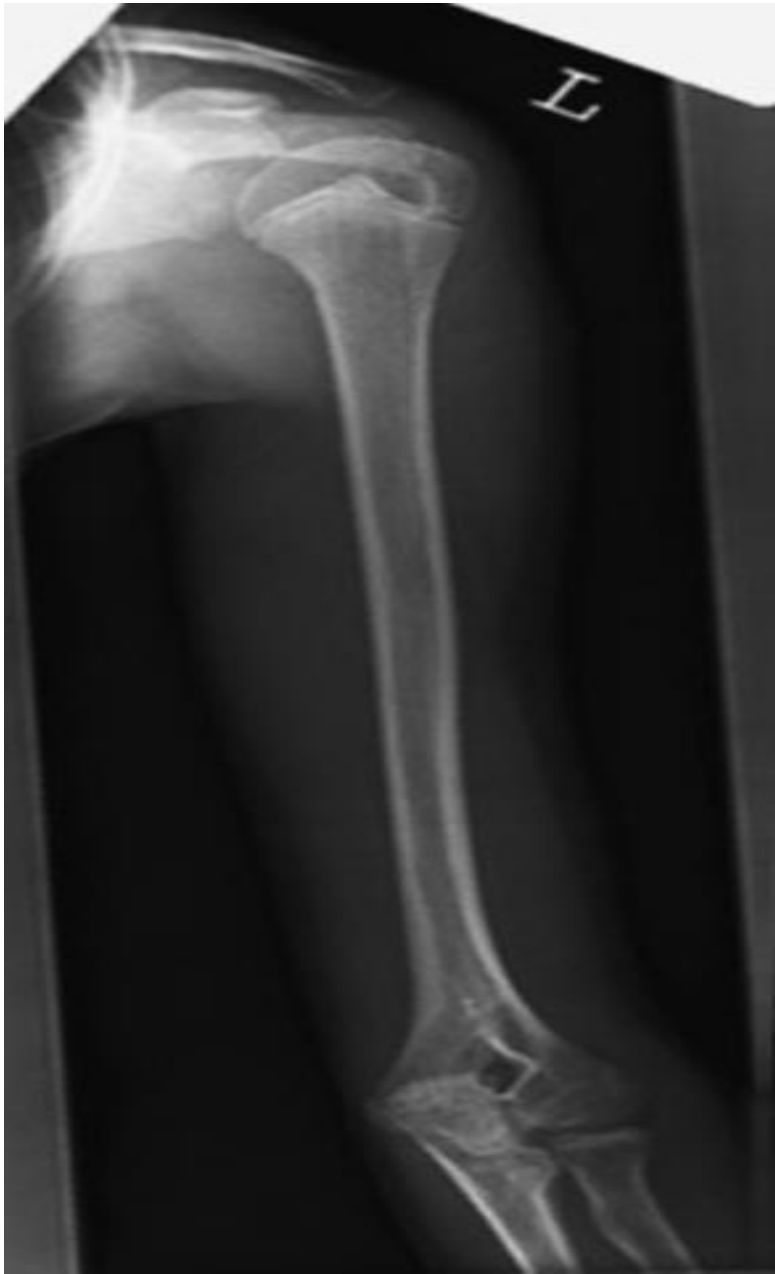Antero-posterior – supine

Direction and centering of the X-ray beam

- The vertical central ray is centered to a point midway between the **shoulder and elbow joints**

Essential image characteristics

- Both joints should be seen on the image



Lateral - supine

Position of patient and cassette

- From the antero-posterior position, the elbow joint is flexed to 90 degrees.
- The arm is abducted and then medially rotated through 90 degrees to bring the medial aspect of the arm, elbow and forearm in contact with the table.
- The cassette is placed under the arm and adjusted to include both the shoulder and the elbow joints.
- The humerus is adjusted to ensure that the medial and lateral epicondyles of the humerus are superimposed.
- The forearm is immobilized using a sandbag

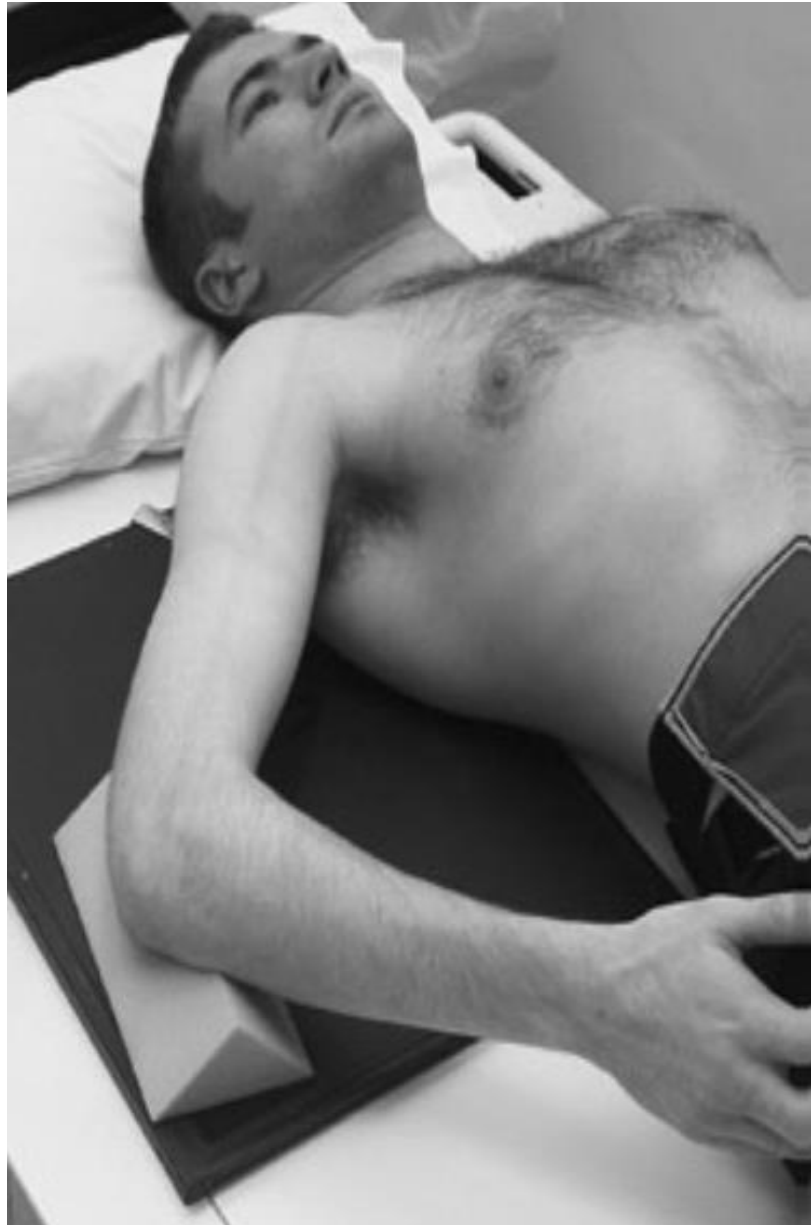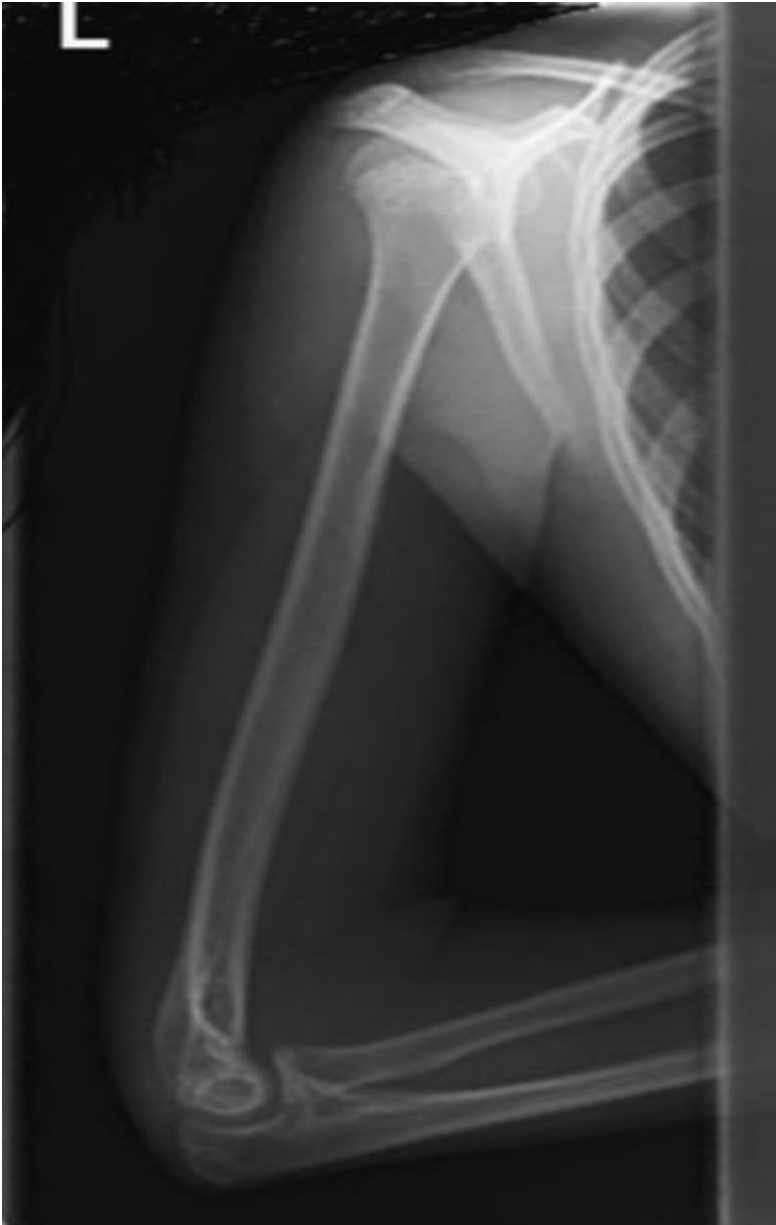Lateral - supine

Direction and centering of the X-ray beam

- The vertical central ray is centered to a point midway between the **shoulder and elbow joints**.

Essential image characteristics

- Both joints should be seen on the image.
- The elbow joint should be seen in the true lateral



Antero-posterior – erect

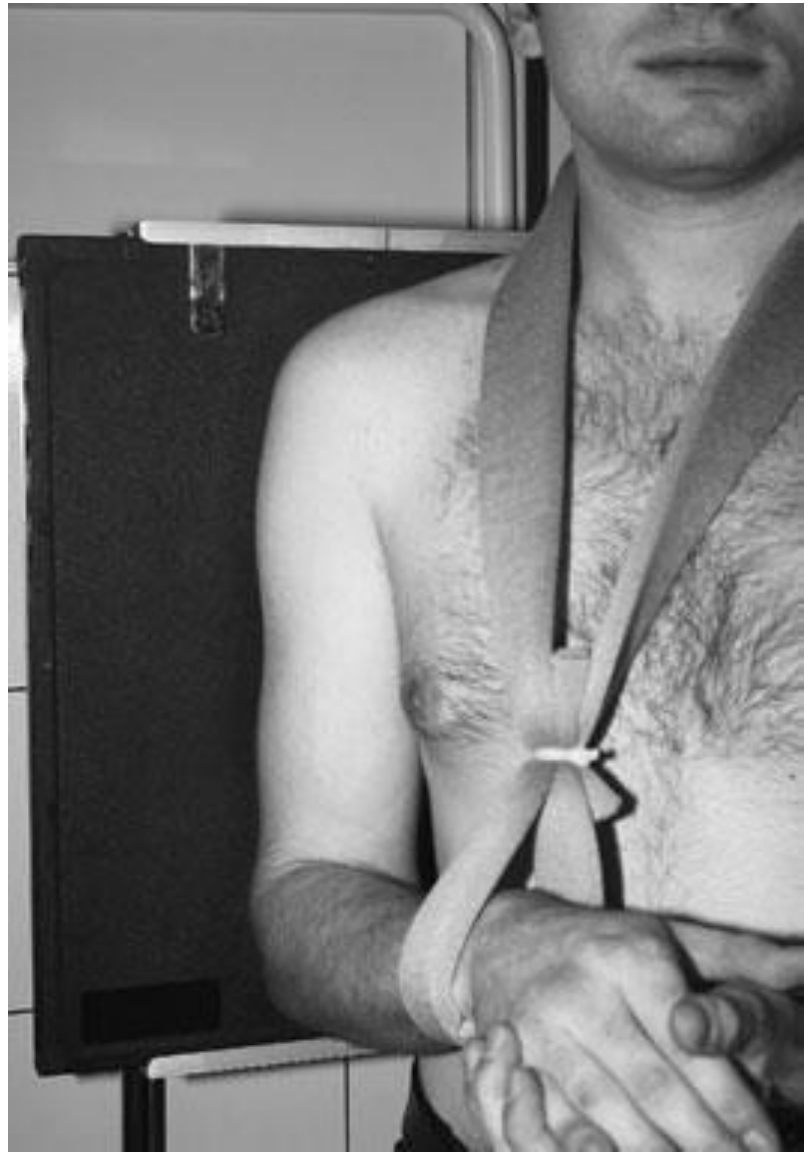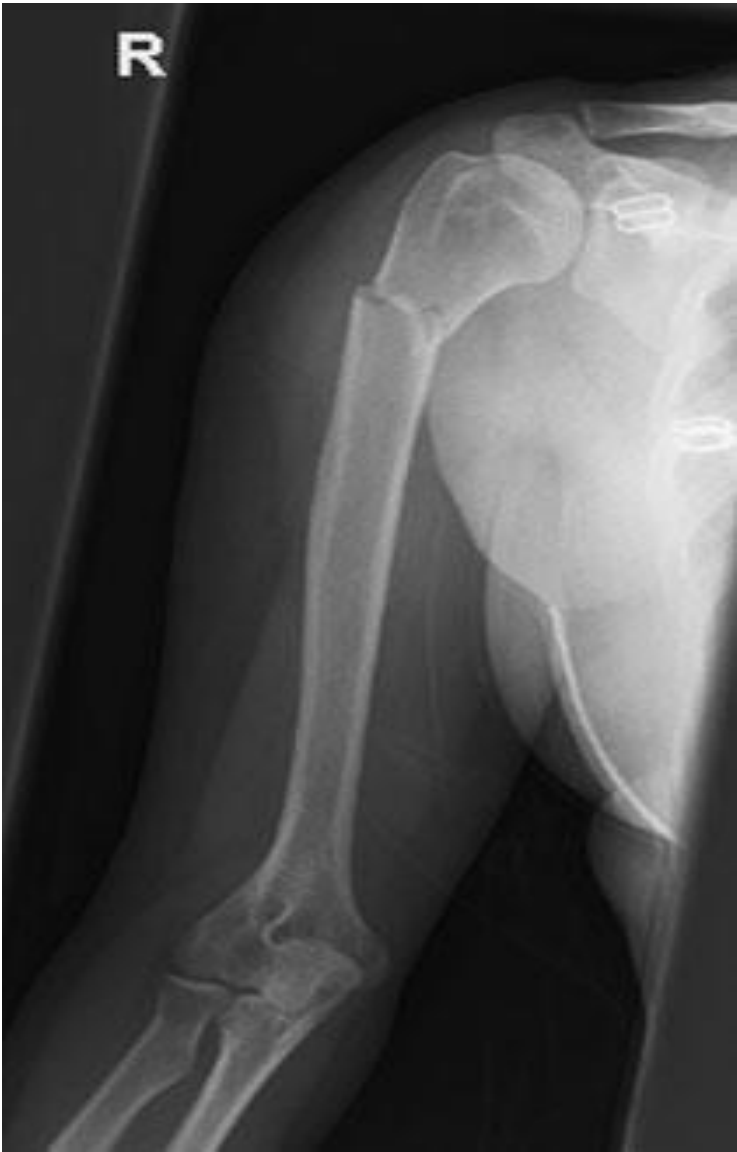Position of patient and cassette

- The cassette is placed in an erect cassette holder.
- The patient sits or stands with their back in contact with the cassette.
- The patient is rotated towards the affected side to bring the posterior aspect of the shoulder, upper arm and elbow in contact with the cassette
- The position of the patient is adjusted to ensure that the medial and lateral epicondyles of the humerus are equidistant from the cassette.

Antero-posterior – erect

Direction and centering of the X-ray beam

- The central ray is directed at right-angles to the shaft of the humerus and centered midway between the shoulder and elbow joints.



Lateral- erect

Position of patient and cassette

- The cassette is placed in an erect cassette holder.
- From the anterior position, the patient is rotated through 90 degrees until the lateral aspect of the injured arm is in contact with the cassette
- The patient is now rotated further until the arm is just clear of the rib cage but still in contact with the cassette.

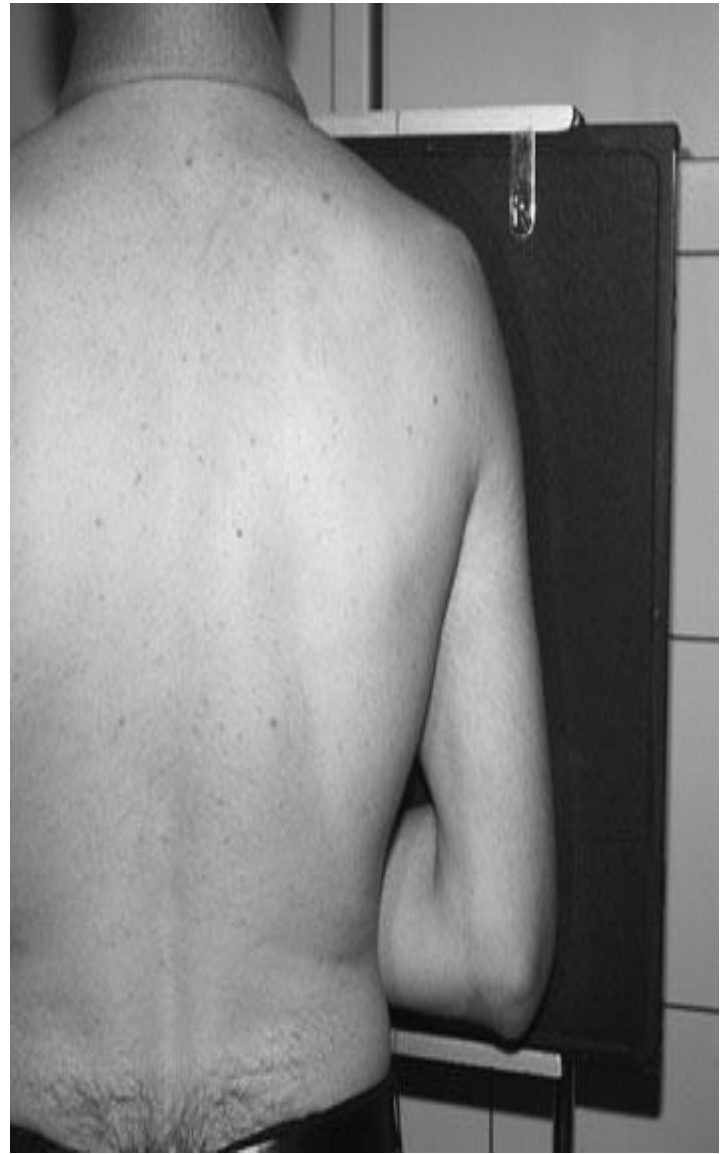
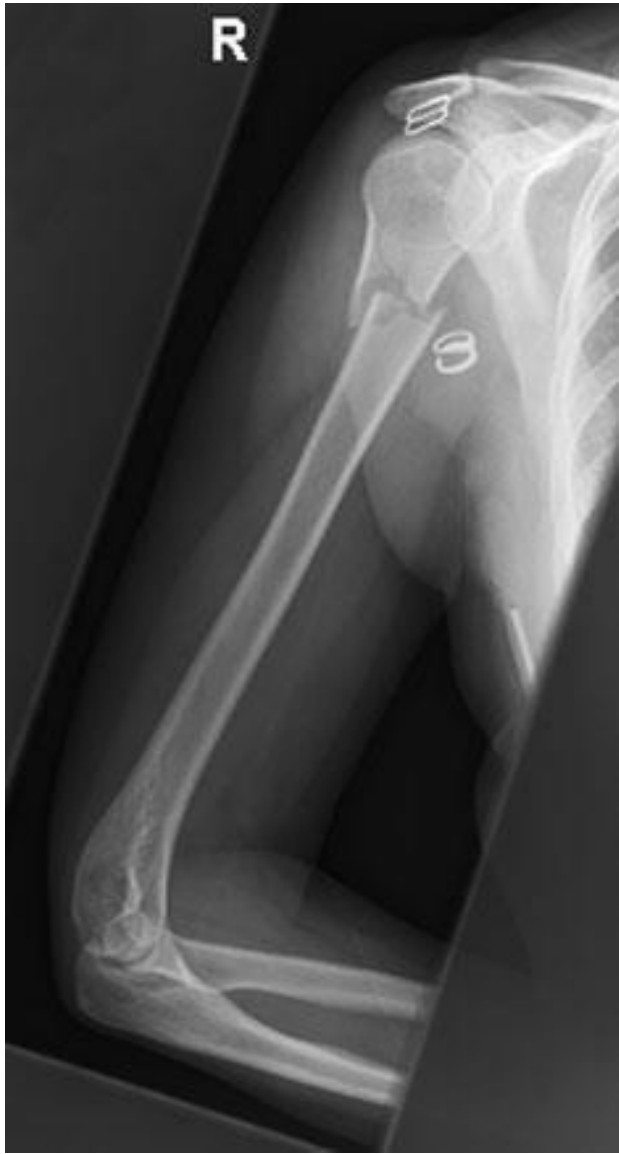Lateral- erect

Direction and centring of the X-ray beam

- The horizontal central ray is directed at right-angles to the shaft of the humerus and centred midway between the **shoulder and elbow joint**.

Essential image characteristics

- The exposure should be adjusted to ensure that the area of interest is clearly visualized.



Humerus – neck

- Humerus – neck
- The most common reason for radiography of the neck of the humerus is suspected fracture, either pathological or traumatic.
- Two projections at right-angles are necessary: an (anterio posterior and an axial or a lateral projection).

Antero-posterior

Position of patient and cassette

- The patient stands or lies supine facing the X-ray tube.
- The patient is rotated towards the affected side to bring the posterior aspect of the injured shoulder into contact with the midline of the cassette.
- The cassette A 24 x 30-cm (10x12) is positioned out bucky to include the acromion process and the proximal half of the humerus

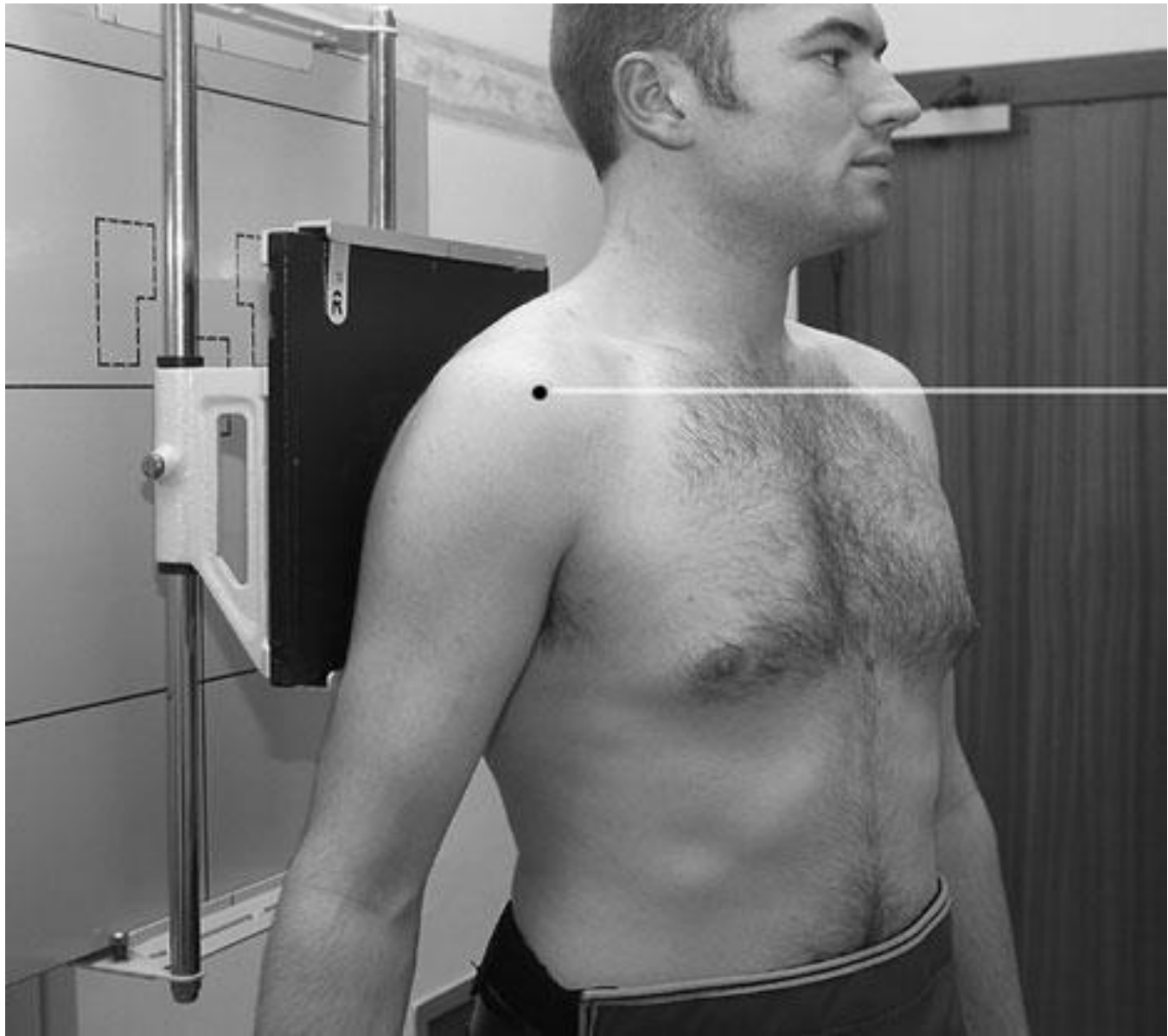Antero-posterior

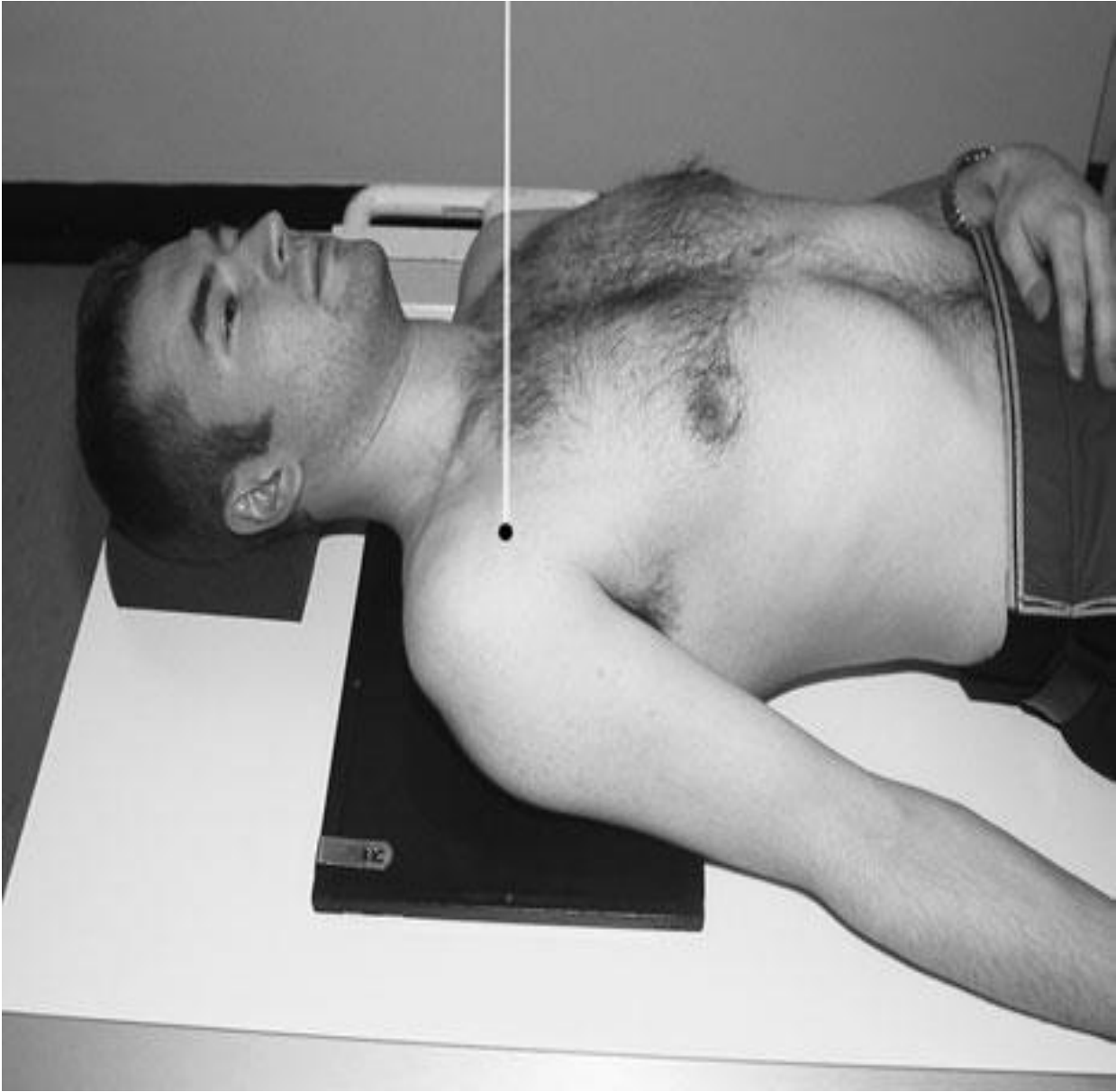Direction and centering of the X-ray beam

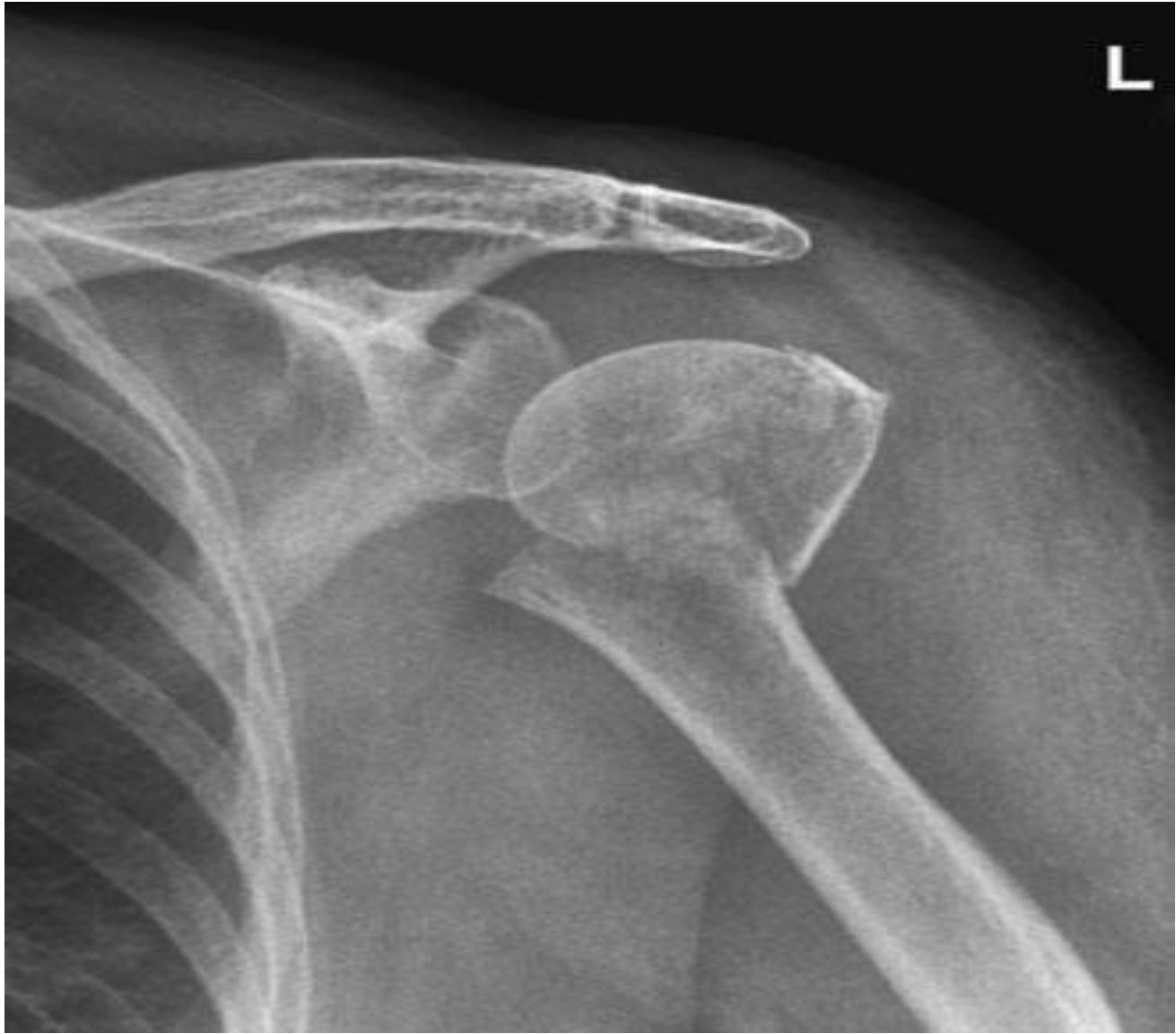- The central ray is directed at right-angles to the humerus and centered to the head of the humerus.

Essential image characteristics

- The image should include the acromion process and proximal half of the shaft of the humerus.
- The exposure should demonstrate adequately the neck of the humerus clear of the thorax







Thank
you!





Radiology Techniques Department

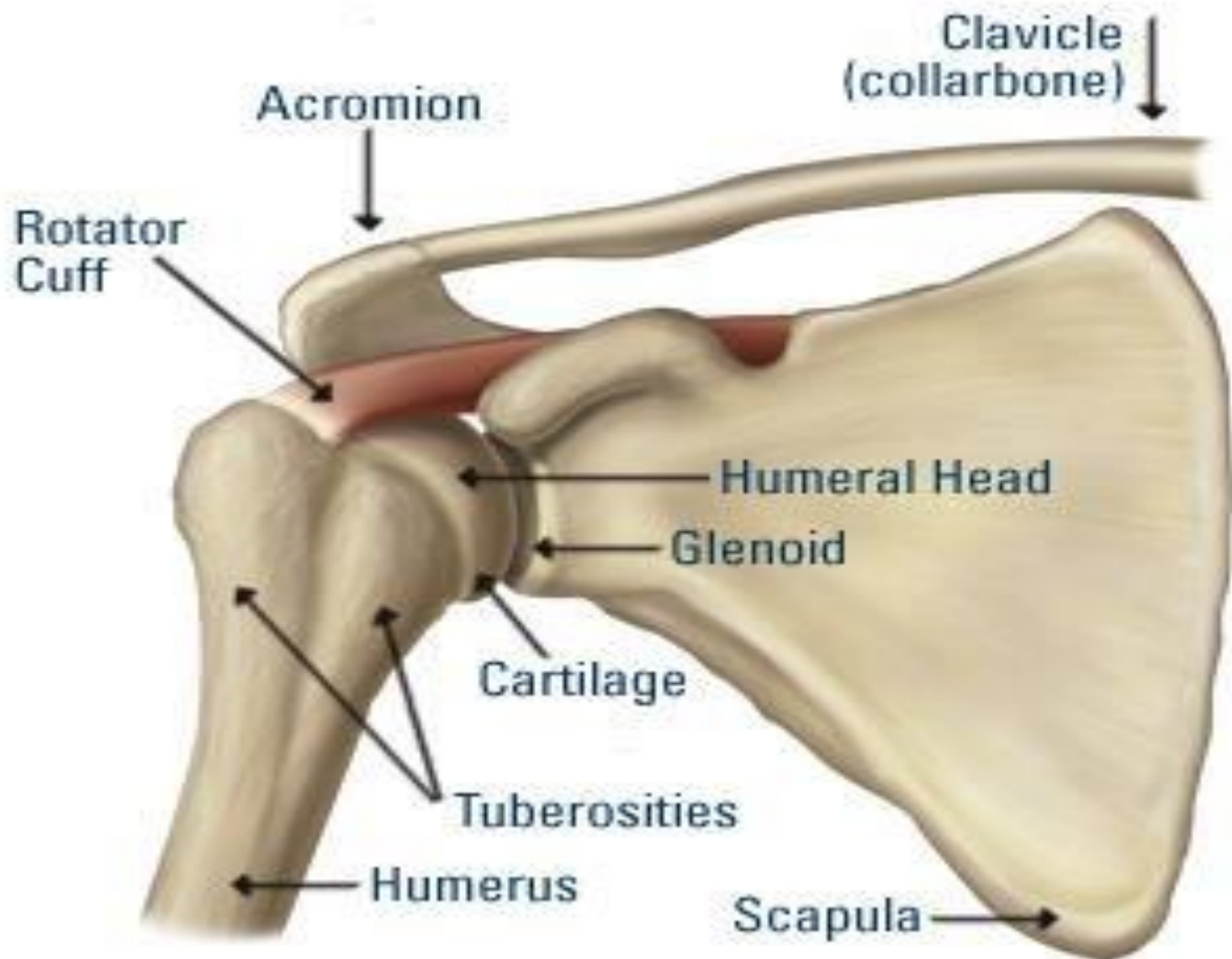Radiographic imaging

Radiographic position of shoulder

Lecture 6

د. حيدر سعيد شندل

M.B.CH.B MSc. RAD. (ASU)



Shoulder

Basic position in shoulder

- Antero posterior
- Axial
- superio- inferior
- inferio- superior

Anterio-posterior(15 degree) erect position

Position of patient and cassette

- The patient stands with the affected shoulder against the cassette and is rotated **15 degrees** to bring the shoulder closer to the cassette and the plane of the acromioclavicular joint parallel to the central beam.
- The arm is supinated and slightly abducted away from the body. The medial and lateral epicondyles of the distal humerus should be parallel to the cassette.

Anterio-posterior(15 degree) erect position

- The cassette is positioned so that its upper border is at least 5 cm above the shoulder to ensure that the oblique rays do not project the shoulder off the cassette

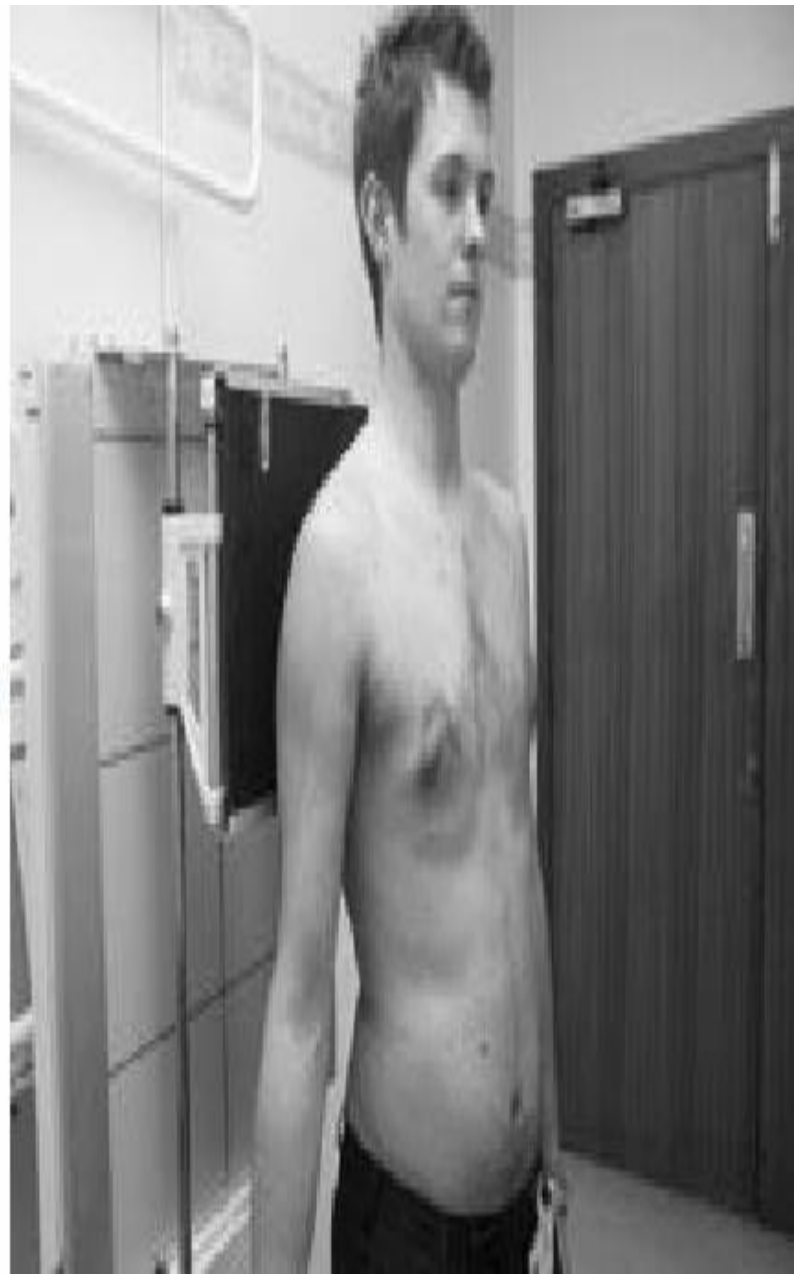
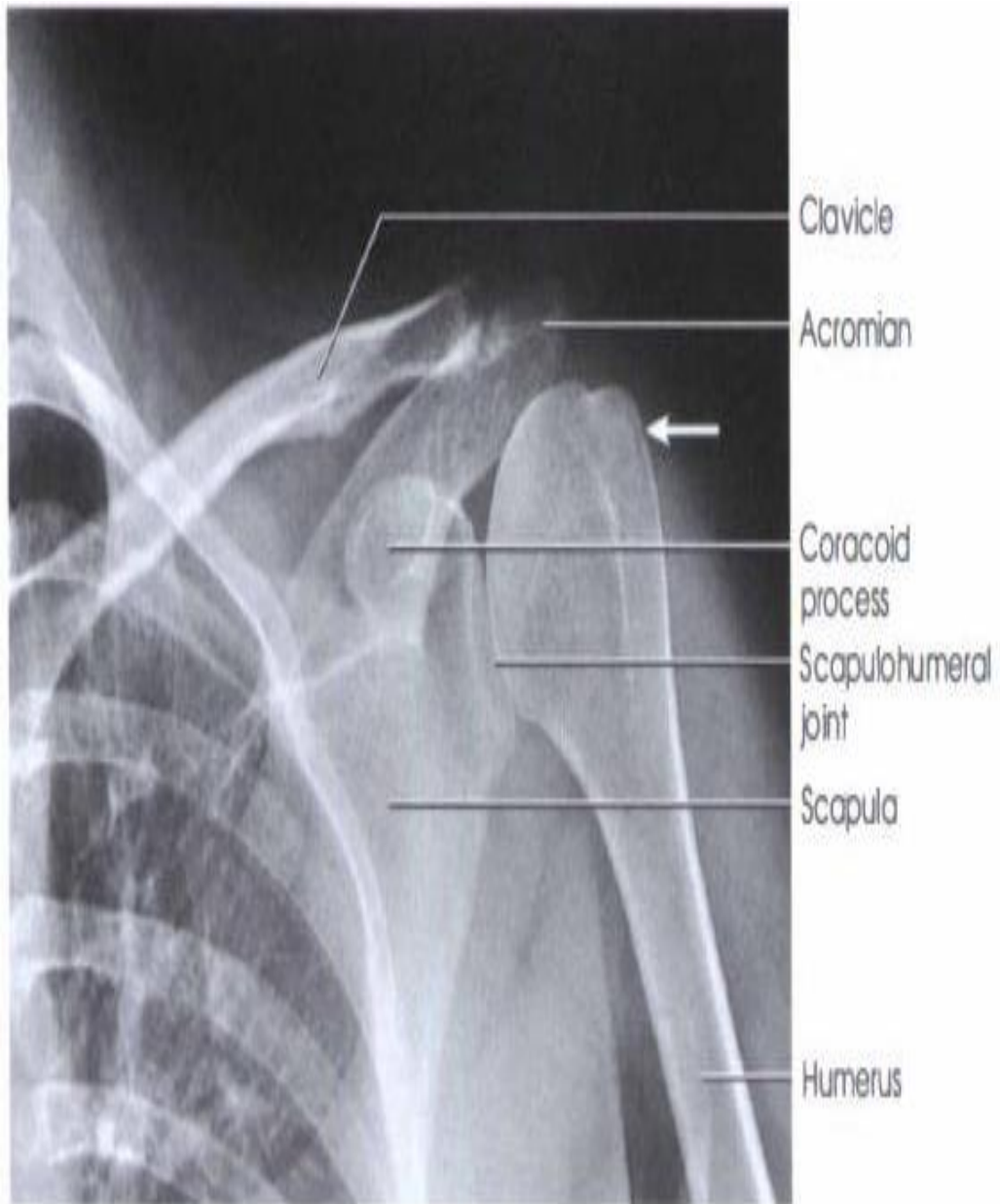Anterio-posterior(15 degree) erect position

Direction and centering of the X-ray beam

- The horizontal central ray is directed to coracoid process of the scapula.

Essential image characteristics

- The image should demonstrate the head and proximal end of the humerus, the inferior angle of the scapula and the whole of the clavicle.
- The head of the humerus should be seen slightly overlapping the glenoid cavity but separate from the acromion process.
- Arrested respiration aids good rib detail in acute trauma.



Axial (superio-inferior)

Position of patient and cassette

- The patient is seated at the side of the table, which is lowered to waist level.
- The cassette is out bucky (8x10) placed on the tabletop, and the arm under examination is abducted over the cassette
- The elbow can remain flexed, but the arm should be abducted to a minimum of 45 degrees

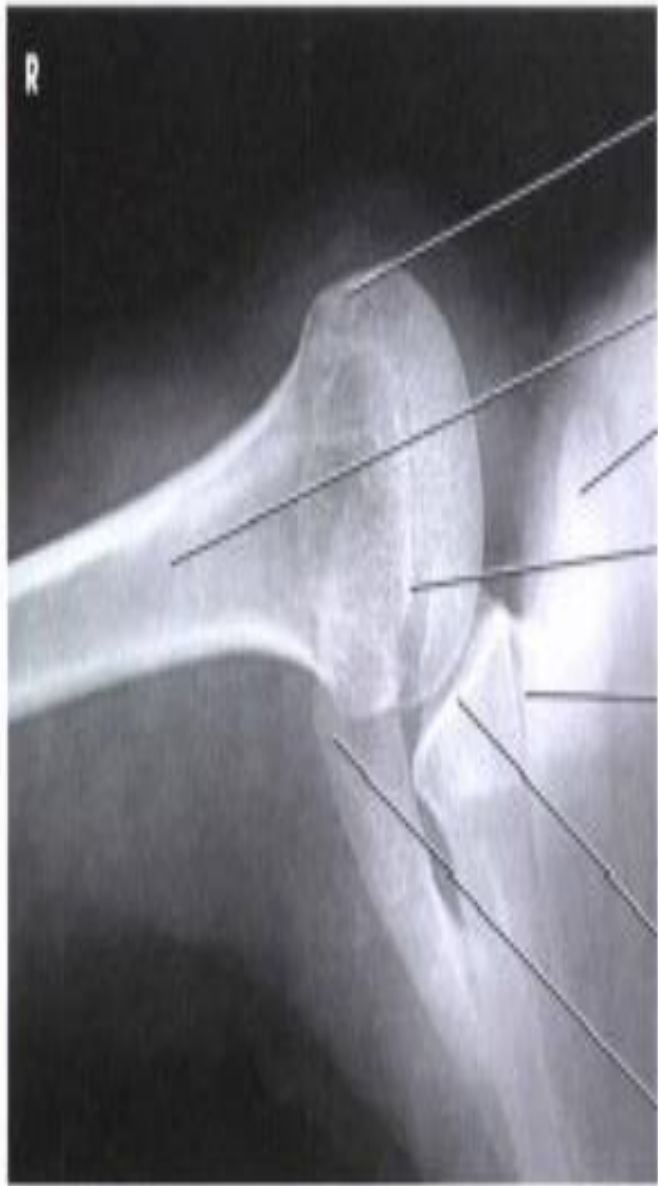Axial (superio-inferior)

Direction and centering of the X-ray beam

- The vertical central ray is directed through the proximal aspect head of the humerus

Essential image characteristics

- Lateral view of proximal humerus in relationship to the glenohumeral articulation is visualised.
- Corocoid process of scapula is seen



Lesser tubercle

Humerus

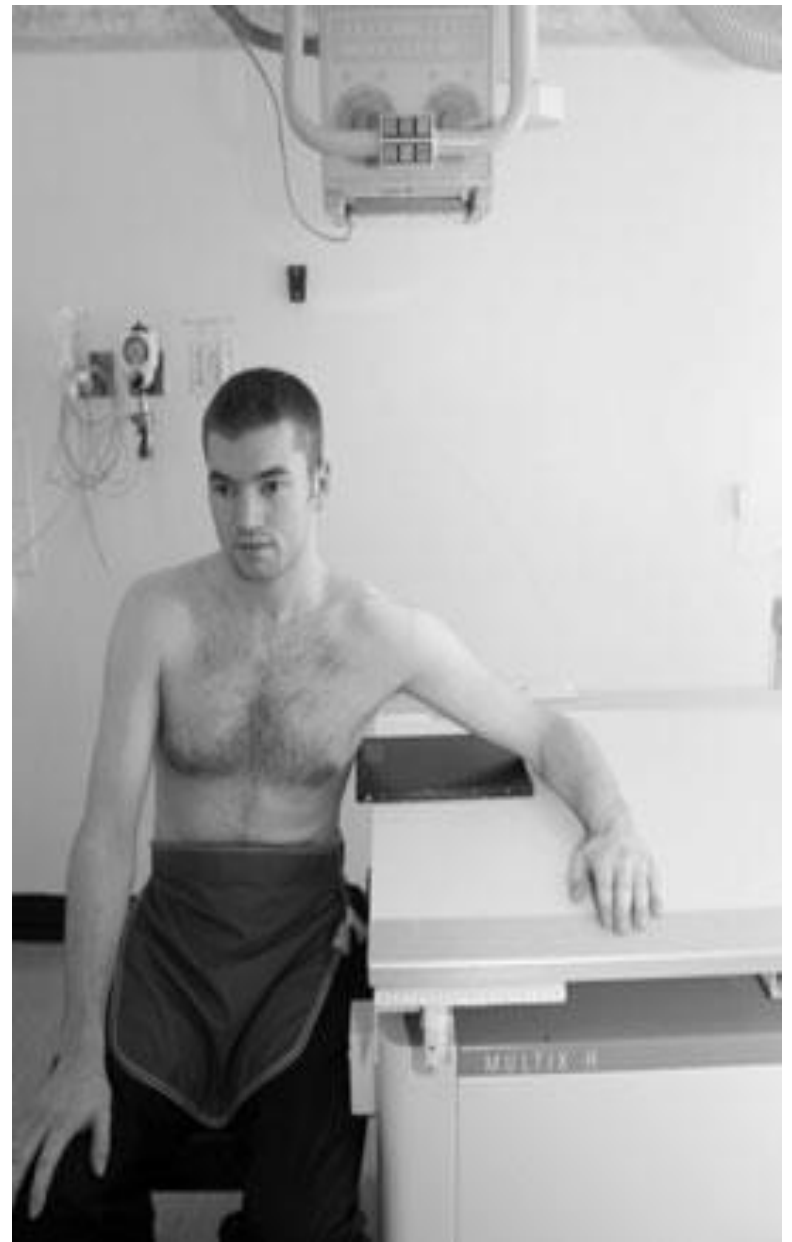Coracoid process

Acromioclavicular joint

Clavicle

Scapulohumeral joint

Acromion



Axial (infero superior)

- Also known as **Lawrence view**
- This projection may be used as an alternative to the superoinferior projection in cases of dislocation or when the patient is supine, since it can be taken even when the patient is able to abduct the arm only slightly.
- An (12x10) cassette is used.

Axial (superio-inferior)

Position of patient and cassette

- The patient lies supine, with the arm of the affected side slightly abducted and supinated without causing discomfort to the patient.
- The affected shoulder and arm are raised on non-opaque pads.
- A cassette is supported vertically against the shoulder and is pressed against the neck to include as much as possible of the scapula on the film.

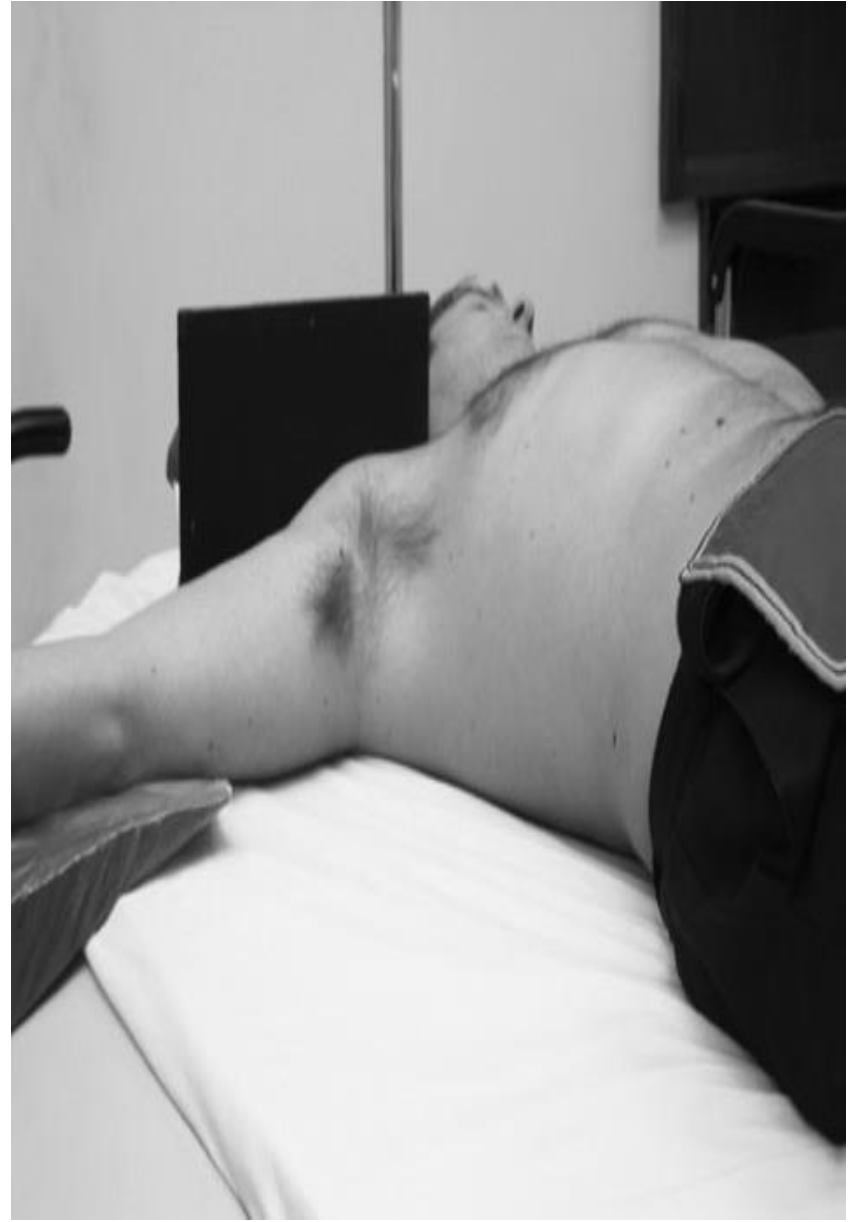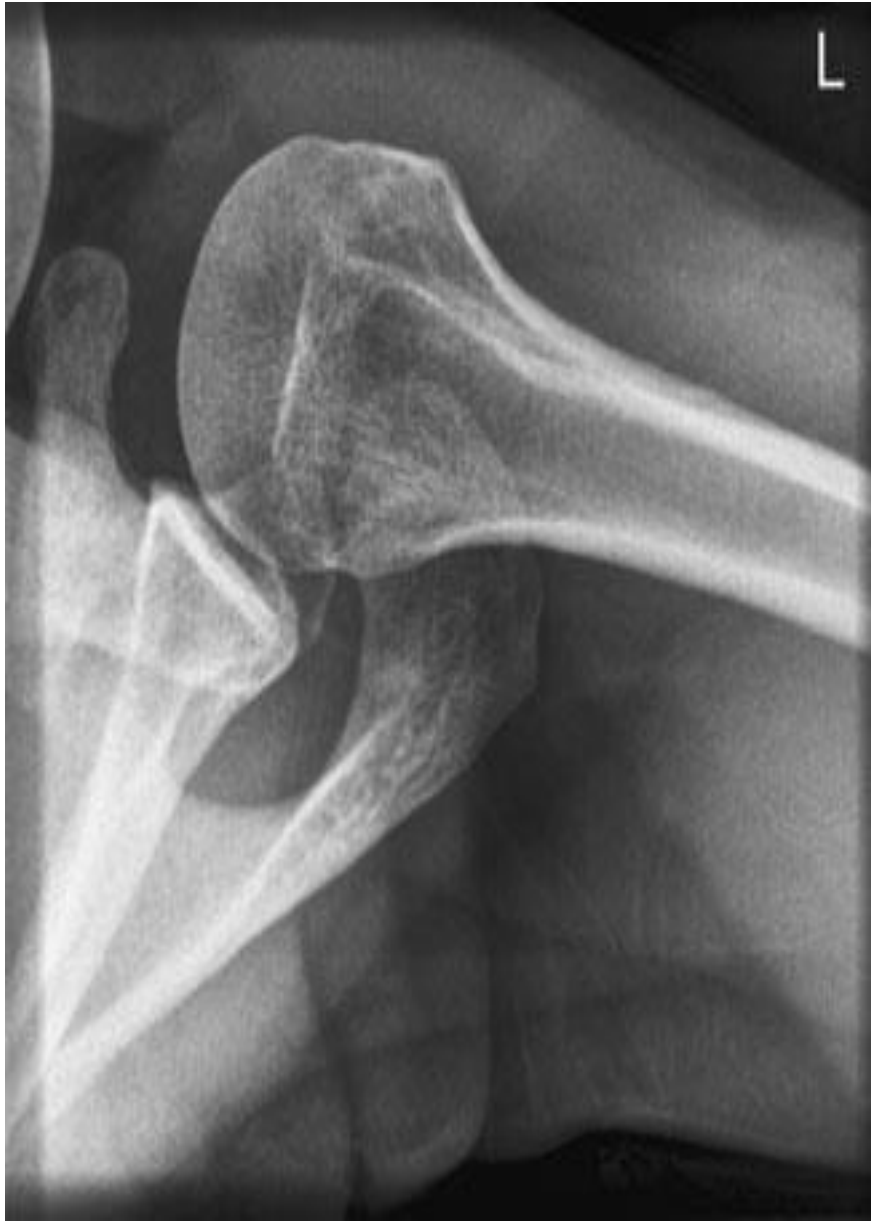Axial (superio-inferior)

Direction and centering of the X-ray beam

- The horizontal central ray is directed towards the axilla.

Essential image characteristics

- The image should demonstrate the head of the humerus, the acromion process, the coracoid process and the glenoid cavity of the scapula.
- The lesser tuberosity will be in profile, and the acromion process and the superior aspect of the glenoid will be seen superimposed on the head of humerus



Lateral (outlet view)

Position of patient and cassette

- The patient stands or sits facing the cassette, with the lateral aspect of the affected arm in contact.
- The affected arm is extended backwards, with the dorsum of the hand resting on the patient's waist.
- The patient is adjusted so that the head of the humerus (coracoid process) is in the centre of the cassette.
- The patient is now rotated forward until a line joining the medial and lateral borders of the affected scapula is at right-angles to the cassette.

Lateral (outlet view)

The body of the scapula is now at right-angles to the cassette, and the scapula and the proximal end of the humerus are clear of the rib cage

Lateral (outlet view)

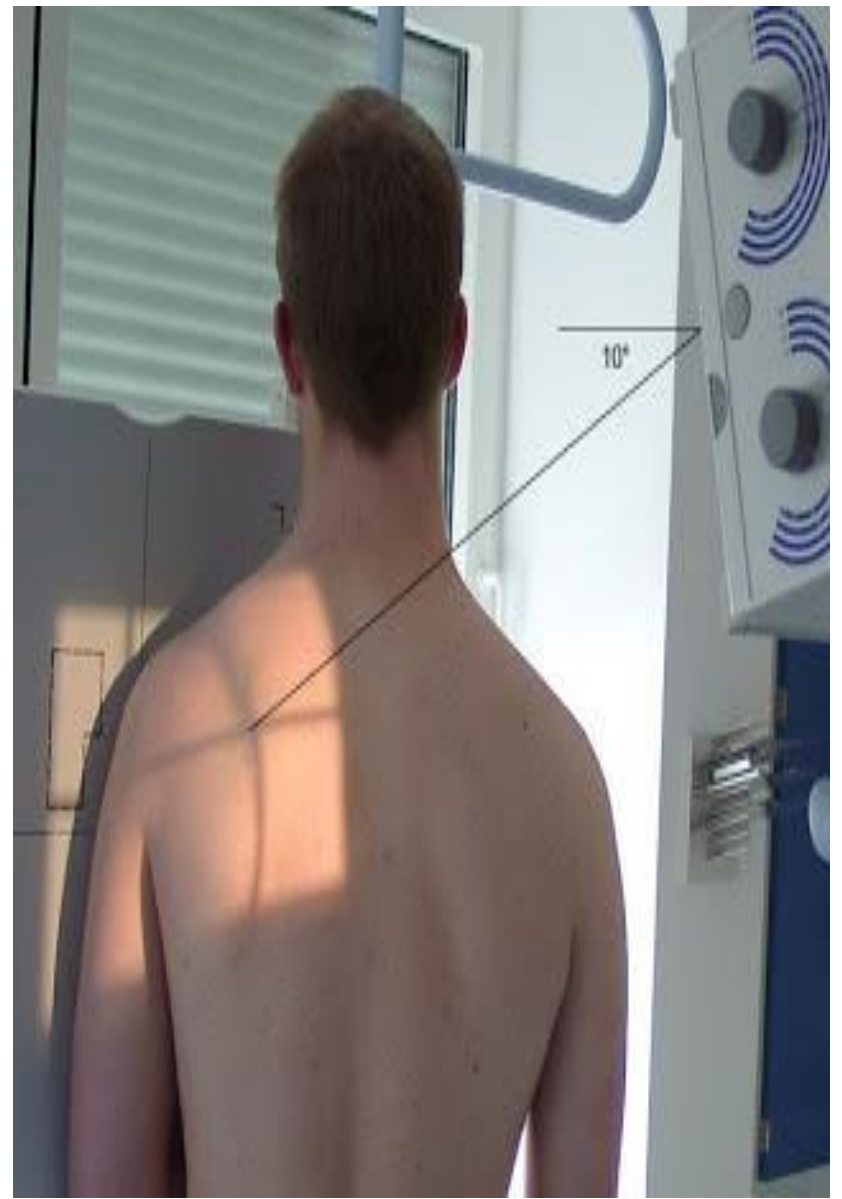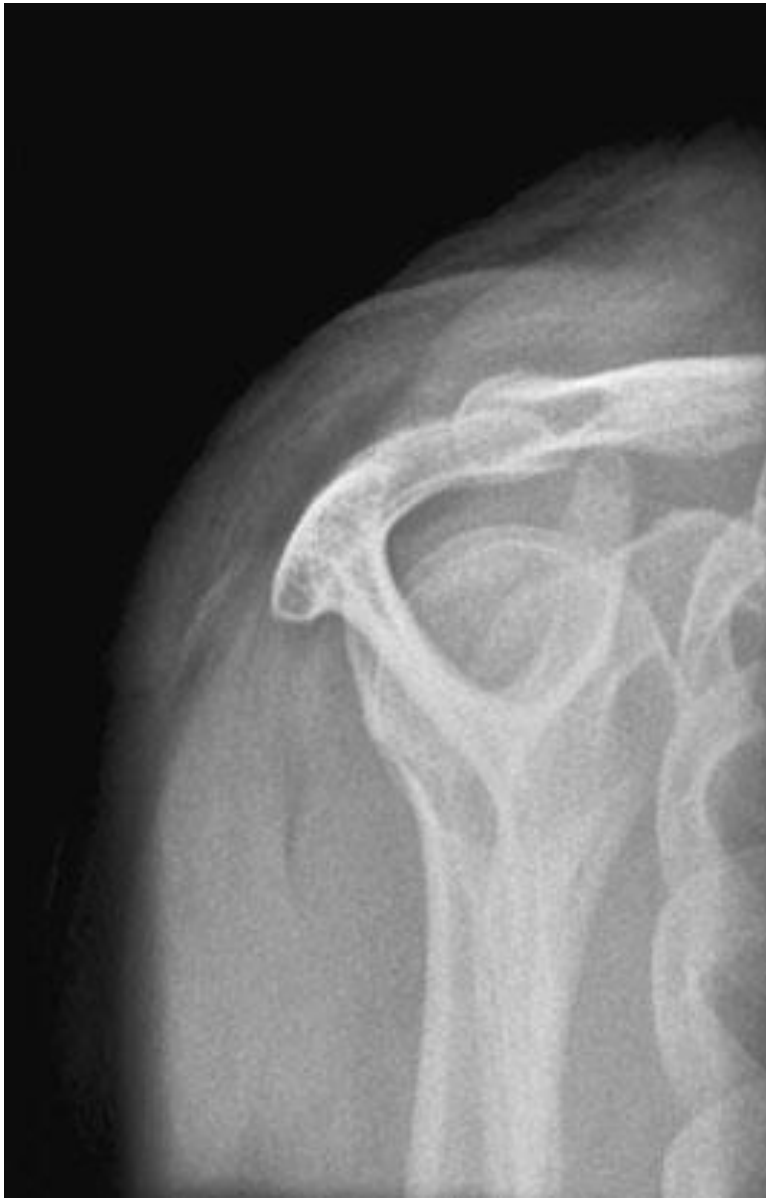Direction and centring of the X-ray beam

- The horizontal central ray is angled 10 degrees caudally and centred to the head of the humerus.

Essential image characteristics

The humeral head should appear superimposed and centered to the glenoid fossa.

The extent of the anterior projection of the acromion and the subacromial space.



Lateral oblique 'Y' projection

Position of patient and cassette

- The patient stands or sits with the lateral aspect of the injured arm against the cassette.
- The patient rotates 45-60 degrees.
- The arm is abducted with the elbow flexed to allow the back of the hand to rest on the hip.
- The cassette is positioned to include the superior border of scapula

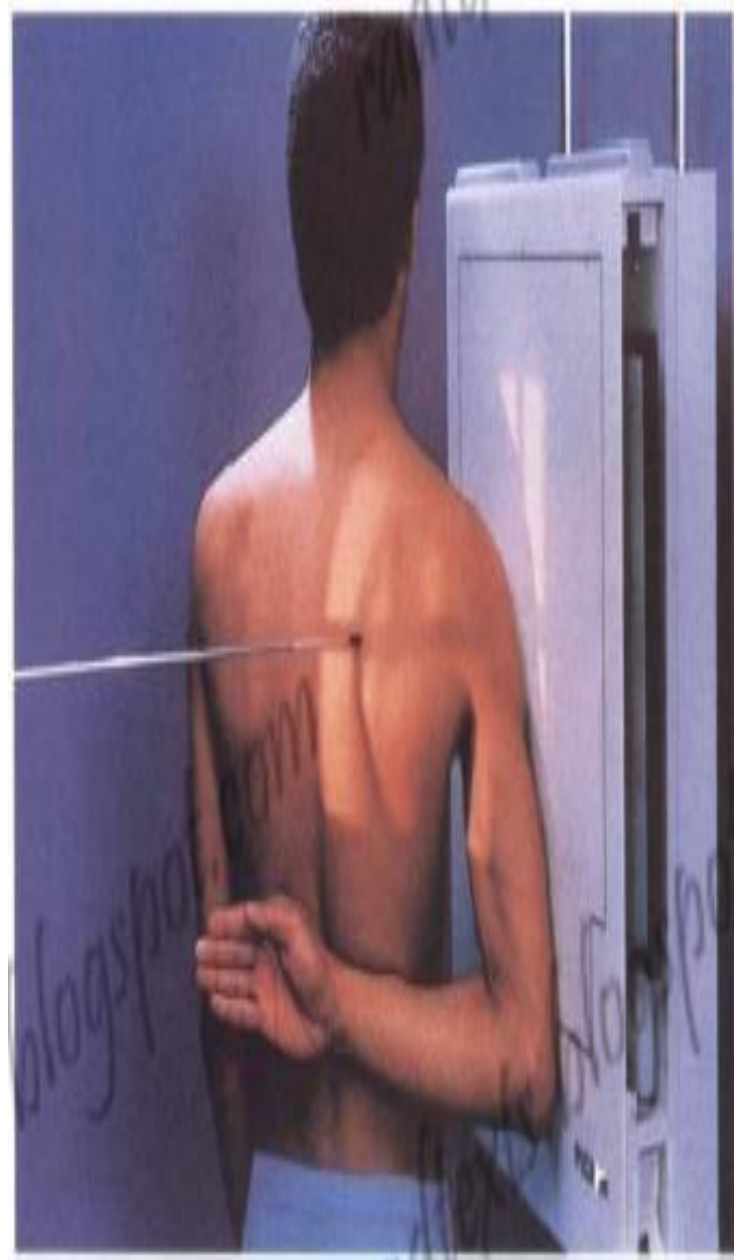
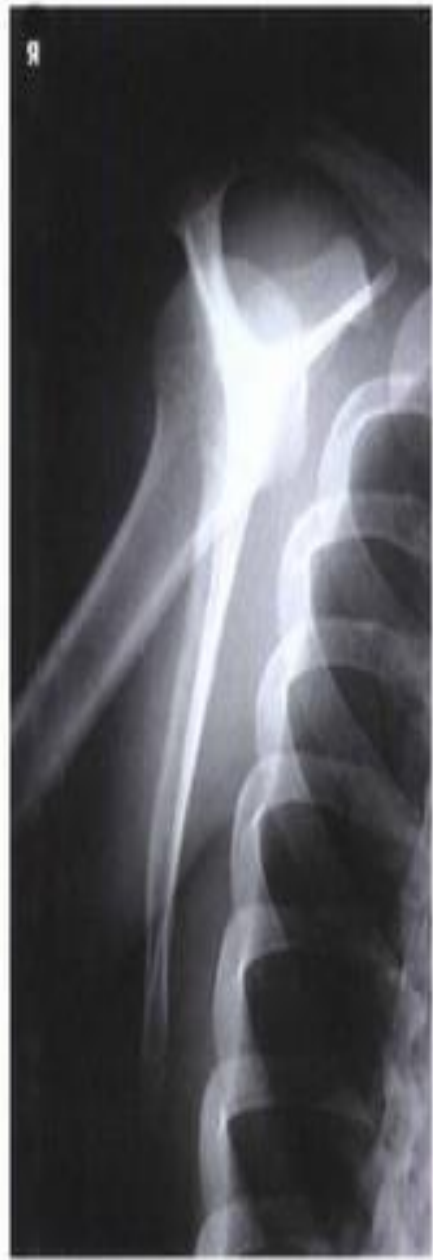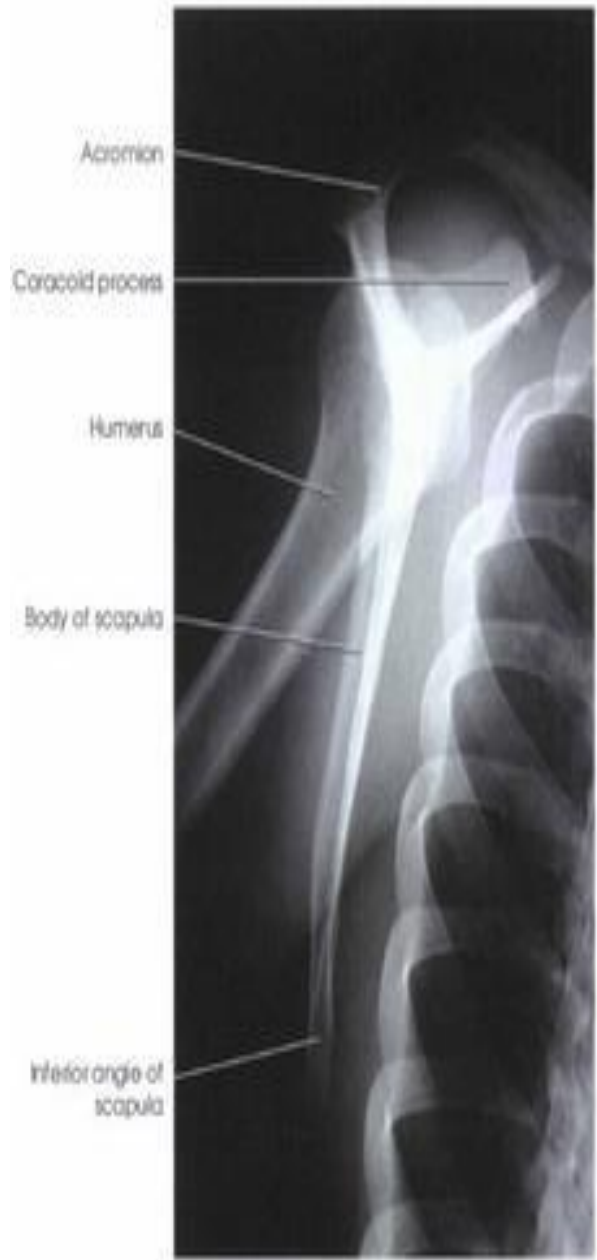Lateral oblique 'Y' projection

Direction and centring of the X-ray beam

- The horizontal central ray is directed towards the medial border of the scapula

Essential image characteristics

- The body of the scapula should be at right-angles to the cassette, and the scapula and the proximal end of the humerus are clear of the rib cage.
- The exposure should demonstrate the position of the head of the humerus in relation to the glenoid cavity between the coracoid and acromion processes



STRYKER'S VIEW

- The patient is supine or erect, with the posterior aspect the affected shoulder against the cassette.
- The arm of the affected side is abducted to above shoulder level .
- Allow the hand to rest on the patients head.
 - The position of the cassette is adjusted so that it is centered to axilla

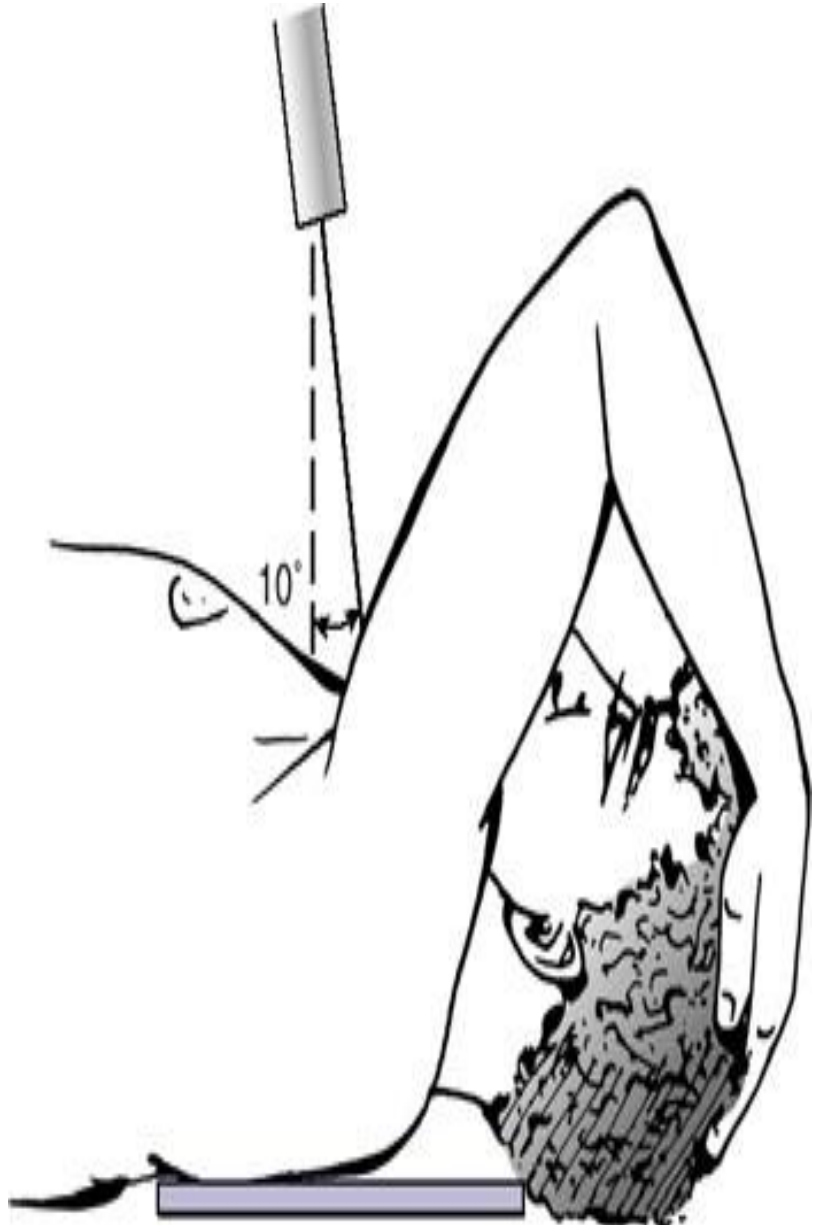
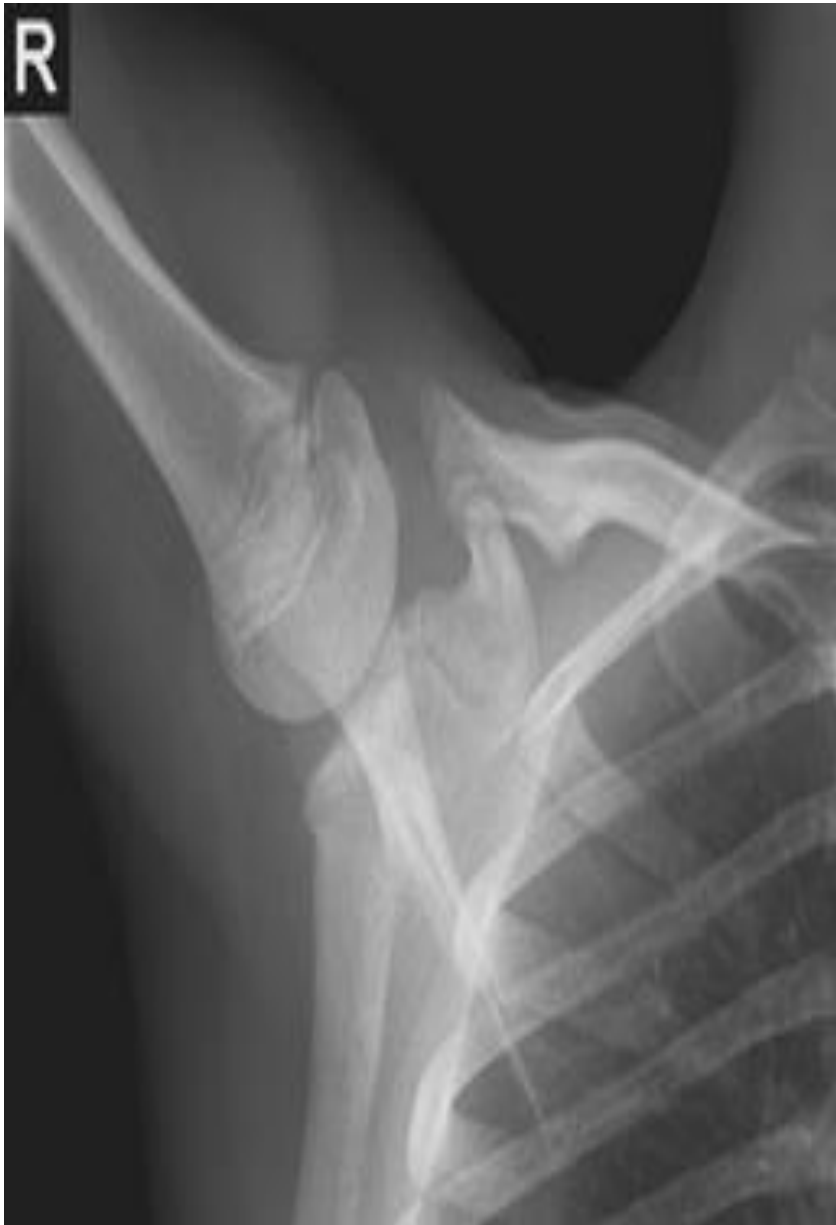STRYKER'S VIEW

Direction and centring of the X-ray beam

- Centered to the axilla of the affected side.

Essential image characteristics

- The clear view of posterior and superior aspects of the head of humerus.
- The inferior borders of glenoid fossa and joint will be seen.
- It is useful in detecting hill-sach's defects



Thank
you!





Radiology Techniques Department

Radiographic imaging

Radiographic position of hand

Lecture 7

د. حيدر سعيد شندل

M.B.CH.B MSc. RAD. (ASU)

Upper Limbs

The Upper Limbs consist of:

Scapula

Clavicle

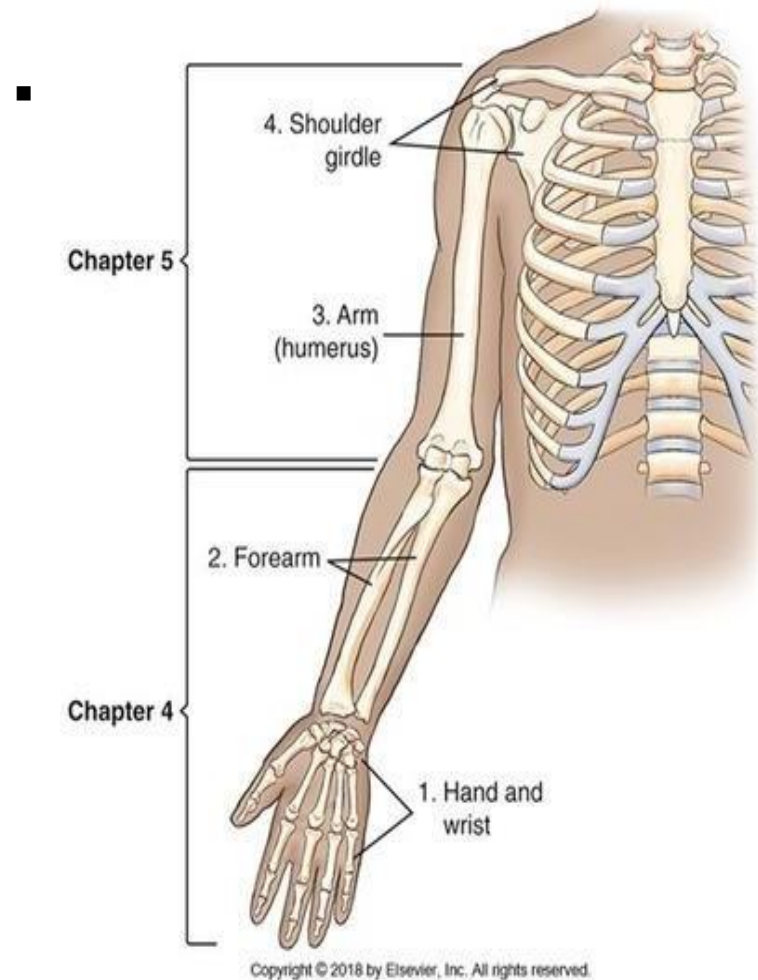
Shoulder Joint

Hummers (Arm)

Elbow Joint

Forearm (Radius, Ulna)

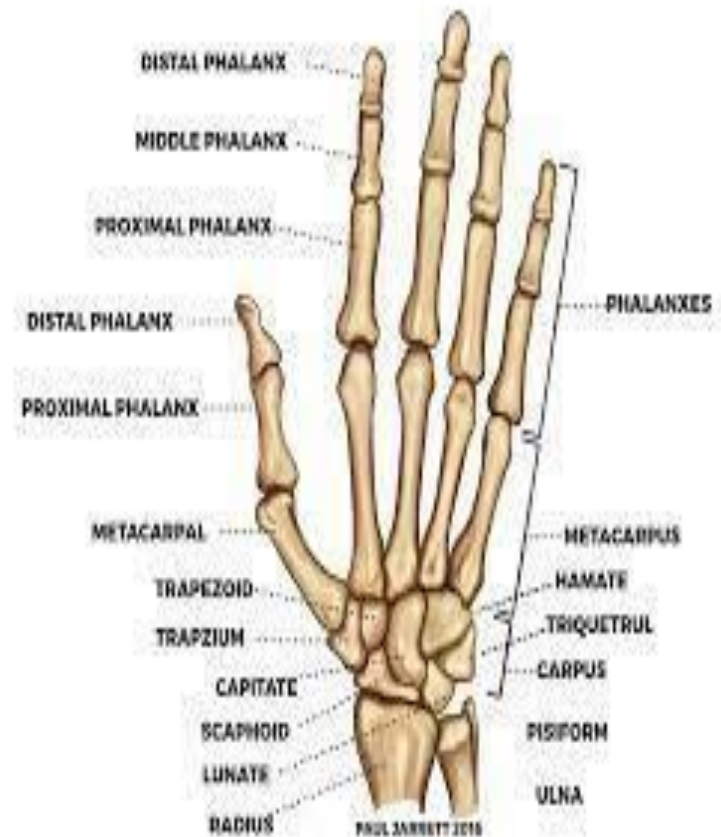Wrist Joint and Hand.



Hand and Wrist

The 27 bones on each hand and wrist are divided into the following three groups:

1. Phalanges (fingers and thumb) 14
 2. Metacarpals 5
 3. Carpals (wrist) 8
- Total 27

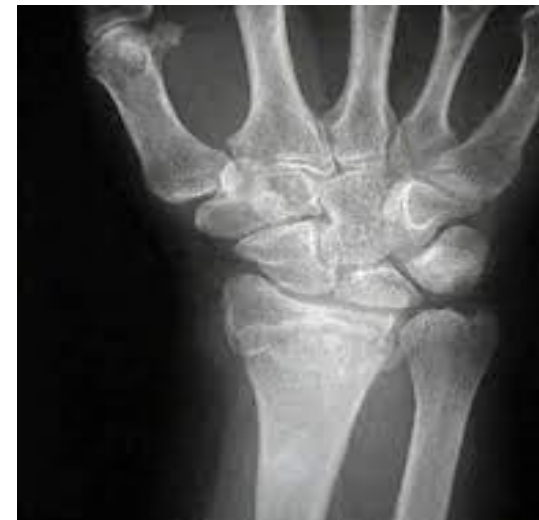

Clinical Indications

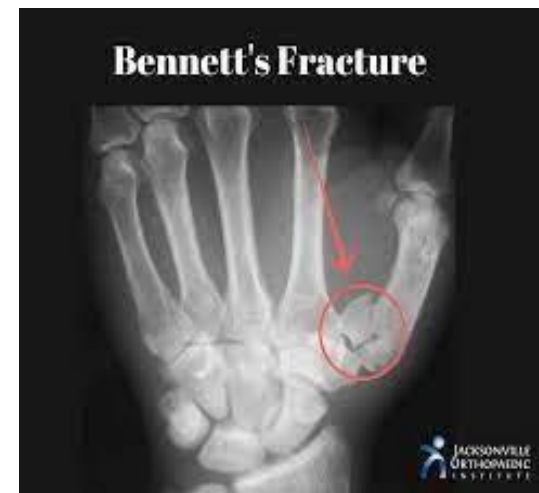Fracture A fracture is a break in the structure of bone caused by a force (direct or indirect). Numerous types of fractures have been identified; these are named by the extent of fracture, direction of fracture lines, alignment of bone fragments, and integrity of overlying tissue. Some common examples are as follows:

Barton's fracture: Fracture and dislocation of the posterior lip of the distal radius involving the wrist joint

Bennett's fracture: Fracture of the base of the first metacarpal bone, extending into the carpometacarpal joint, complicated by subluxation with some displacement



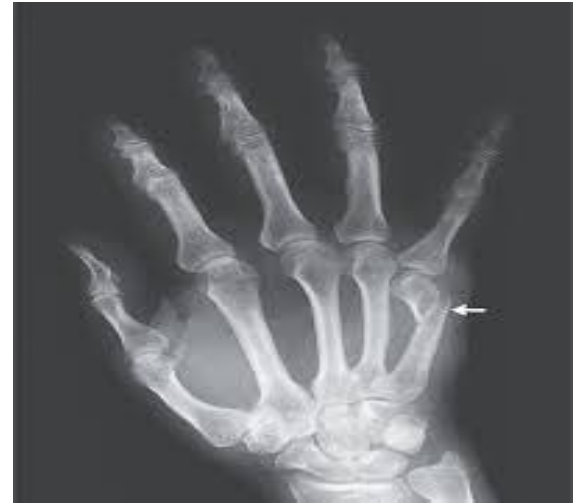Barton's fracture



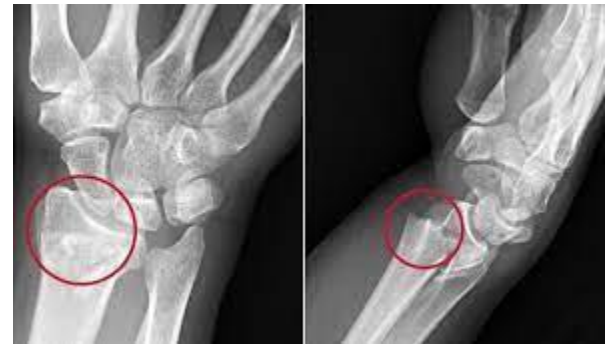Boxer's fracture: Transverse fracture that extends through the metacarpal neck; most commonly seen in the fifth metacarpal

Colles' fracture: Transverse- fracture of the distal radius in which the distal fragment is displaced posteriorly; an associated ulnar

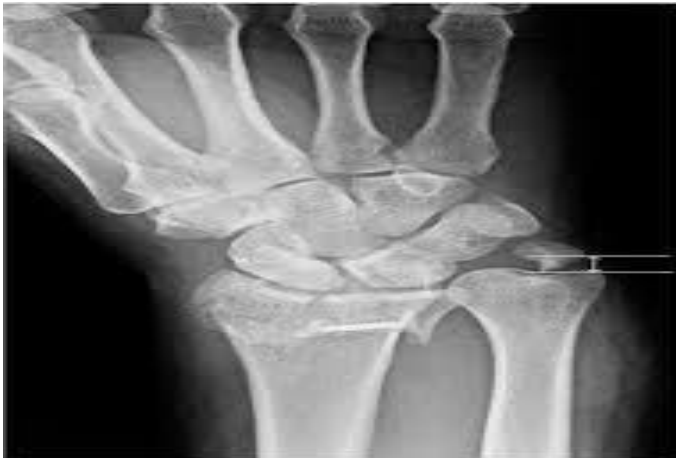styloid fracture seen in 50% to 60% of cases



Boxer's fracture:



Colles' fracture



styloid fracture

Hand positions

Basic projections of Hand

It is common practice to obtain three projections,

1- postero-anterior(PA)

2- Anterior oblique

3- Lateral

All on one 24 x 30-cm (10x12 inches) cassette.

Postero-anterior (PA)

Position of patient

- The patient is seated alongside the table with the affected arm nearest to the table.
- The forearm is pronated and placed on the table with the palmer surface of the hand in contact with the cassette.
- The fingers are separated and extended but relaxed to ensure that they remain in contact with the cassette.
- The wrist is adjusted so that the radial and ulna styloid processes are equidistant from the cassette.
- A sandbag is placed over the lower forearm for immobilization

Postero-anterior(PA)

Direction and centring of the X-ray beam

- The vertical central ray is centred over the head of the third metacarpal

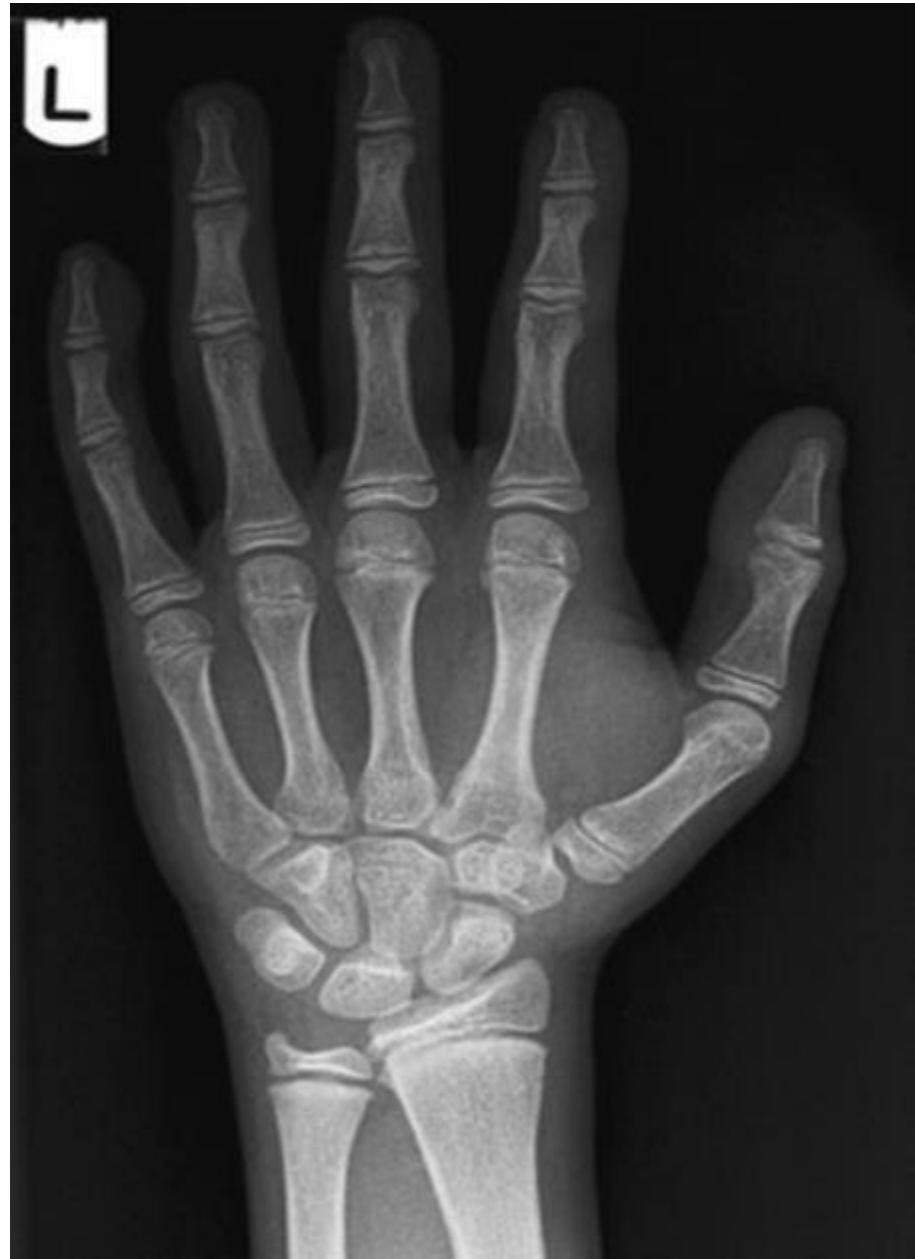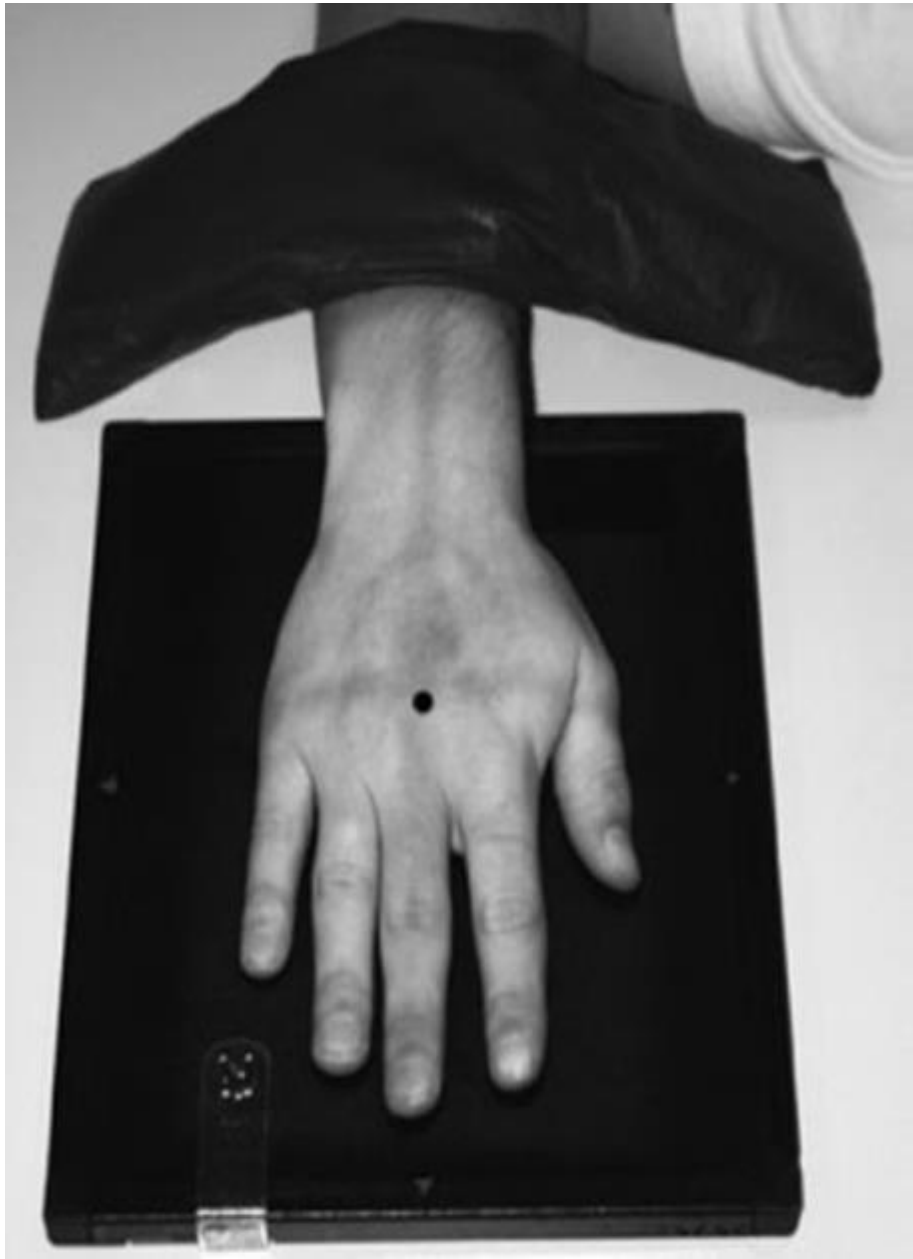
Size of cassette

- 24 x 30-cm (10x12 inches) cassette crosswise
- Digital screen, use lead masking
- Remove any opaque material

Postero-anterior(PA)

Essential image characteristics

- The image should demonstrate all the phalanges, including the soft-tissue fingertips, the carpal and metacarpal bones and the distal end of the radius and ulna.
- The inter-phalangeal and metacarpo-phalangeal and carpometacarpal joints should be demonstrated clearly.
- No rotation.



Anterior oblique

Position of patient

- From the basic postero-anterior position, the hand is externally rotated 45 degrees with the fingers extended.
- The fingers should be separated slightly and the hand supported on a 45-degree non-opaque pad.
- A sandbag is placed over the lower end of the forearm for immobilization.

Anterior oblique

Direction and centring of the X-ray beam

- The vertical central ray is centred over the head of the fifth metacarpal.
- The tube is then angled so that the central ray passes through the head of the third metacarpal, enabling a reduction in the size of the field.

Size of cassette

- 24 x 30-cm (10x12 inches) cassette crosswise
- Digital screen, use lead masking
- Remove any opaque material

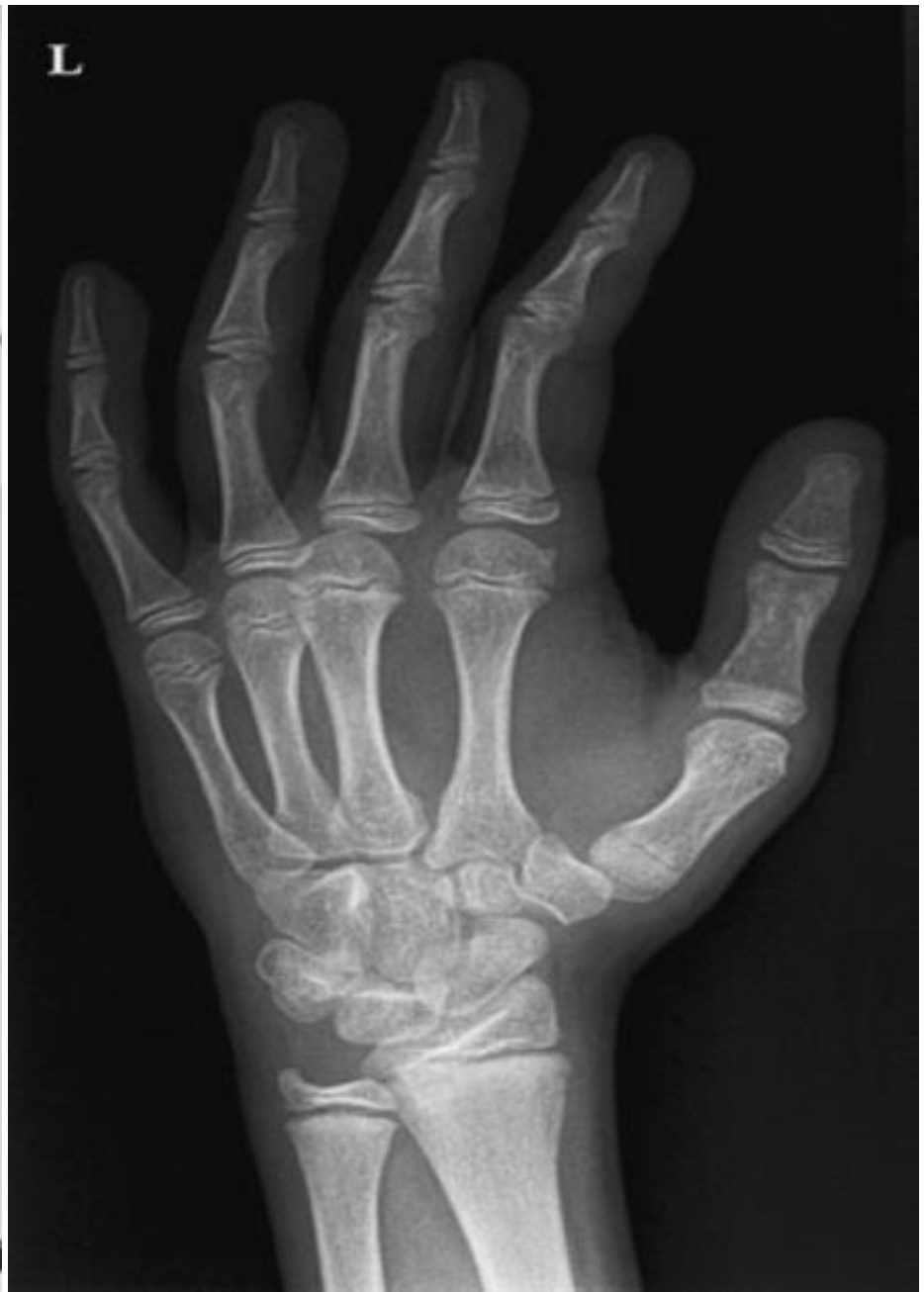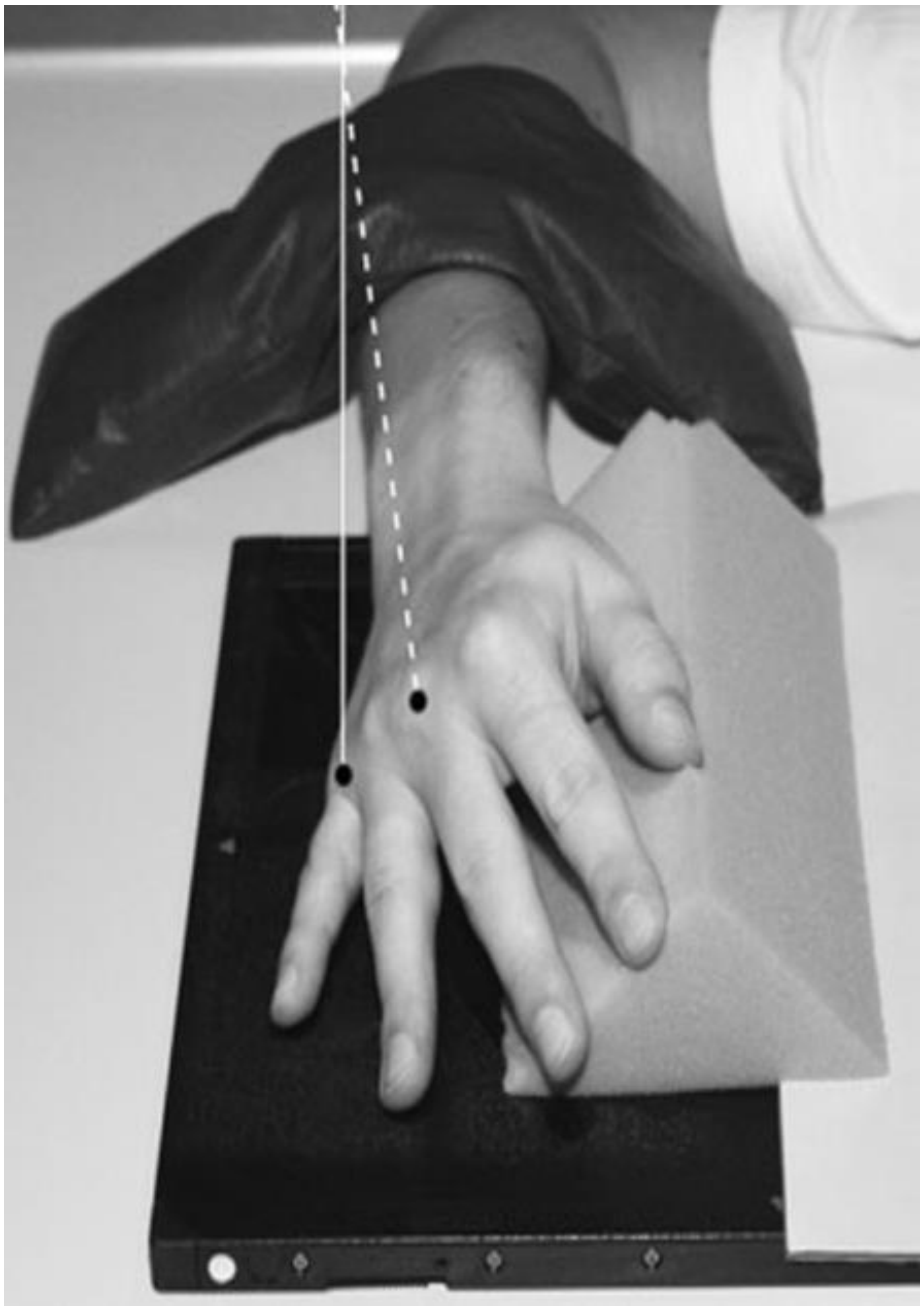Collimation

Collimate on four sides to outer margins of hand and wrist.

Anterior oblique

Essential image characteristics

- The image should demonstrate all the phalanges, including the soft-tissue of the fingertips, the carpal and metacarpal bones, and the distal end of the radius and ulna.
- The correct degree of rotation has been achieved when the heads of the first and second metacarpals are seen separated those of the fourth and fifth are just superimposed.

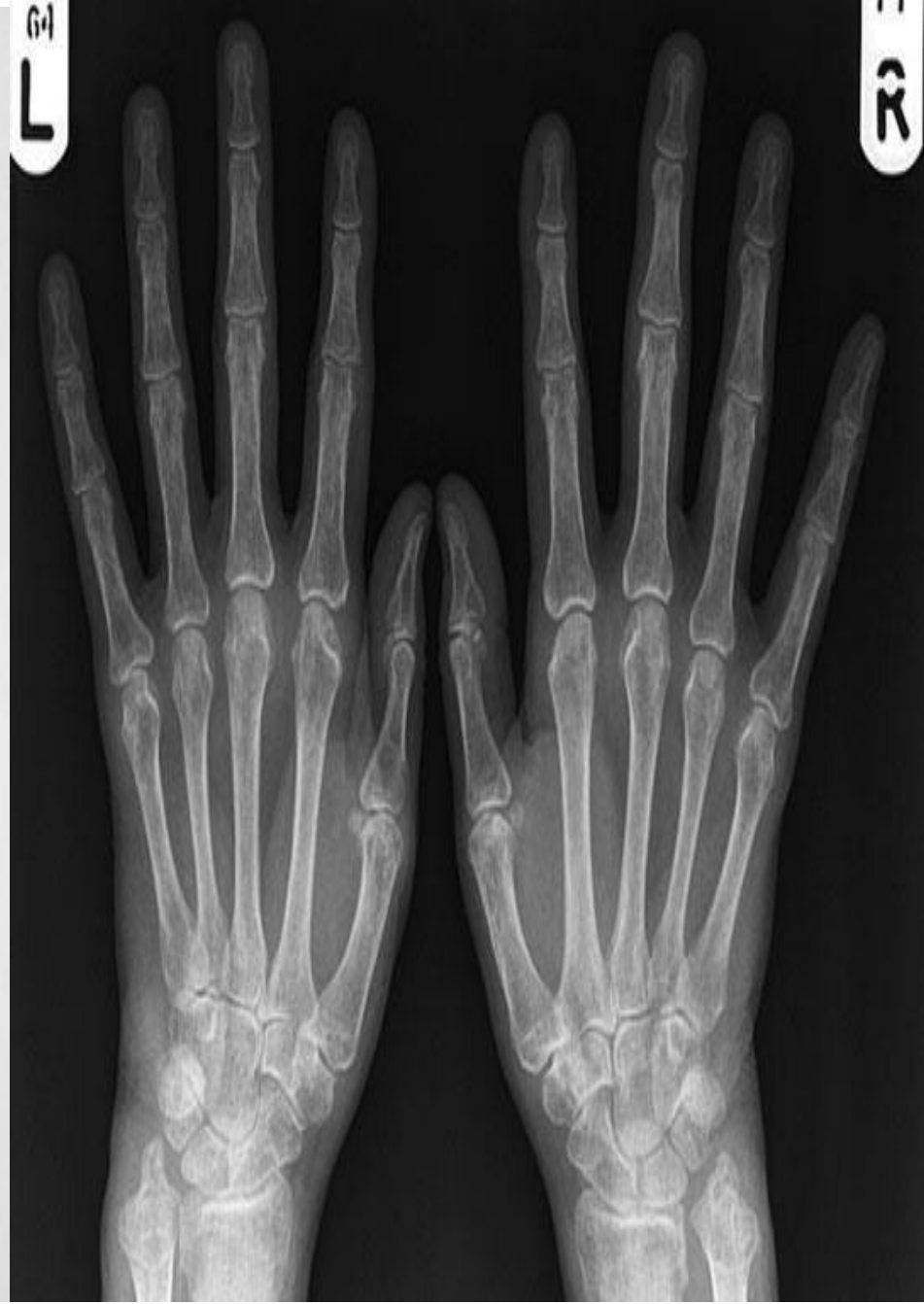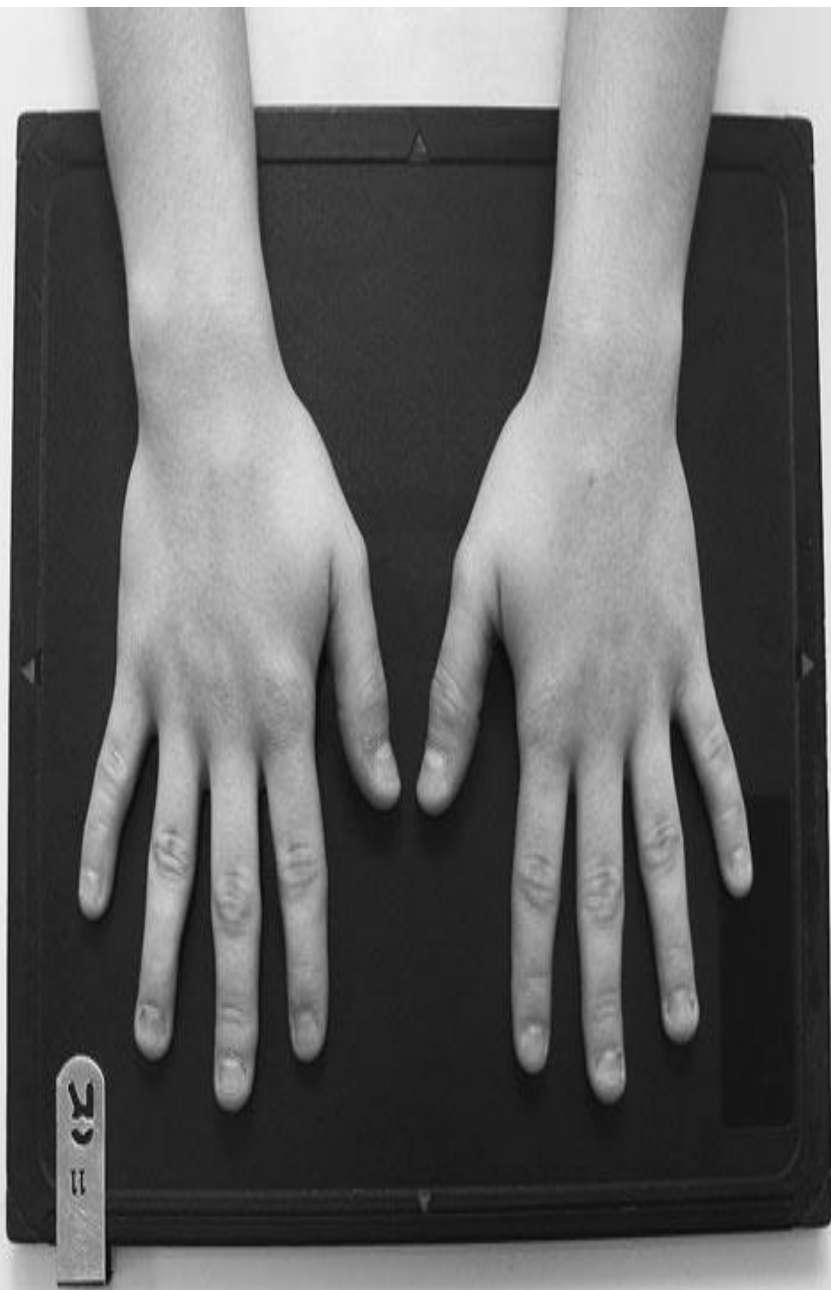


Postero-anterior – both hands

This projection is often used to demonstrate subtle radiographic changes associated with early rheumatoid arthritis and to monitor the progress of the disease.

Direction and centring of the X-ray beam

- The vertical central is centred over a point midway between the inter-phalangeal joints of both thumbs.



Posterior oblique – both hands
(ball catcher's or Nørgaard projection)

This projection may be used in the diagnosis of rheumatoid arthritis. It can also be used to demonstrate a fracture of the base of the fifth metacarpal.

Posterior oblique – both hands

Position of patient

- Seat the patient at the end of the radiographic table
Have the patient place the palms of both hands together.
- Center the MCP joints on the medial aspect of both hands to the cassette. Both hands should be in the lateral position.

Posterior oblique – both hands

- Place two 45° radiolucent sponges against the posterior aspect of each of the patient's hands to a half-supinate position until the dorsal surface of each hand rests against each 45° sponge support
- Extend the patient's fingers, and abduct the thumbs slightly to avoid superimposition over the fingers

Posterior oblique – both hands

centring of the X-ray beam

- to a point midway between the hands at the level of the fifth metacarpo-phalangeal joints.

Size of cassette

- 24 x 30-cm (10x12 inches) cassette crosswise
- Digital screen, use lead masking
- Remove any opaque material

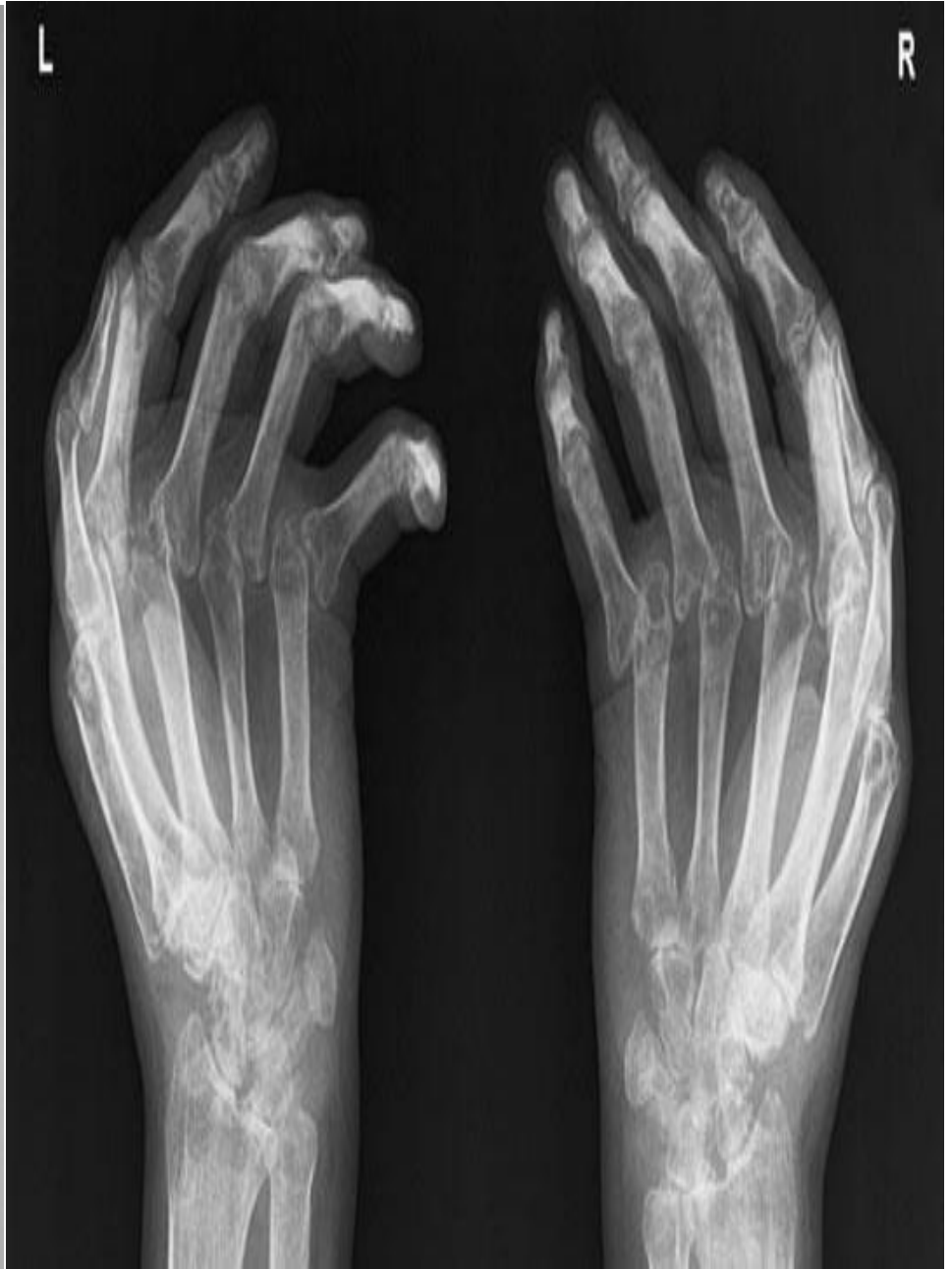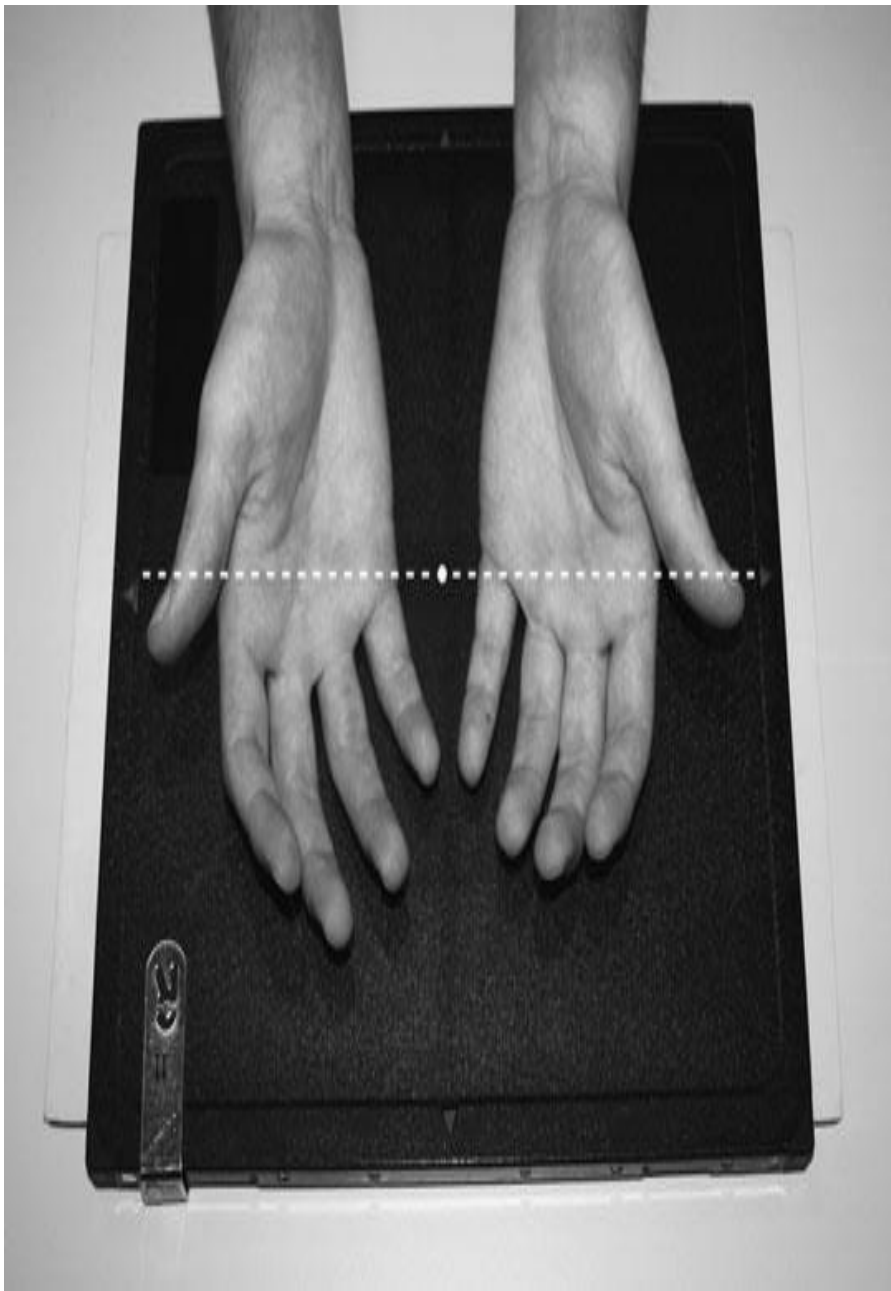Collimation

Collimate on four sides to outer margins of hand and wrist.

Posterior oblique – both hands

Essential image characteristics

- Entire hand, wrist, and about part of the distal forearm should be visible.
- Fingers should appear equally separated, with phalanges in the lateral position and joint spaces open, indicating fingers were parallel to the IR.
- Thumb should appear in a slightly oblique position completely free of superimposition, with joint spaces



Lateral position

- This is used in addition to the routine postero-anterior projection to locate a foreign body.
- It may also be used to demonstrate a fracture or dislocation of the carpal Bones

Lateral position

Position of patient

- Seat the patient at the end of the radiographic table with the forearm in contact with the table and the hand in the lateral position with the ulnar aspect down.
- Place the palmar surface perpendicular to the cassette.
- Center the cassette to the MCP joints, and adjust the midline to be parallel with the long axis of the hand and forearm.
- If the hand is resting on the ulnar surface, immobilization of the thumb may be necessary

Lateral position

Important note

when place the radial side of the wrist against the cassette. However, this position is more difficult for the patient.

- If the elbow is elevated, support it with sandbags

Lateral position

Centering of x-ray

- The vertical central ray is centred over the head of the second metacarpal

Size of cassette

- 24 x 30-cm (10x12 inches) cassette crosswise
- Digital screen, use lead masking
- Remove any opaque material

Collimation

Collimate on four sides to outer margins of hand and wrist.

Lateral position

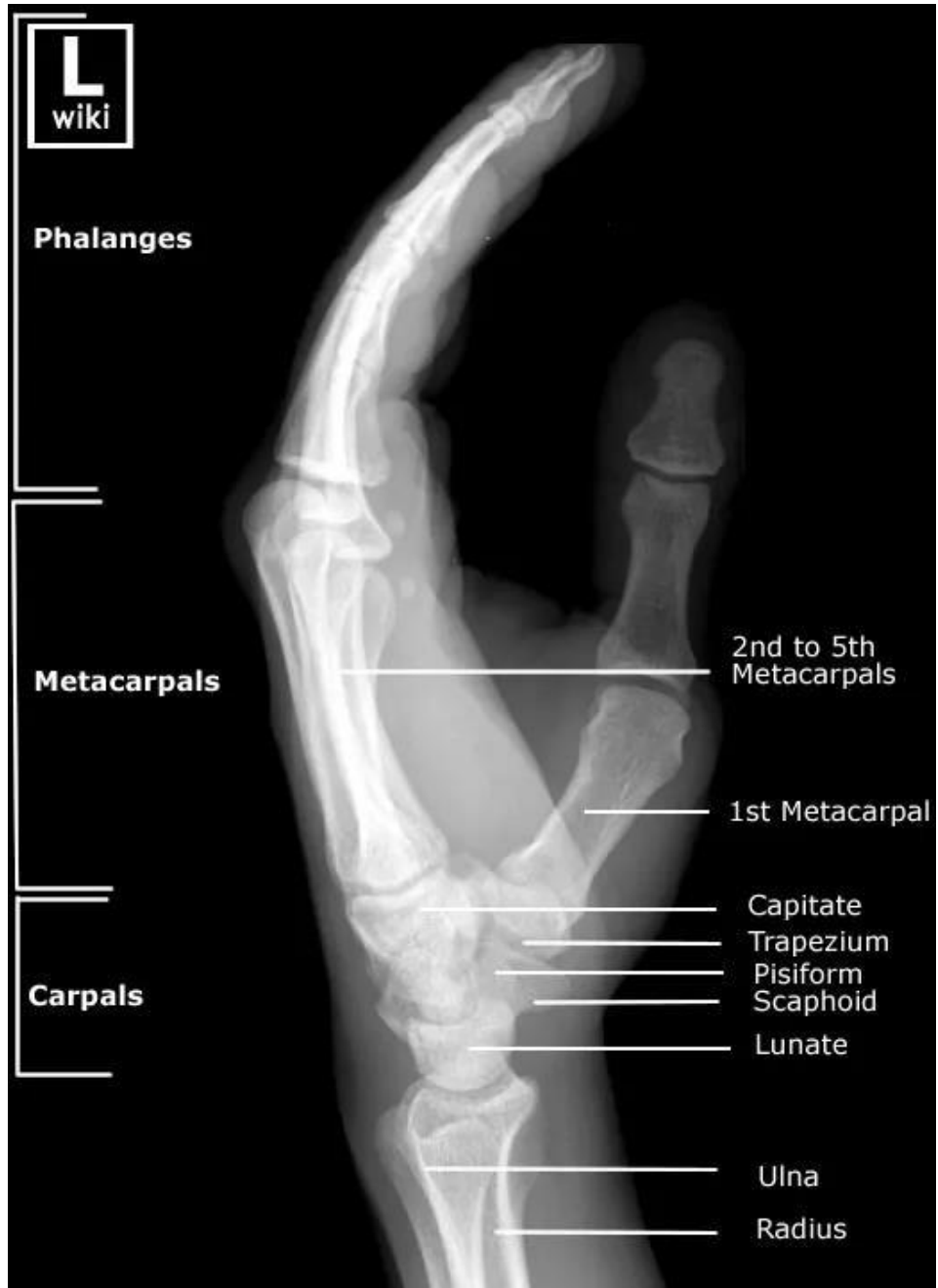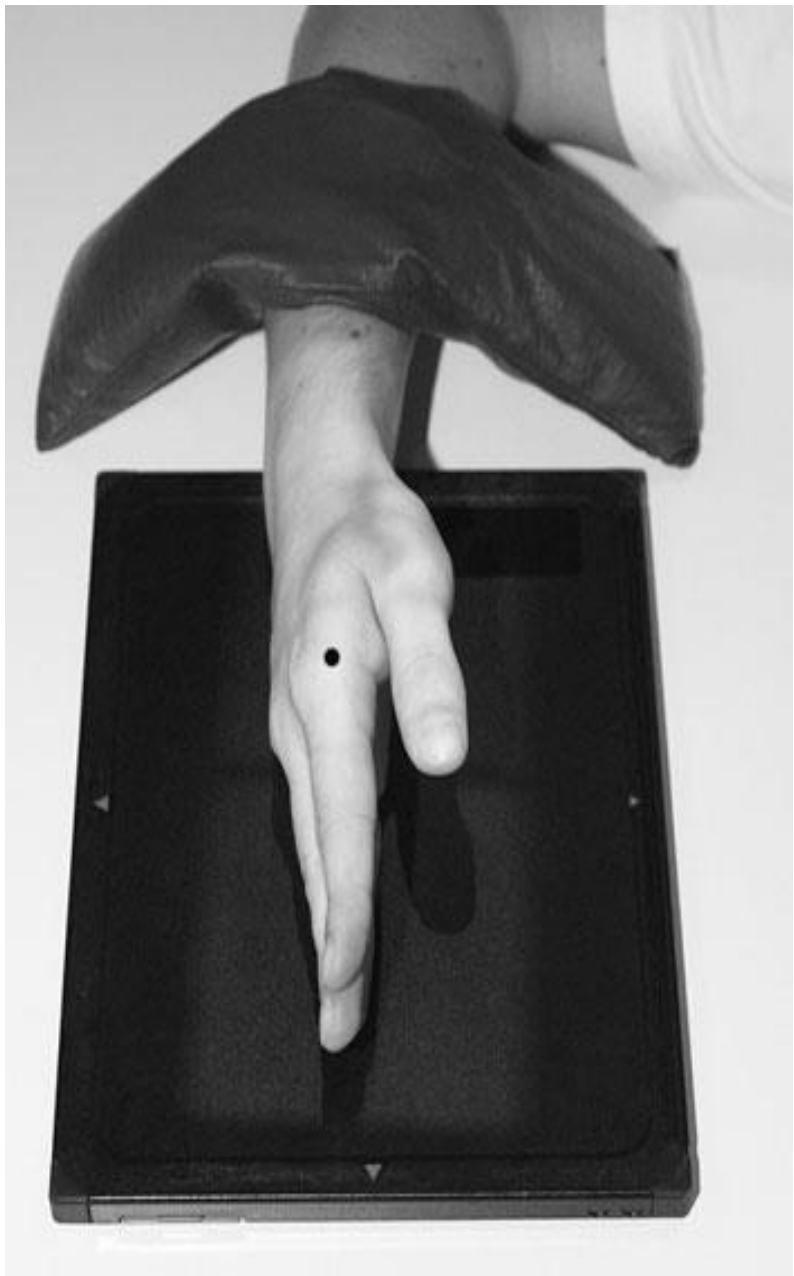
Essential image characteristics

- Entire hand, wrist, and about part of the distal forearm should be visible.
- Thumb should appear in a slightly oblique position completely free of superimposition, with joint spaces open.

.

Lateral position

- Long axis of hand and wrist should be aligned to the long axis of the IR.
- Hand and wrist should be in a true-lateral position, evidenced by the following: Distal radius and ulna superimposed; metacarpals should be superimposed



Fan lateral

In lateral position, the the phalanges are superimposed
So that there is other position

the fan-lateral position, which

eliminates superimposition of all but the proximal
phalanges.

Patient Position:

- Seat patient at end of table with elbow flexed about 90 degrees and hand and forearm resting on table.

Fan lateral

- Align long axis of hand with long axis of IR.
- Rotate hand and wrist into lateral position with thumb side up.
- Spread fingers and thumb into a "fan" position, and support each digit on radiolucent block as shown.
- Ensure all digits, including the thumb, are separated and parallel to IR, and that the metacarpals are not rotated but remain in a lateral position.

Fan lateral

Centering of x-ray

CR perpendicular to IR, directed to second MCP joint

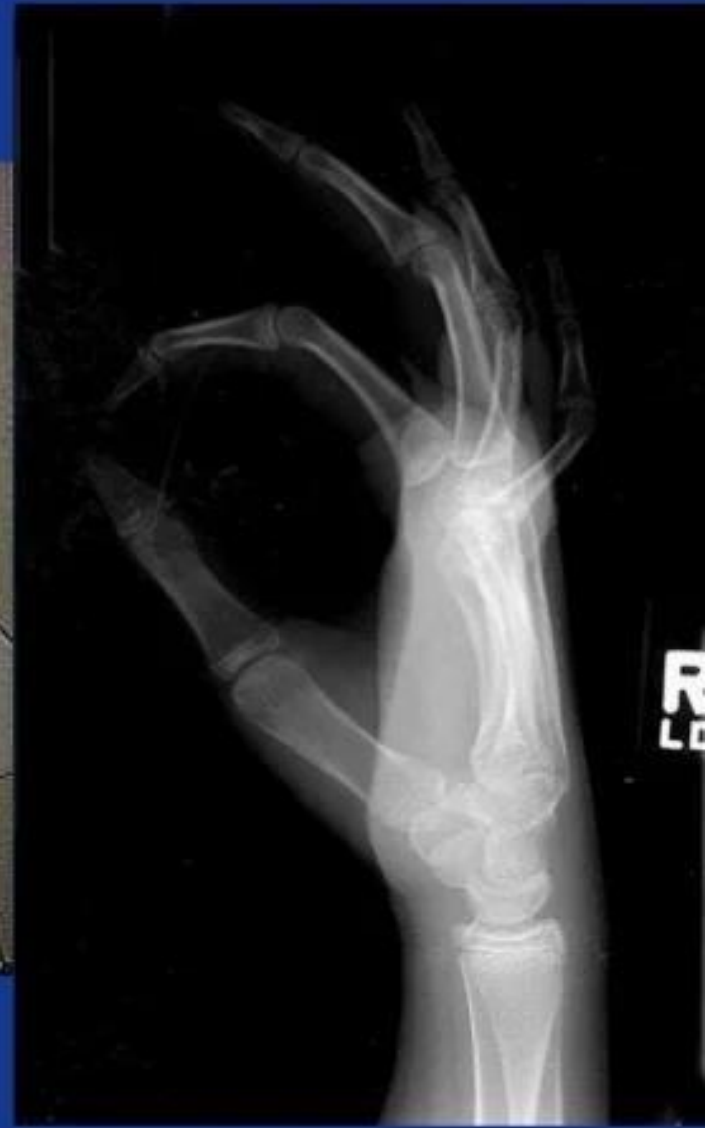Collimation

Collimate on four sides to outer margins of hand and wrist.

Size of cassette

- 24 x 30-cm (10x12 inches) cassette crosswise
- Digital screen, use lead masking
- Remove any opaque material

Fan Lateral



Thump

It is common practice to obtain two projections, an antero-posterior and a lateral

Lateral

- The thumb is flexed slightly and the palm of the hand is placed on the cassette
- The palm of the hand is raised slightly with the fingers partially flexed and supported on a non-opaque pad, such that the lateral aspect of the thumb is in contact with the cassette

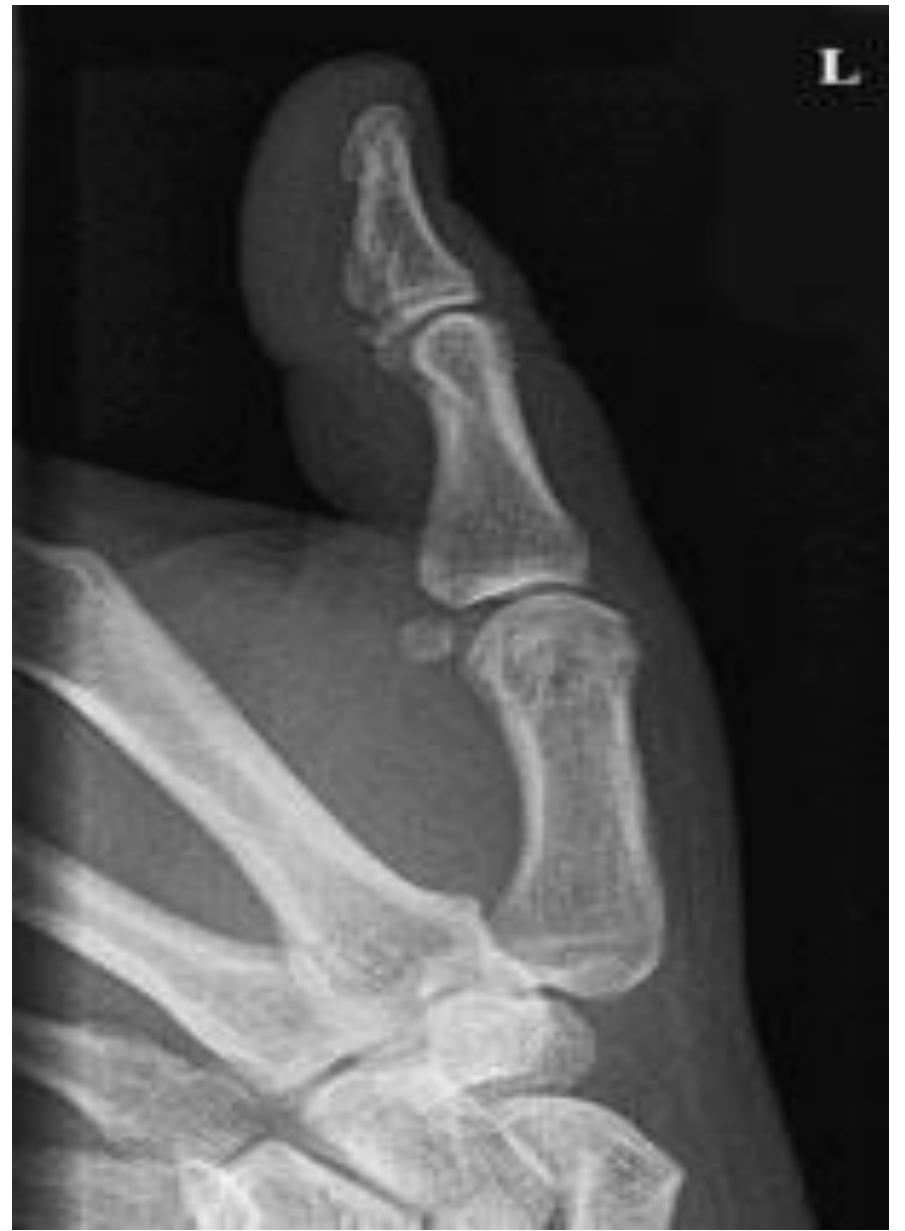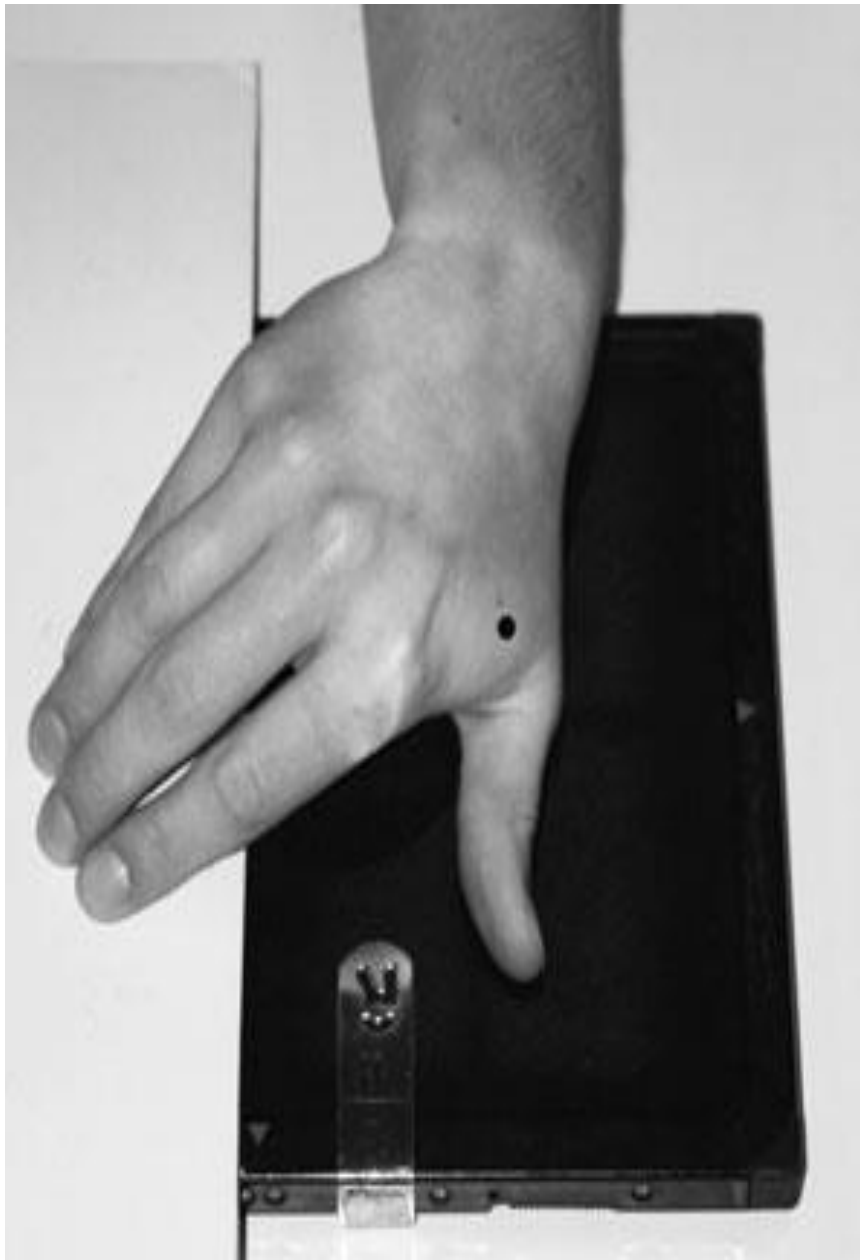Lateral

Direction and centring of the X-ray beam

- The vertical central ray is centred over the first metacarpo phalangeal joint.

Essential image characteristics

- Where there is a possibility of injury to the base of the first metacarpal, the carpo-metacarpal joint must be included on the image.



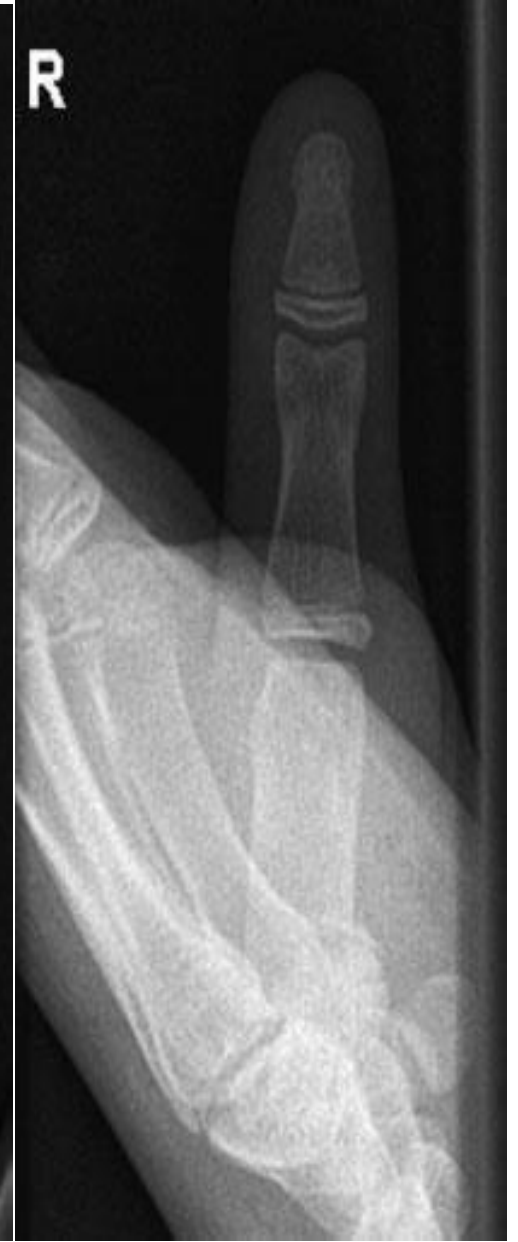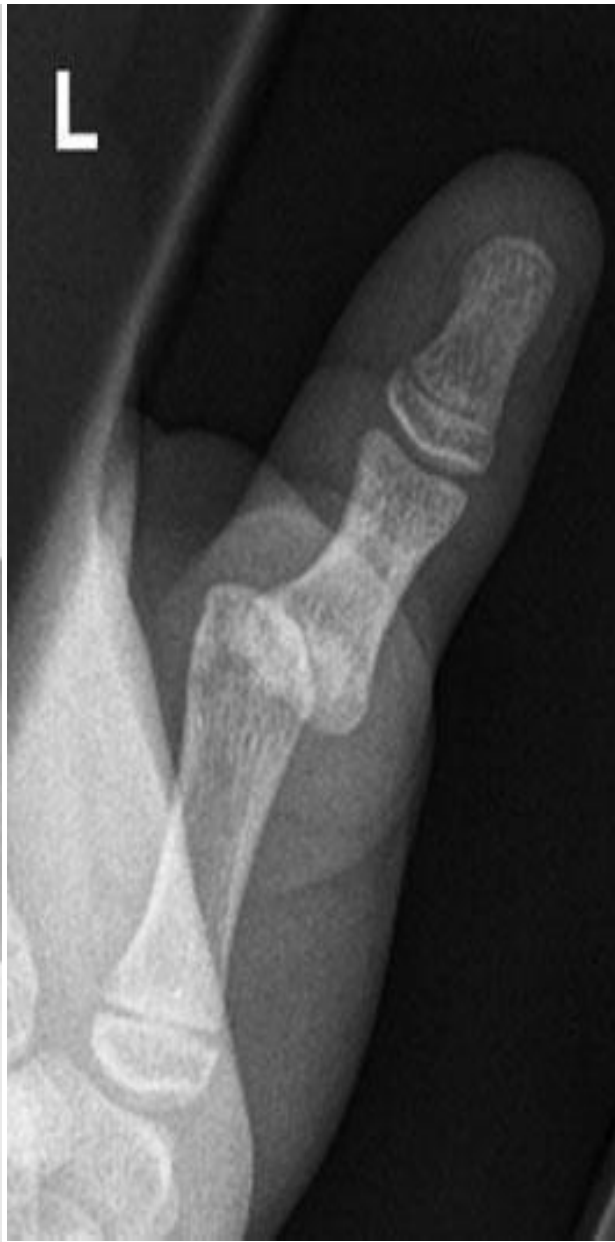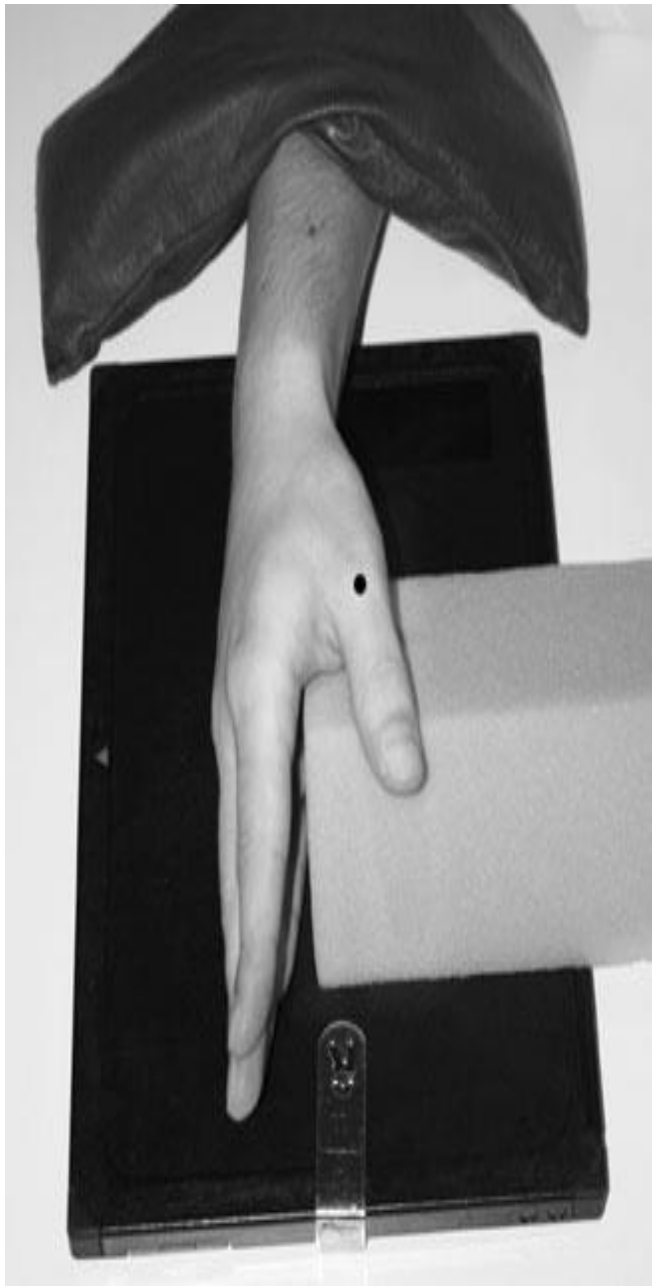
Postero-anterior

Postero-anterior

- With the hand in the postero-anterior position, the palm of the hand is rotated through 90 degrees to bring the medial aspect of the hand in contact with the table and the palm vertical.
- The fingers are extended and the hand is rotated slightly forwards until the anterior aspect of the thumb is parallel to the cassette.
- The thumb is supported in position on a non-opaque pad.
-

Postero-anterior

- The vertical central ray is centred to the first metacarpophalangeal joint
- The use of the postero-anterior projection maintains the relationship of the adjacent bones, i.e. the radius and ulna, which is essential in cases of suspected foreign body



Scaphoid

Postero-anterior – ulnar deviation

The projections may also be used to demonstrate other carpal bones.

For scaphoid fractures, three projections are normally taken:

postero-anterior, anterior oblique and lateral.

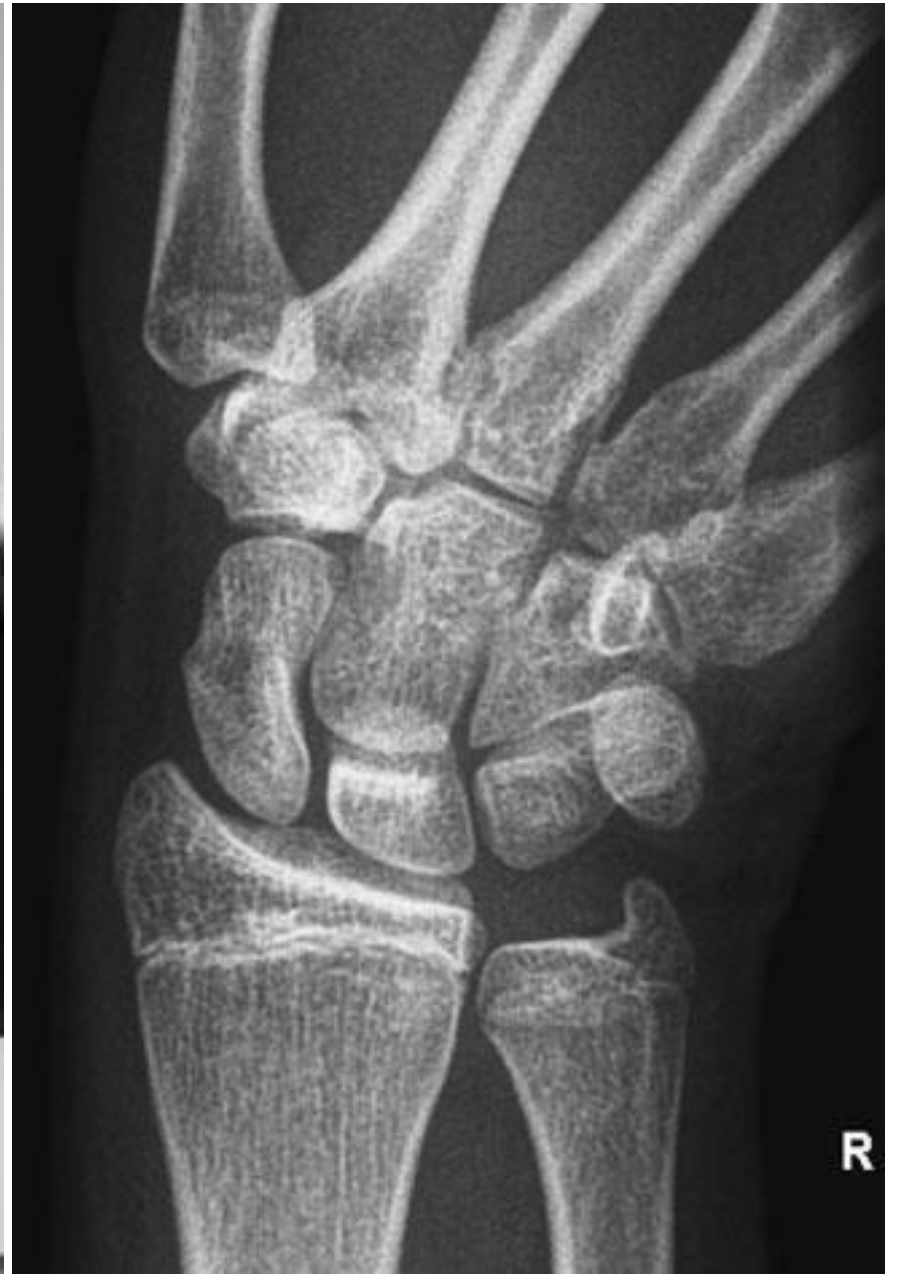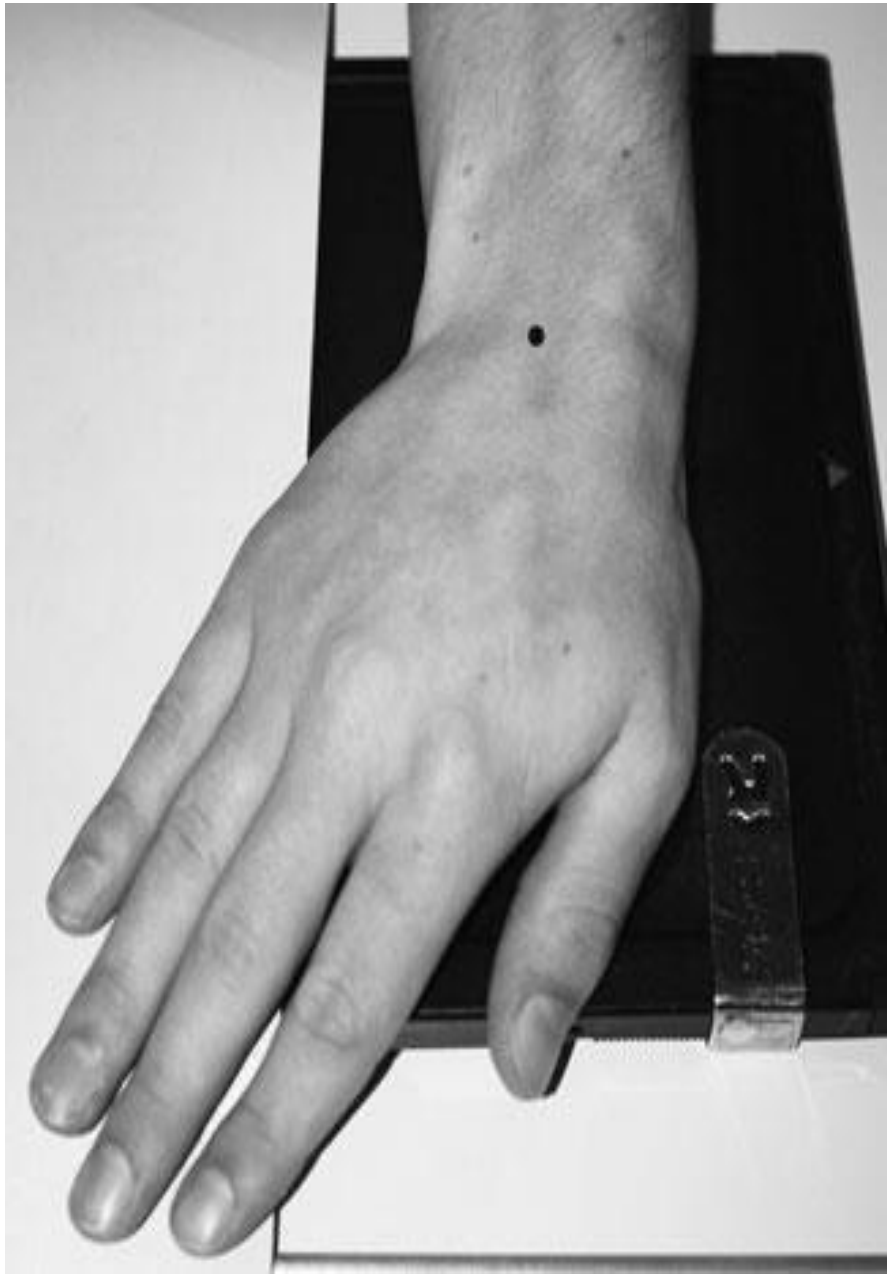
Scaphoid

- The patient is seated alongside the table with the affected side nearest the table.
- The arm is extended across the table with the elbow flexed and the forearm pronated.
- If possible, the shoulder, elbow and wrist should be at the level of the tabletop.
- the hand is adducted (ulnar deviation).
- The vertical central ray is centred midway between the radial and ulnar styloid processes

Scaphoid

Essential image characteristics

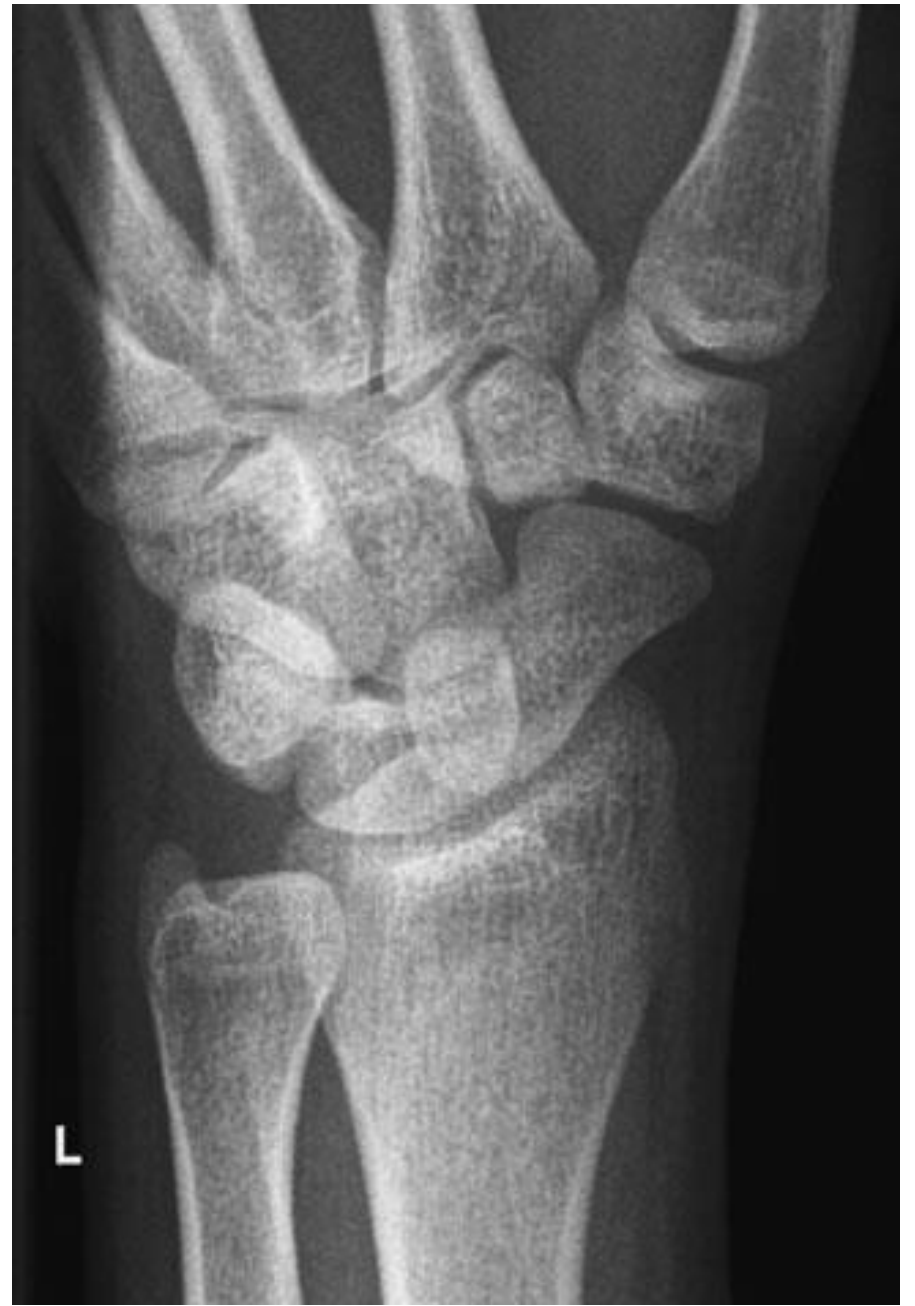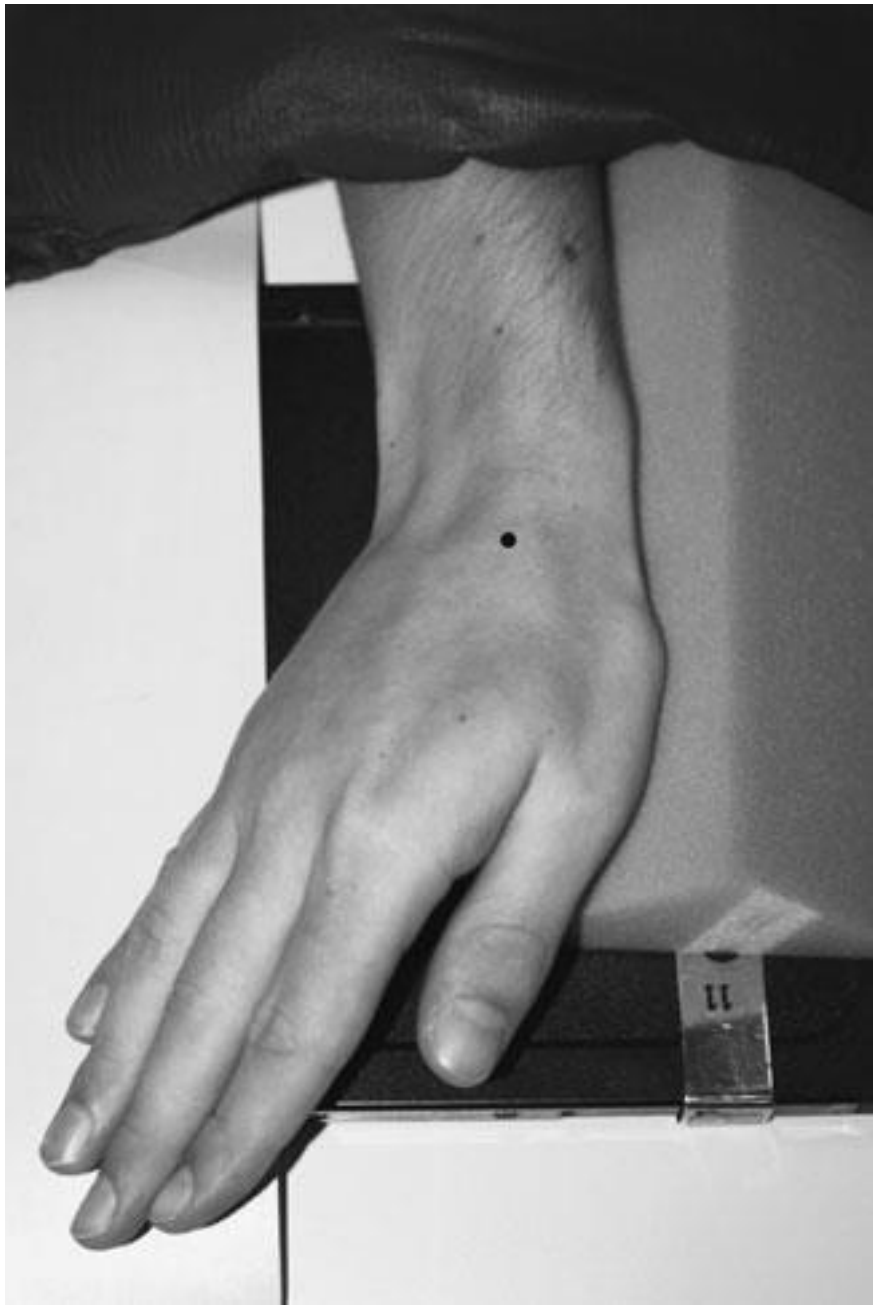- The image should include the distal end of the radius and ulna and the proximal end of the metacarpals.
- The joint space around the scaphoid should be demonstrated clearly



Scaphoid

Anterior oblique – ulnar deviation

- From the postero-anterior position, the hand and wrist are rotated 45 degrees externally. The hand should remain adducted in ulnar deviation.
- The hand is supported in position, with a non-opaque pad placed under the thumb.
- The forearm is immobilized using a sandbag.
- The vertical central ray is centred midway between the radial and ulnar styloid processes



Scaphoid

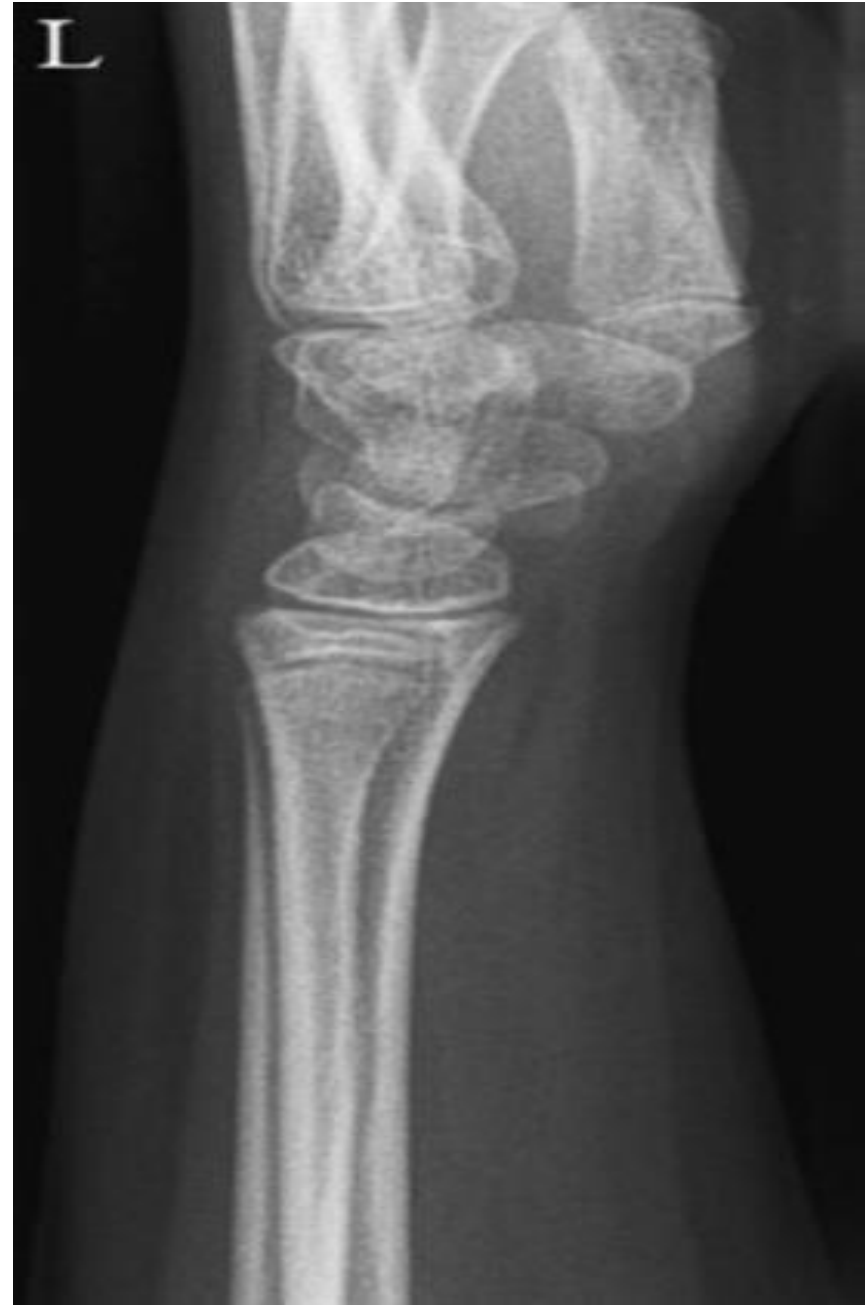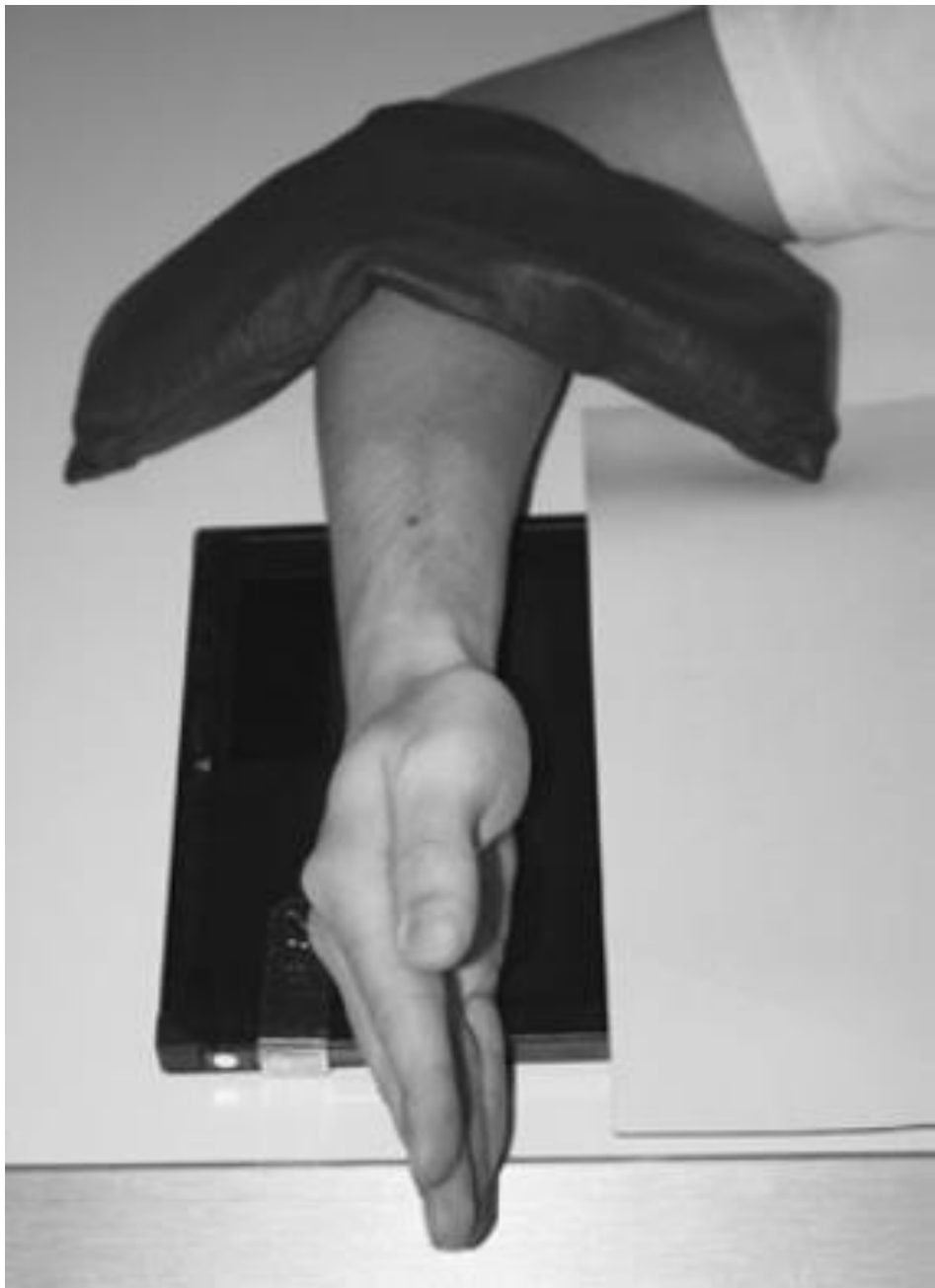Lateral

- From the posterior oblique position, the hand and wrist are rotated internally through 45 degrees, such that the medial aspect of the wrist is in contact with the cassette
- The hand is adjusted to ensure that the radial and ulnar styloid processes are superimposed.
- The vertical central ray is centred over the radial styloid process.

Scaphoid

Essential image characteristics

- The image should include the distal end of the radius and ulna and the proximal end of the metacarpals
- The image should demonstrate clearly any subluxation or dislocation of the carpal bones



Thank
you!





Radiology Techniques Department

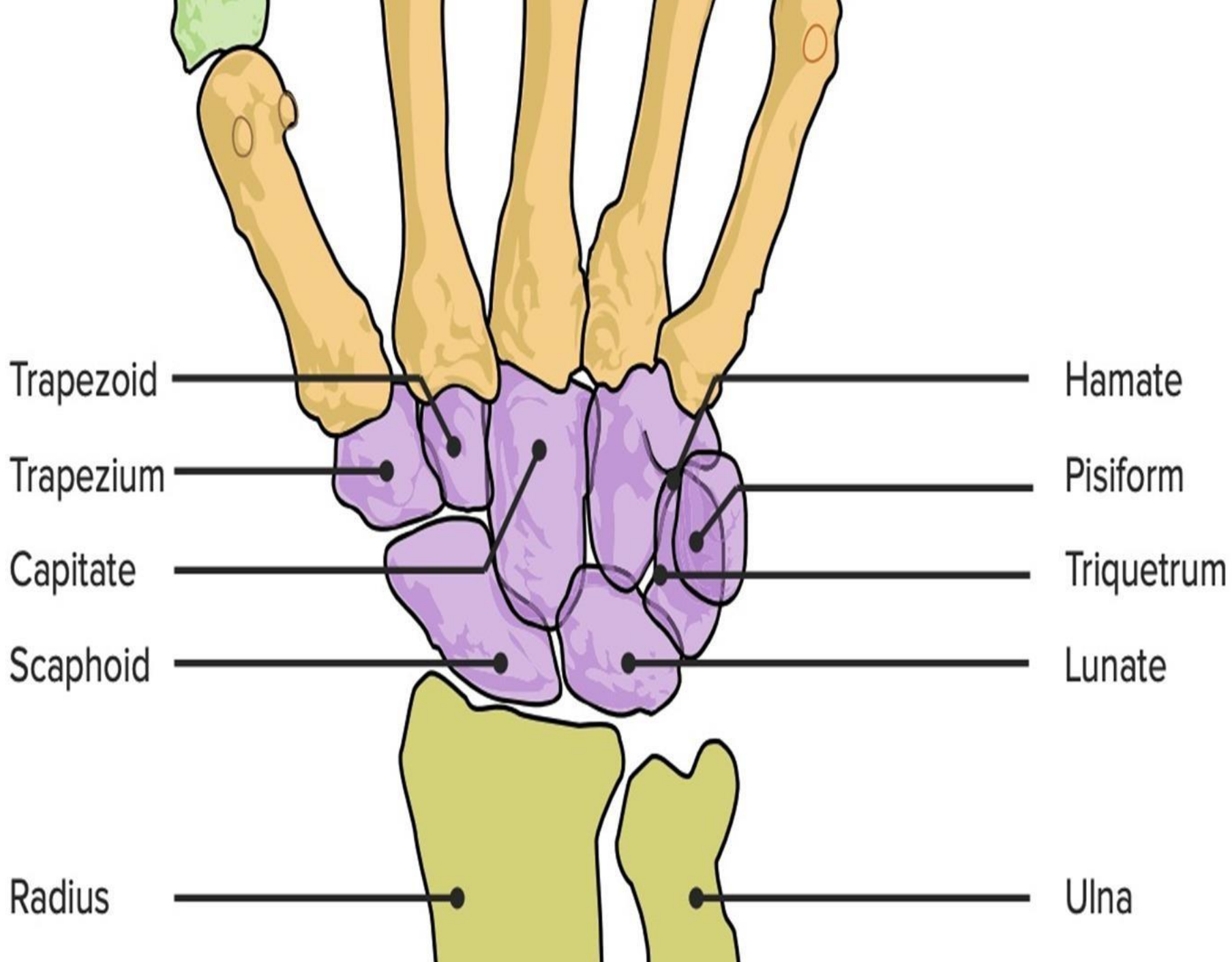
Radiographic imaging

Radiographic position of wrist joint

Lecture 8

د. حيدر سعيد شندل

M.B.CH.B MSc. RAD. (ASU)



Wrist

Basic projection a postero -anterior and a lateral

- The patient is seated alongside the table, with the affected side nearest to the table.
- The elbow joint is flexed to 90 degrees and the arm is abducted, such that the anterior aspect of the forearm and the palm of the hand rest on the cassette.
- If the mobility of the patient permits, the shoulder joint should be at the same height as the forearm.
- The wrist joint is placed on one half of the cassette and adjusted to include the lower part of the radius and ulna and the proximal two-thirds of the metacarpals

Wrist

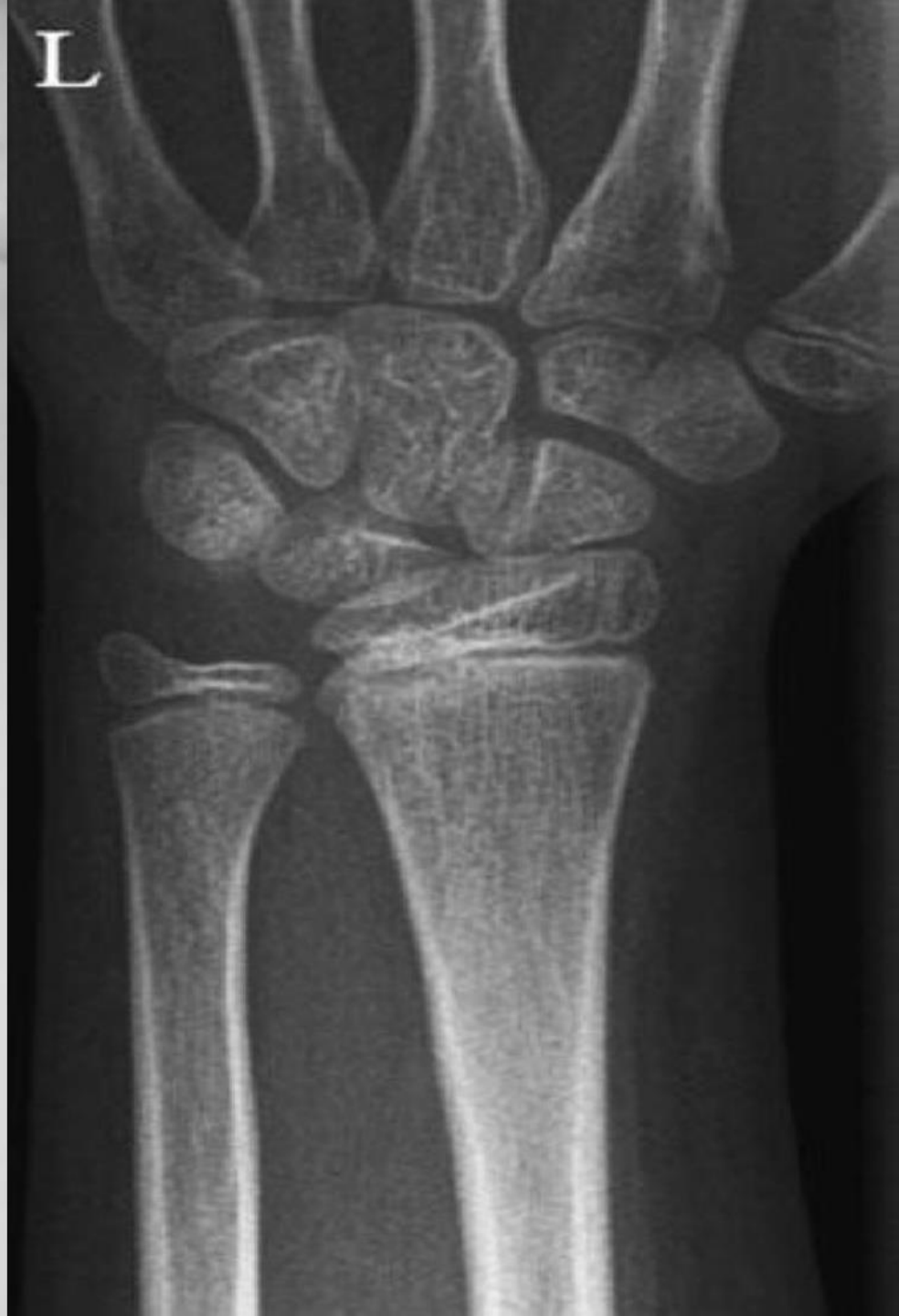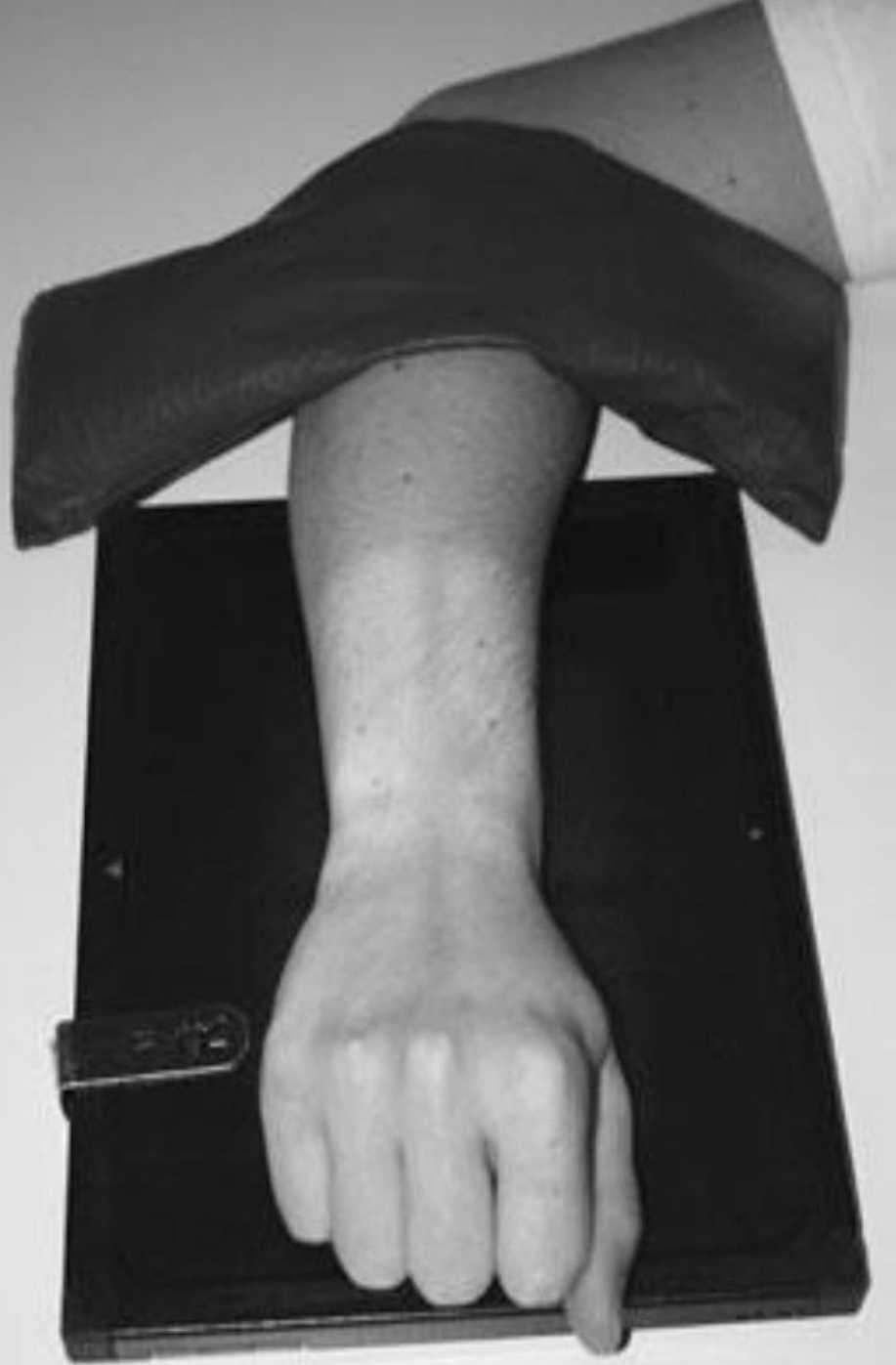The fingers are flexed slightly to bring the anterior aspect of the wrist into contact with the cassette

- The vertical central ray is centred to a point midway between the radial and ulnar styloid processes

Essential image characteristics

- The image should demonstrate the proximal two-thirds of the metacarpals, the carpal bones, and the distal third of the radius and ulna.

- There should be no rotation of the wrist joint



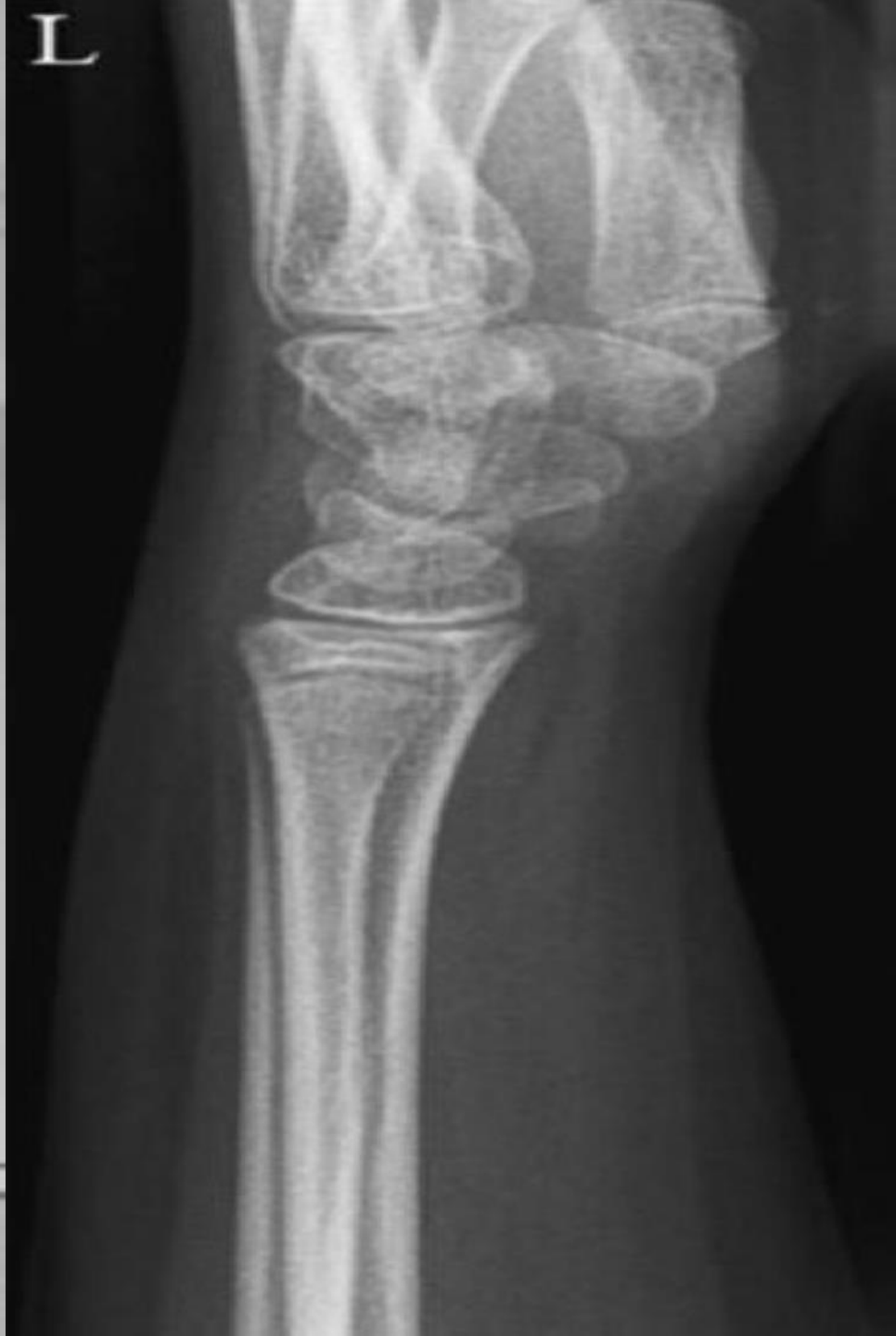Wrist

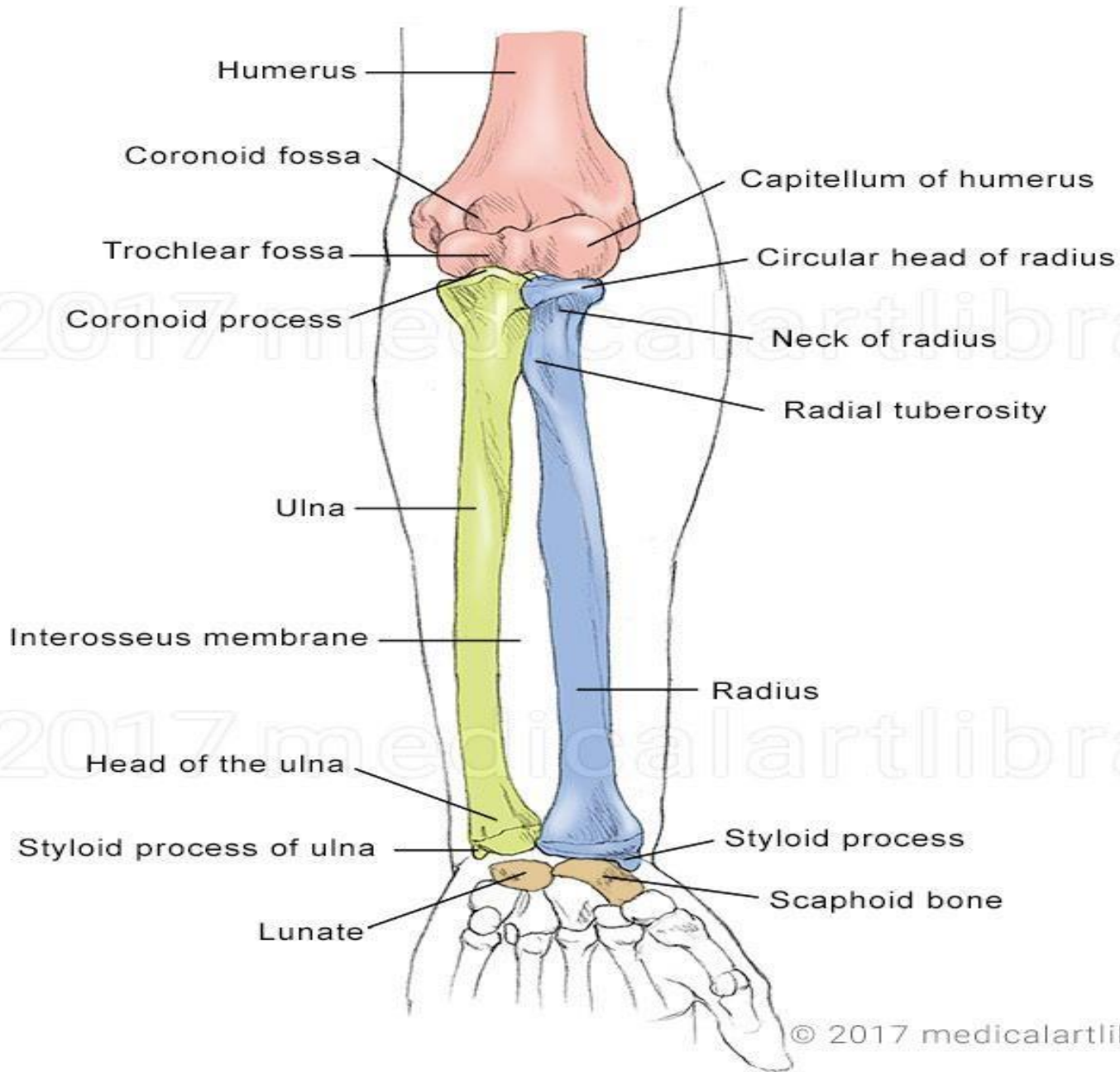
Lateral

- From the postero-anterior position, the wrist is externally rotated through 90 degrees, to bring the palm of the hand vertical. The hand is rotated externally slightly further to ensure that the radial and ulnar styloid processes are superimposed.
- The forearm is immobilized using sandbag.
- The vertical central ray is centred over the styloid process of the radius

Essential image characteristics

- The exposure should provide adequate penetration to visualize the carpal bones.
- The radial and ulnar styloid processes should be superimposed





Antero-posterior – basic

Position of patient and cassette

- The patient is seated alongside the table, with the affected side nearest to the table.
- The arm is abducted and the elbow joint is fully extended, with the supinated forearm resting on the table.
- The shoulder is lowered to the same level as the elbow joint

Antero-posterior – basic

- The cassette is placed out Bucky under the forearm to include the wrist joint and the elbow joint.
- film size 10x12 lengthwise
- The arm is adjusted such that the radial and ulnar styloid processes and the medial and lateral epicondyles are equidistant from the cassette.
- The lower end of the humerus and the hand are immobilized using sandbags

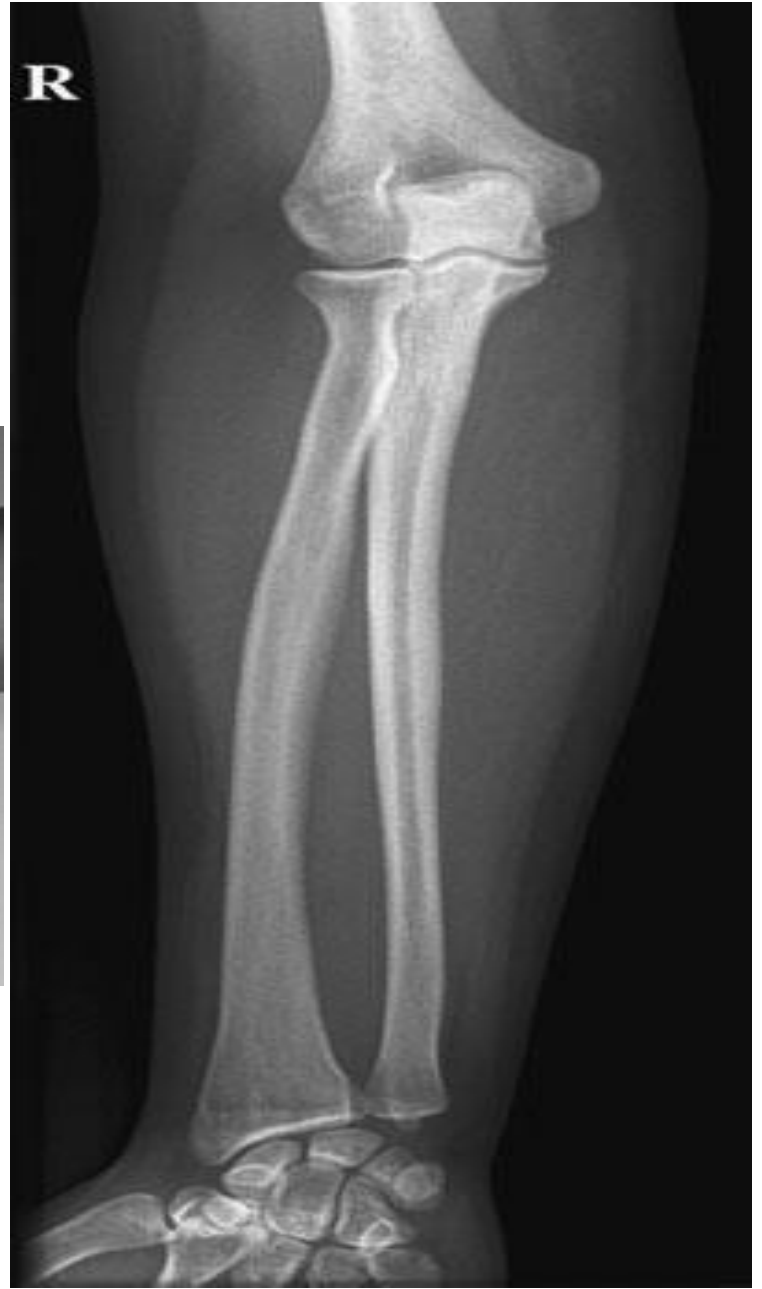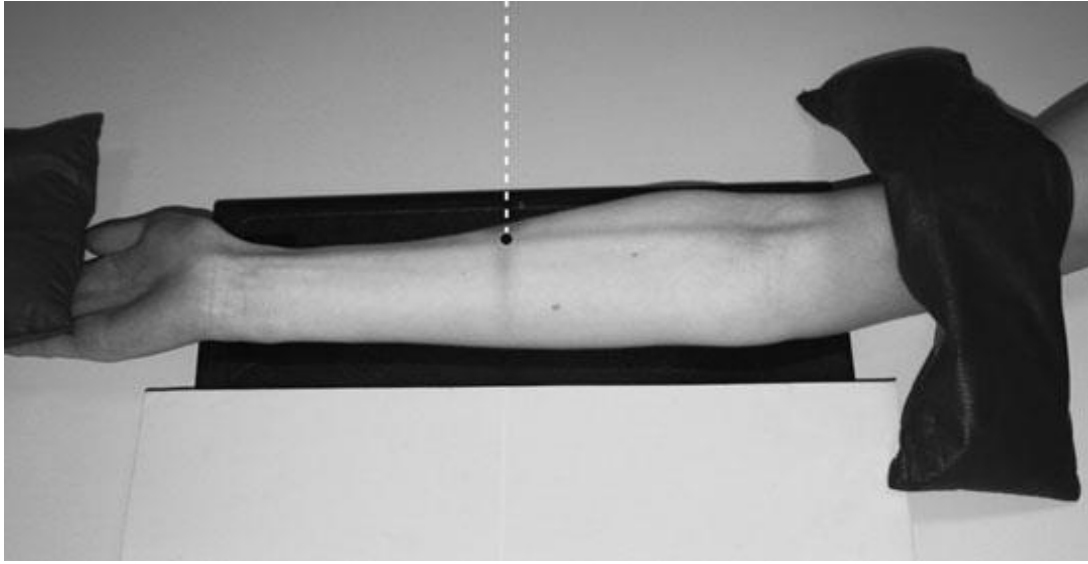
Antero-posterior – basic

Direction and centering of the X-ray beam

- The vertical central ray is centered in the midline of the forearm to a point midway between the wrist and elbow joints.

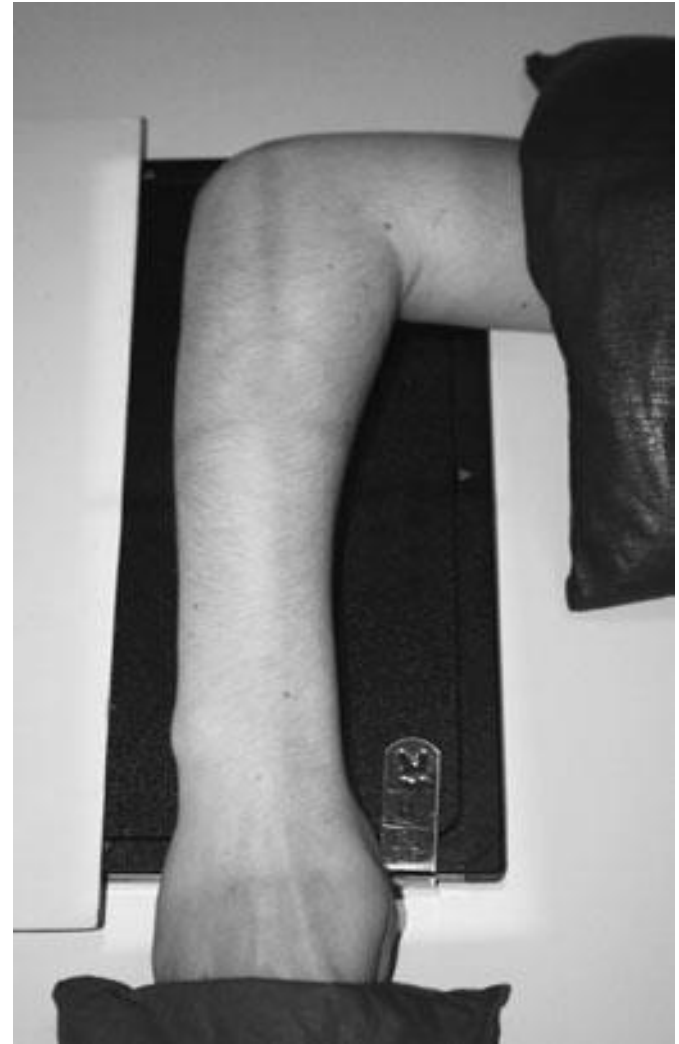Essential image characteristics

- Both the elbow and the wrist joint must be demonstrated on the cassette.
- Both joints should be seen in the true antero-posterior position, with the radial and ulnar styloid processes and the epicondyles of the humerus equidistant from the cassette



Important note

The postero-anterior projection of the forearm with the wrist pronated is not satisfactory because, in this projection, the radius is superimposed over the ulna for part of its length.



Lateral – basic

Position of patient and cassette

- From the antero-posterior position, the elbow is flexed to 90degrees.
- The humerus is internally rotated to 90 degrees to bring the medial aspect of the upper arm, elbow, forearm, wrist and hand into contact with the table.
- The cassette is placed under the forearm to include the wrist joint and the elbow joint.
- The arm is adjusted such that the radial and ulnar styloid processes and the medial and lateral epicondyles are superimposed.
- The lower end of the humerus and the hand are immobilized using sandbags.

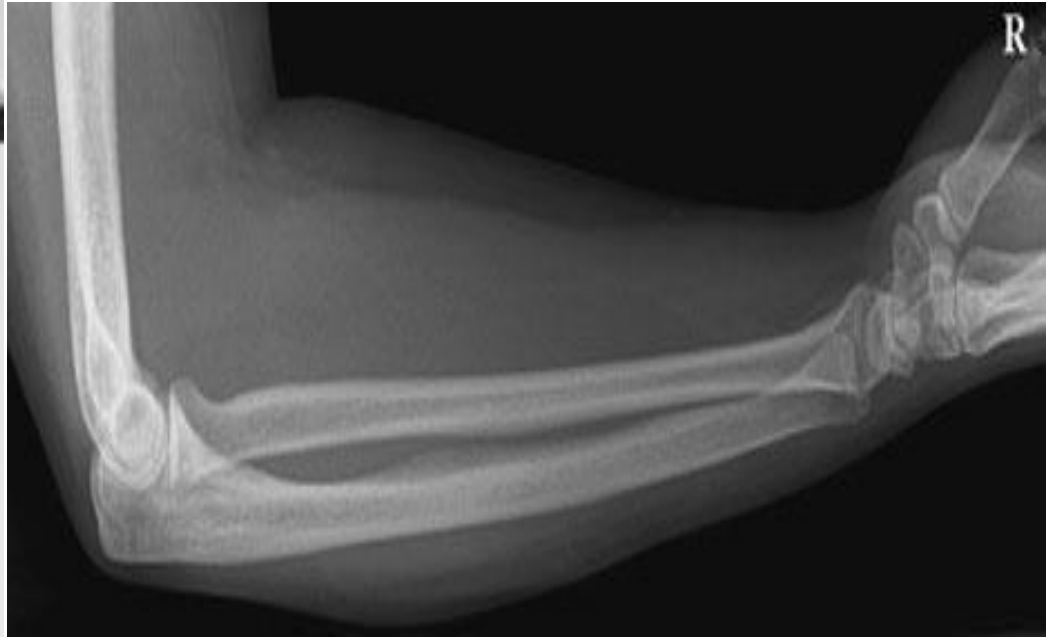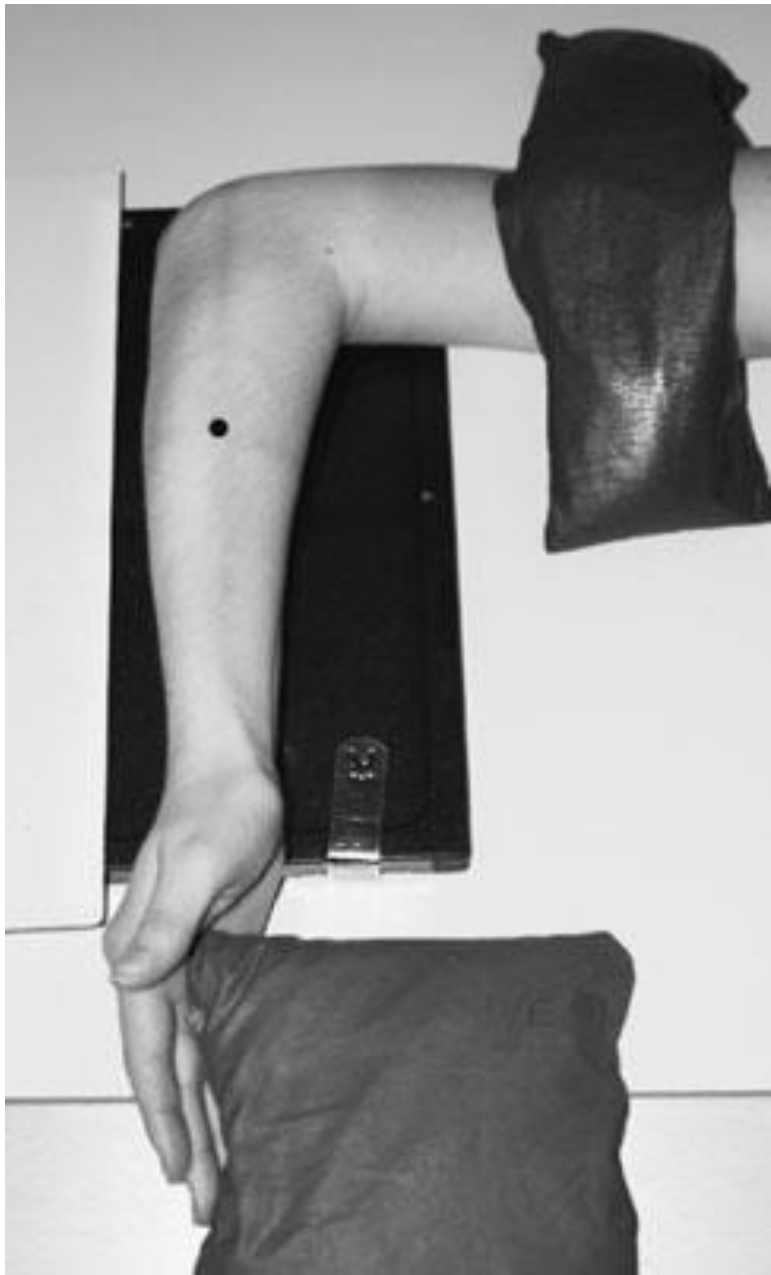
Lateral – basic

Direction and centring of the X-ray beam

- The vertical central ray is centred in the midline of the forearm to a point midway between the wrist and elbow joints.

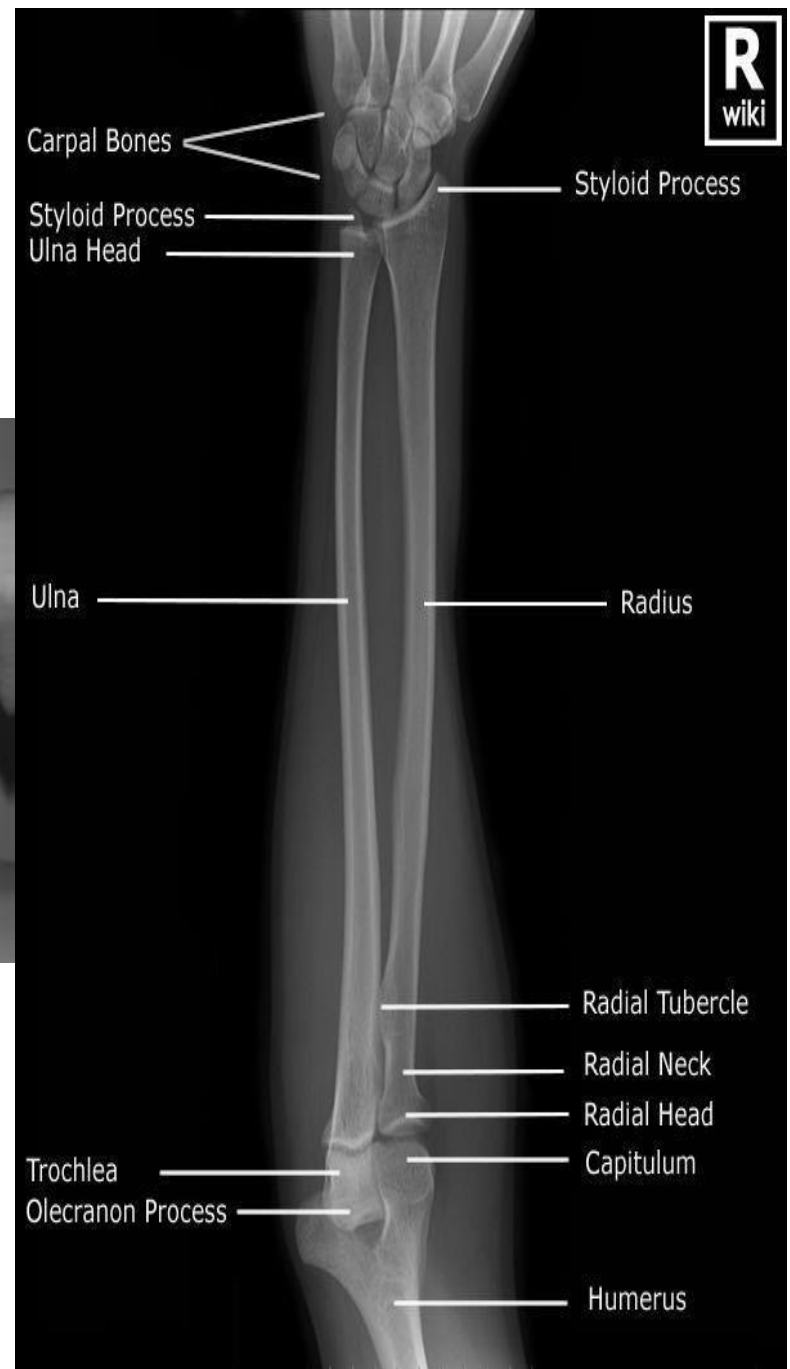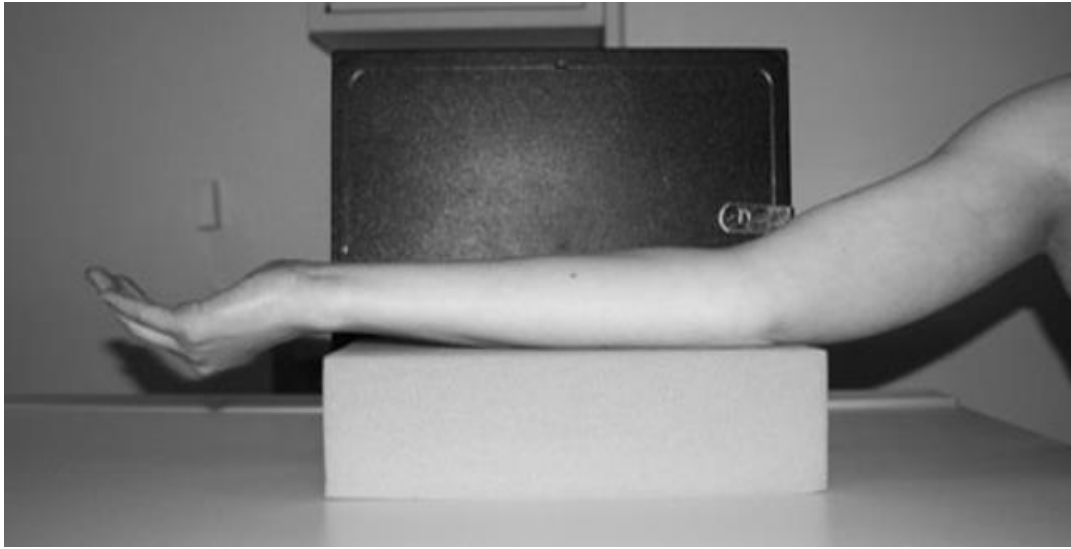Essential image characteristics

- Both the elbow and the wrist joint must be demonstrated on the image.
- Both joints should be seen in the true lateral position, with the radial and ulnar styloid processes and the epicondyles of the humerus superimposed



Important notes

- In trauma cases, it may be impossible to move the arm into the positions described, and a modified technique may need to be employed to ensure that two projections at right-angles to each other are obtained.
- If the limb cannot be moved through 90 degrees, then a horizontal beam should be used
- Both joints should be included on each image.
- No attempt should be made to rotate the patient's hand.



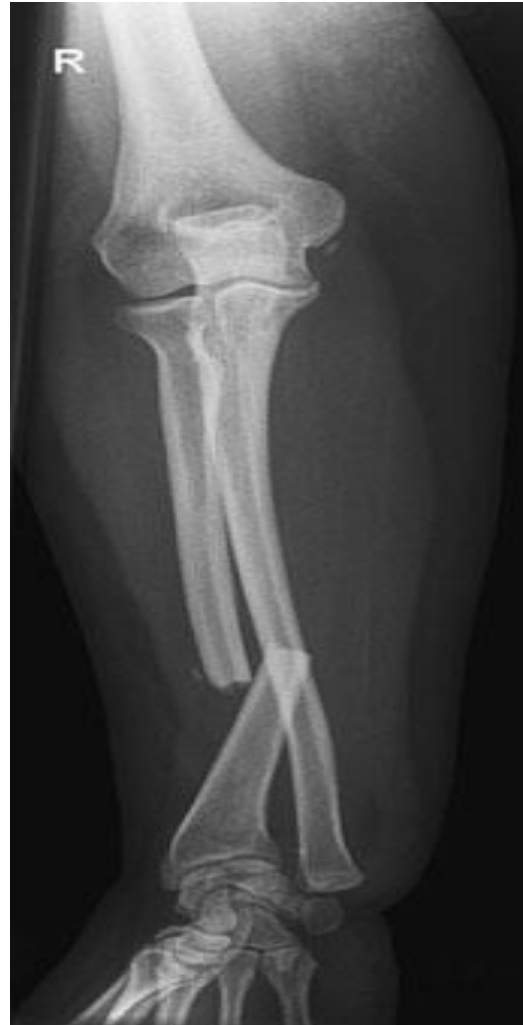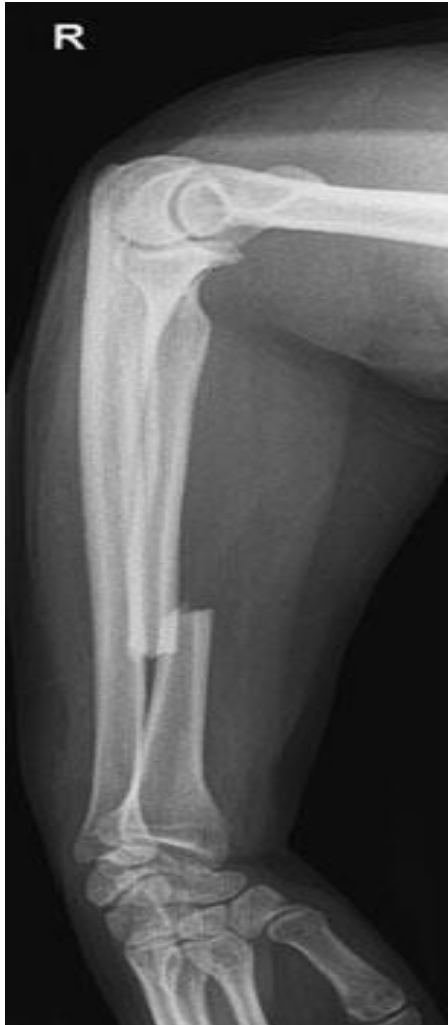Radiological considerations

When two or more bones such as the **radius** and **ulna** form a ring, **fracture** of one of the bones is often associated with **fracture** or **dislocation** elsewhere in the ring, especially if the fracture is displaced or the bone ends overlap.

In Galeazzi fracture there is a fracture of the radius with dislocation of the distal ulna, while in Monteggia fracture there is fracture of the ulna with dislocation of the head of the radius.

In forearm fracture, therefore, both ends of both bones, as well as the proximal and distal radio-ulnar joints, must be demonstrated

Galeazzi fracture



Lateral projection and
Antero-posterior
projection Radiographs of the
forearm
showing Galeazzi fracture

Bone fracture

A bone fracture is a full or partial break in the continuity of bone tissue.

Fractures can occur in any bone in the body.

There are several different ways in which a bone can fracture.

Types of fractures

1 Displaced Fracture:

bone breaks into two or more pieces and moves out of alignment.

2 Non-Displaced Fracture:

the bone breaks but does not move out of alignment (e.g, greenstick fracture)

3 Closed Fracture:

the skin is not broken.

Types of fractures

4 Open Fracture:

the bone has broken through the skin (compound or complex) – this is a medical emergency.

5 Avulsion Fracture:

when a fragment of bone is pulled away by ligament or tendon which its attachment.

6 Impacted Fracture:

ends are driven into each other; commonly seen in arm fractures in children.

Types of fractures

7-Comminuted Fracture:

the bone breaks into several pieces.

8-Compression or Wedge Fracture:

usually involves the bones in the back (vertebrae).

9-Greenstick Fracture:

an incomplete fracture in which the bone is bent;
occurs most often in children

Types of fractures

10-Linear Fracture:

the break is parallel to the bone's long axis.

11-Oblique Fracture:

the break has a curved or sloped pattern.

12-Pathologic Fracture:

caused by a disease that weakens the bones.

13-Spiral Fracture:

one part of the bone has been twisted at the break point.

Types of fractures

14-Stress Fracture: a hairline crack

15-Transverse Fracture:

the broken piece of bone is at a right angle to the bone's axis.

16-Epiphyseal Fracture:

a fracture through the epiphysis.

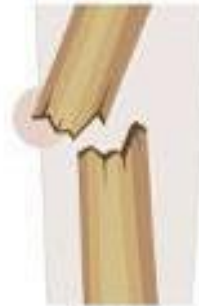17-Depressed Fracture:

a fracture in which fragments are driven inward (skull and facial fracture)

18-Segmental Fracture:

The same bone is fractured in two places, segment of bone between the two breaks

TYPES OF BONE FRACTURES



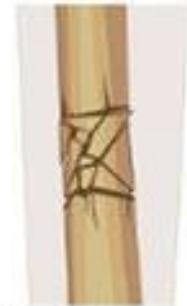Open



Transverse



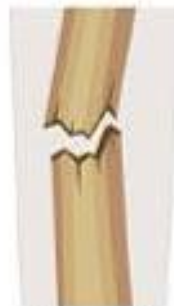Greenstick



Comminuted



Sigmental



Closed



Spiral



Linear



Impacted

Thank
you!





Radiology Techniques Department

Radiographic imaging

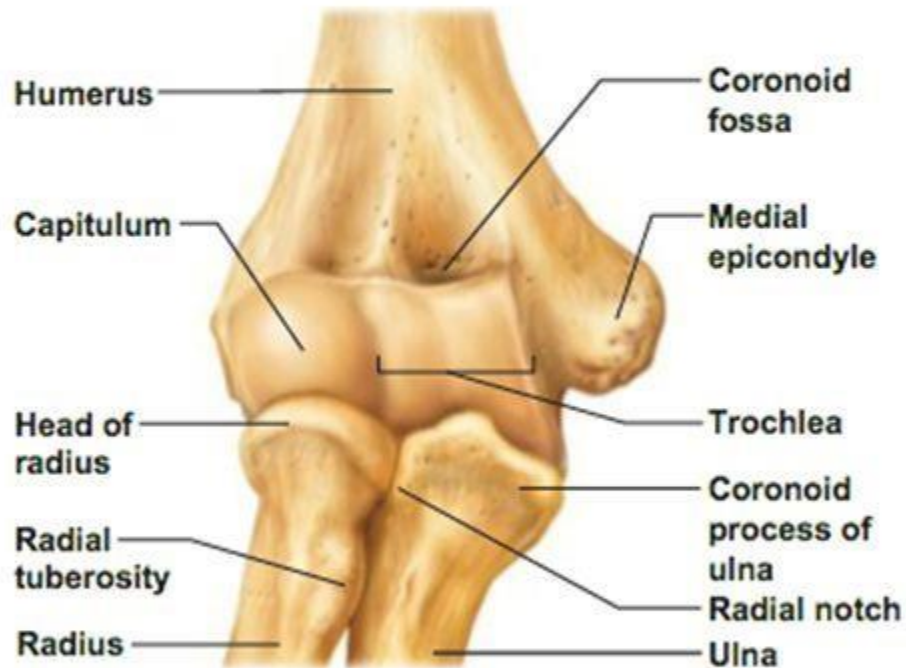Radiographic position of elbow joint

Lecture 9

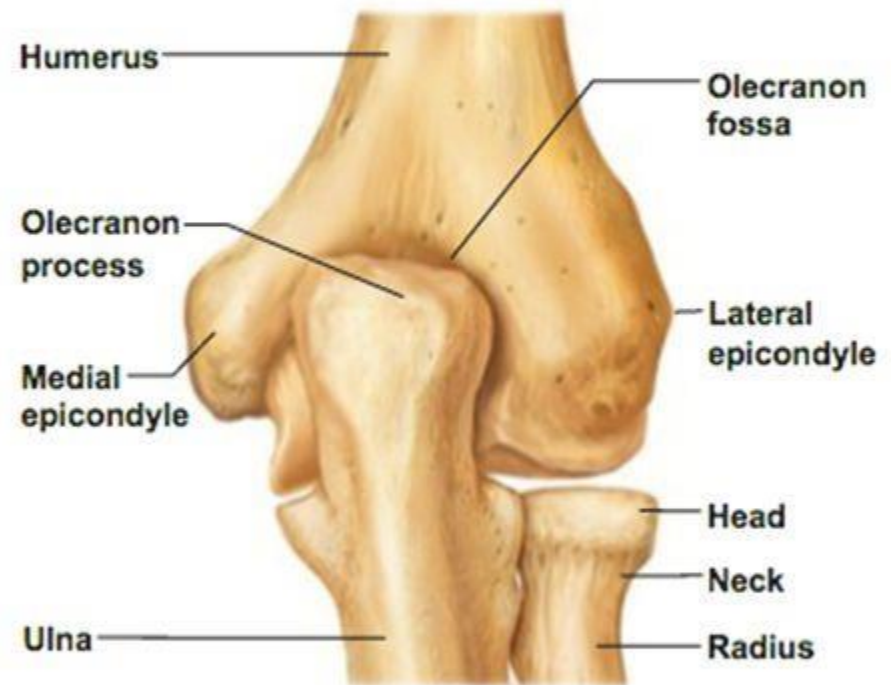د. حيدر سعيد شندل

M.B.CH.B MSc. RAD. (ASU)

ELBOW

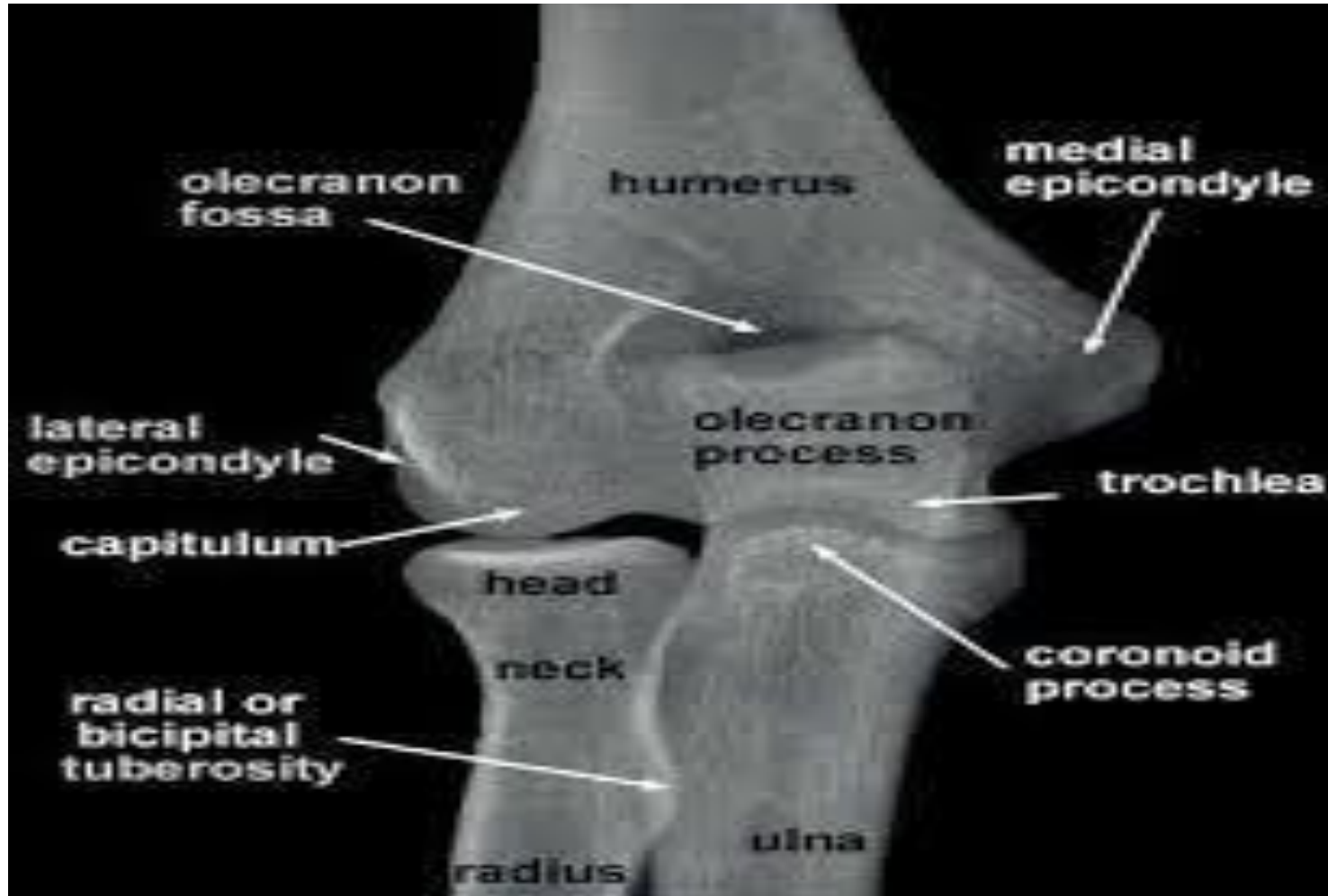


(c) Anterior view at the elbow region



(d) Posterior view of extended elbow

Elbow



Basic Projection of Elbow Joint

- Antero-posterior
- Lateral
- Oblique

Antero posterior

Position of patient and cassette

- The arm is extended fully, such that the posterior aspect of the entire limb is in contact with the tabletop and the palm of the hand is facing upwards.
- cassette is positioned under the elbow joint, with its short axis parallel to the forearm.
- The arm is adjusted such that the medial and lateral epicondyles are equidistant from the cassette.
- Film size 8x10 lengthwise ,cassette is placed out Bucky.

Antero posterior

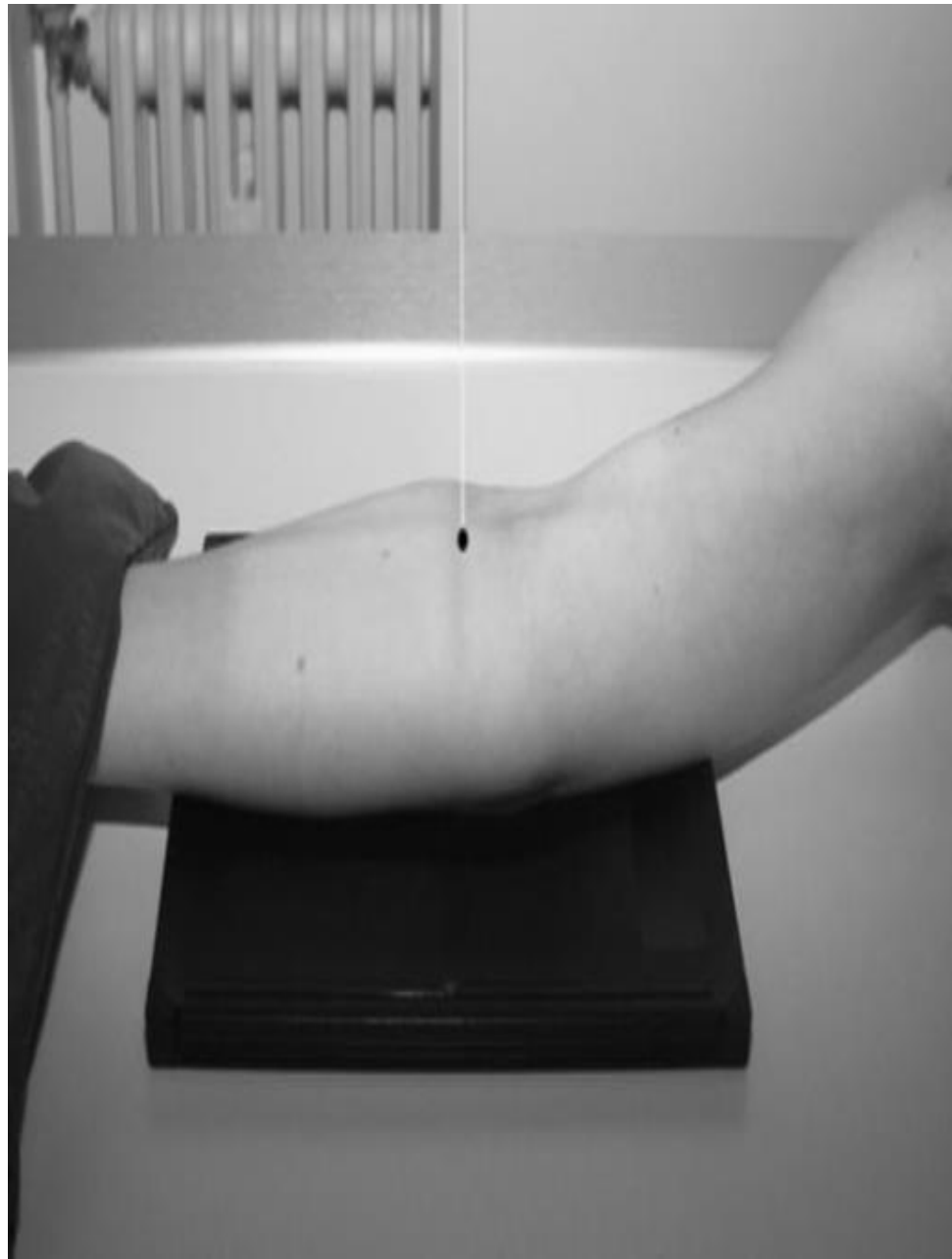
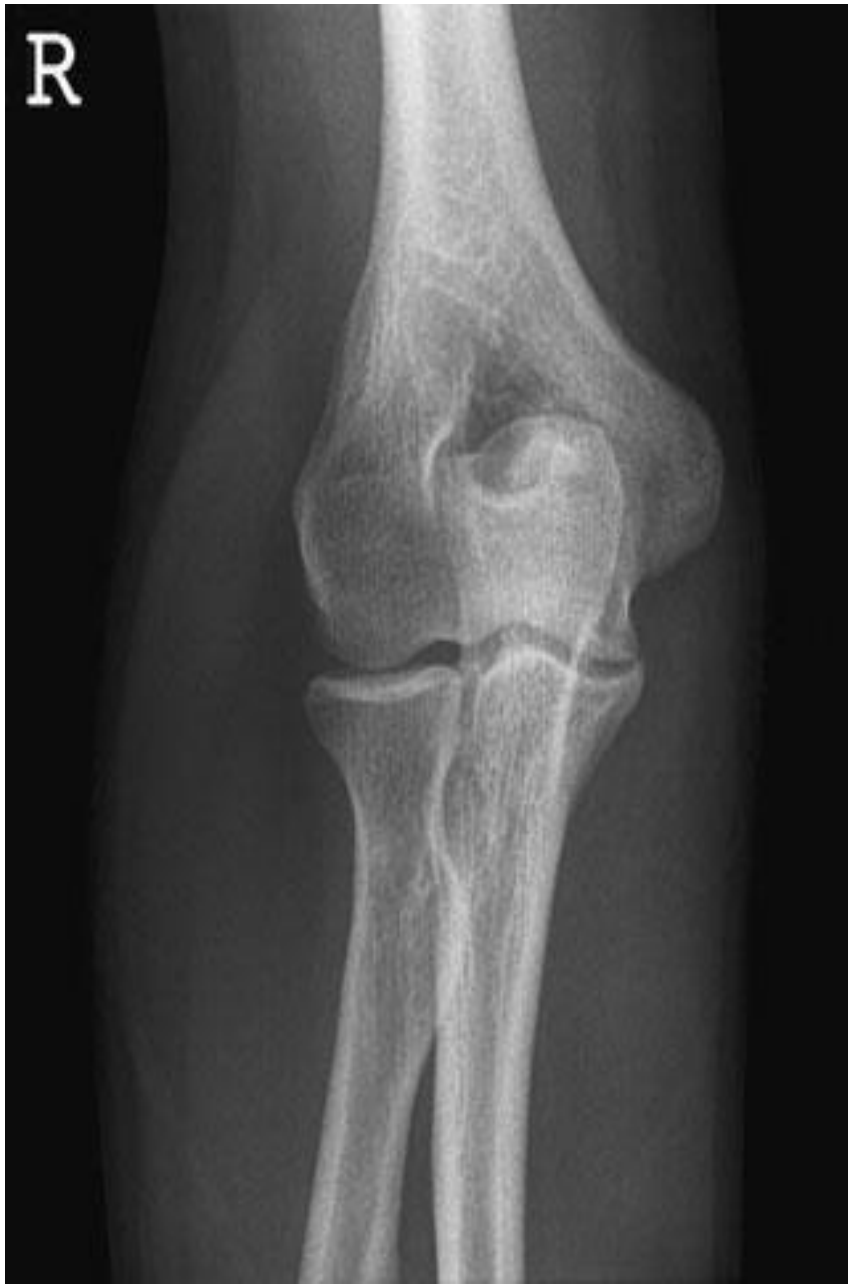Direction and centring of the X-ray beam

- The vertical central ray is centered through the joint space 2.5 cm distal to the point midway between the medial and lateral epicondyles of the humerus.

Antero posterior

Essential image characteristics

- The central ray must pass through the joint space at 90 degrees to the humerus to provide a satisfactory view of the joint space.
- The image should demonstrate the distal third of humerus and the proximal third of the radius and ulna



1-Antero-posterior – forearm in contact

- Position of patient and cassette
- The posterior aspect of the forearm is placed on the table, with the palm of the hand facing upwards.
- The cassette is placed under the forearm, with its center under the elbow joint.
- The arm is adjusted such that the medial and lateral epicondyles of the humerus are equidistant from the cassette.
- The limb is supported and immobilized in this position.

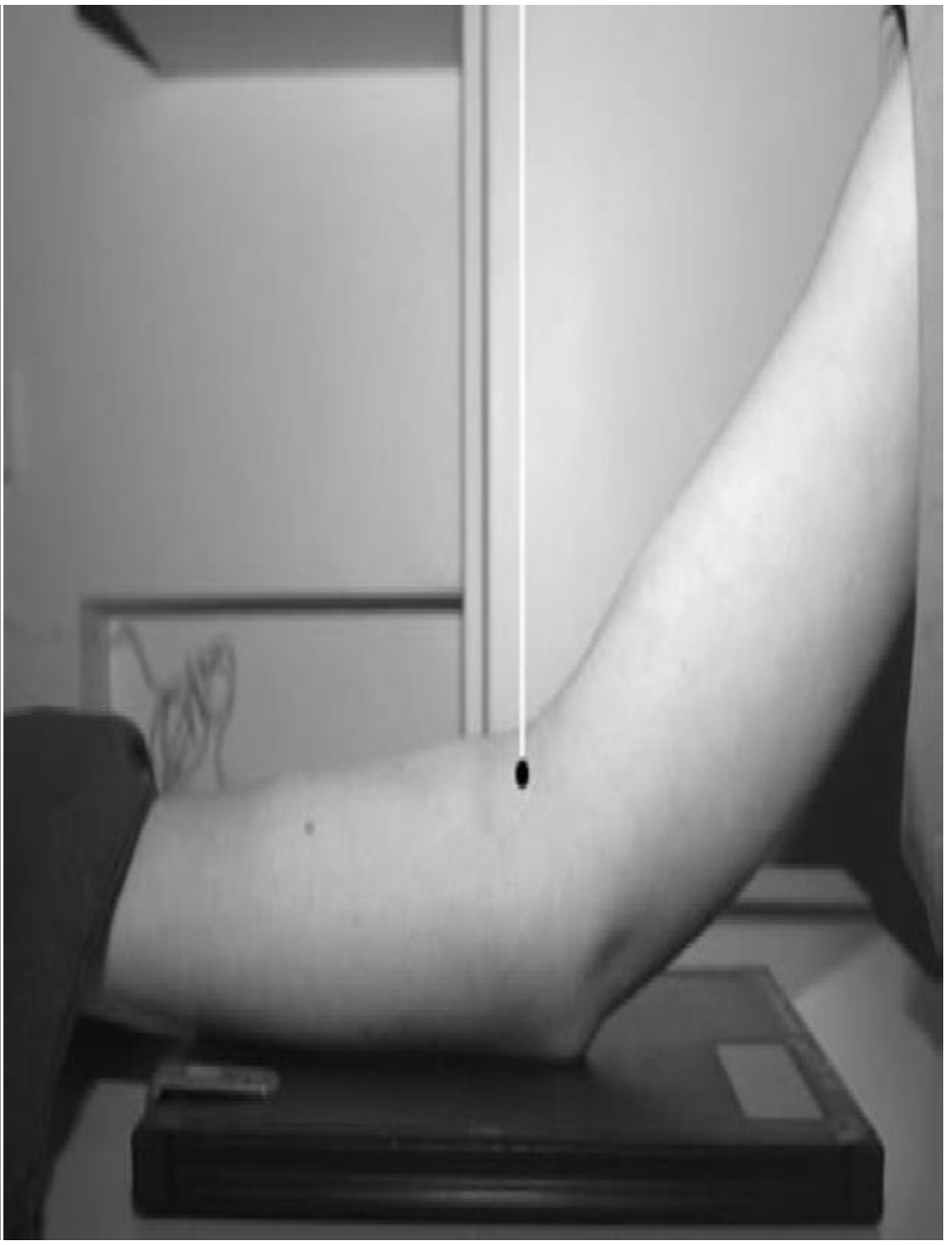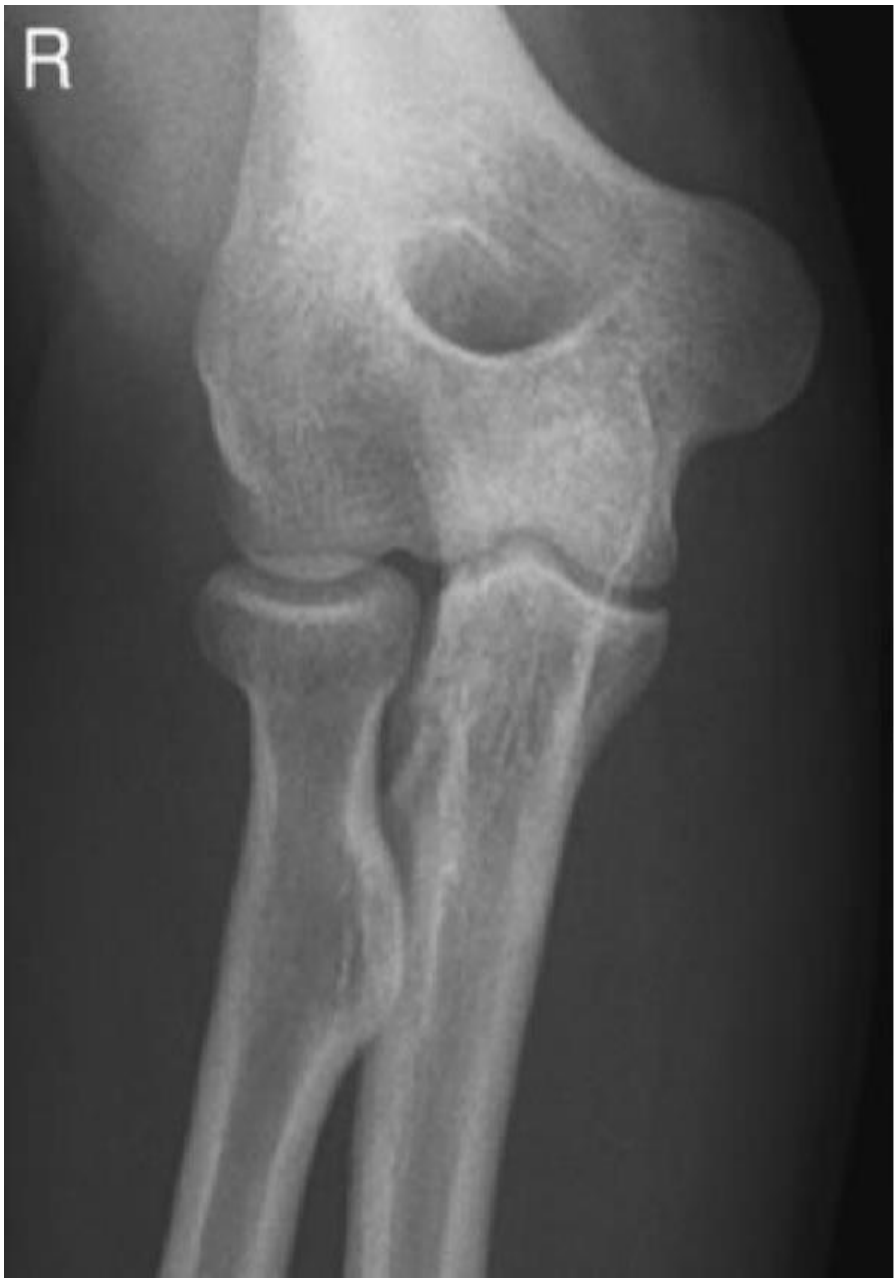Antero-posterior – partial flexion

Direction and centering of the X-ray beam

- The vertical central ray is centred in the midline of the forearm 2.5 cm distal to the crease of the elbow

Essential image characteristics

- The image should demonstrate the distal third of humerus and the proximal third of the radius and ulna



2-Antero-posterior – upper arm in contact

Position of patient and cassette.

- The posterior aspect of the humerus is placed on the table, with the palm of the hand facing upwards.
- The cassette is placed under the forearm, with its center under the elbow joint.
- The arm is adjusted such that the medial and lateral epicondyles of the humerus are equidistant from the film
- The limb is supported and immobilized in this position.

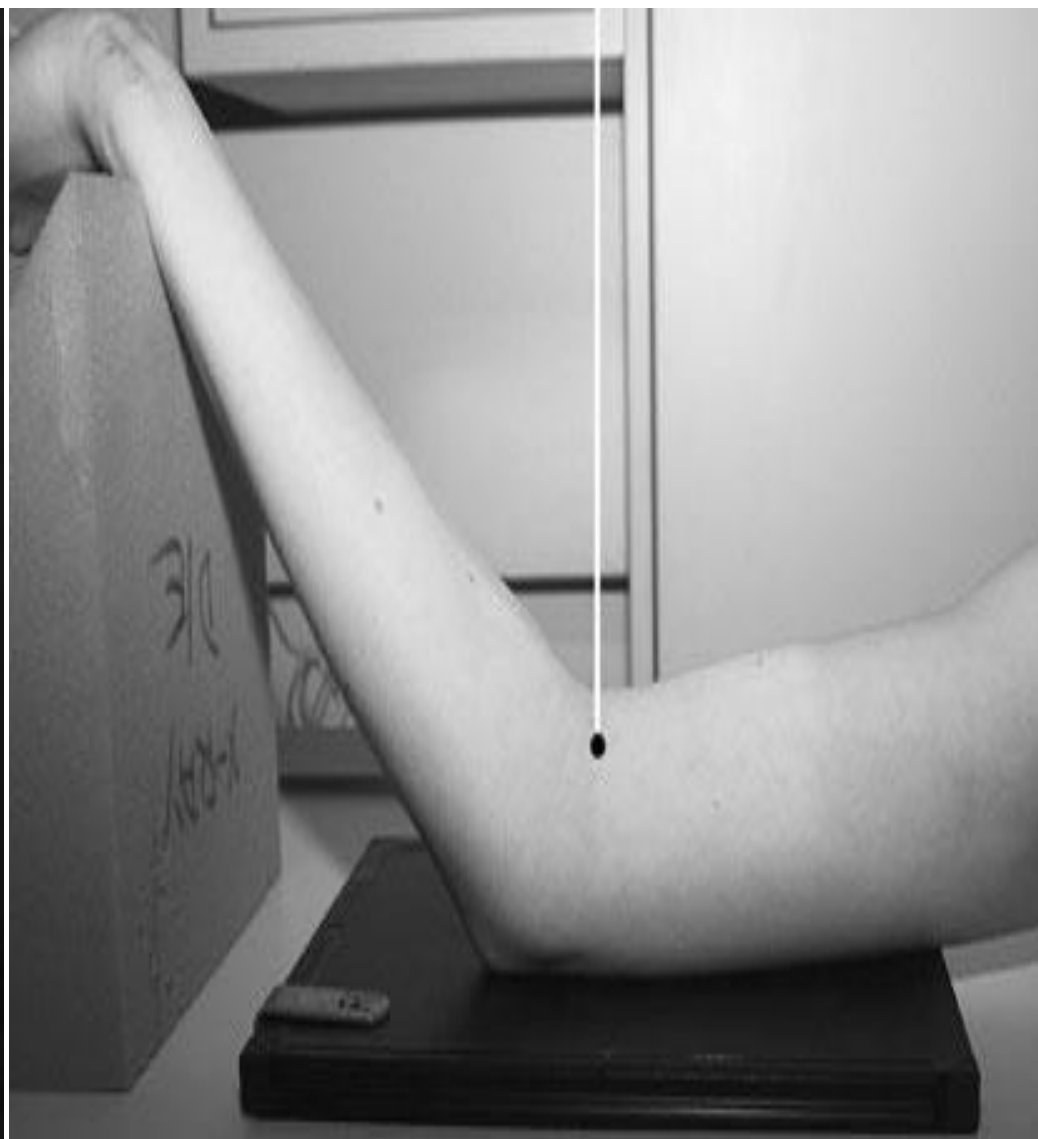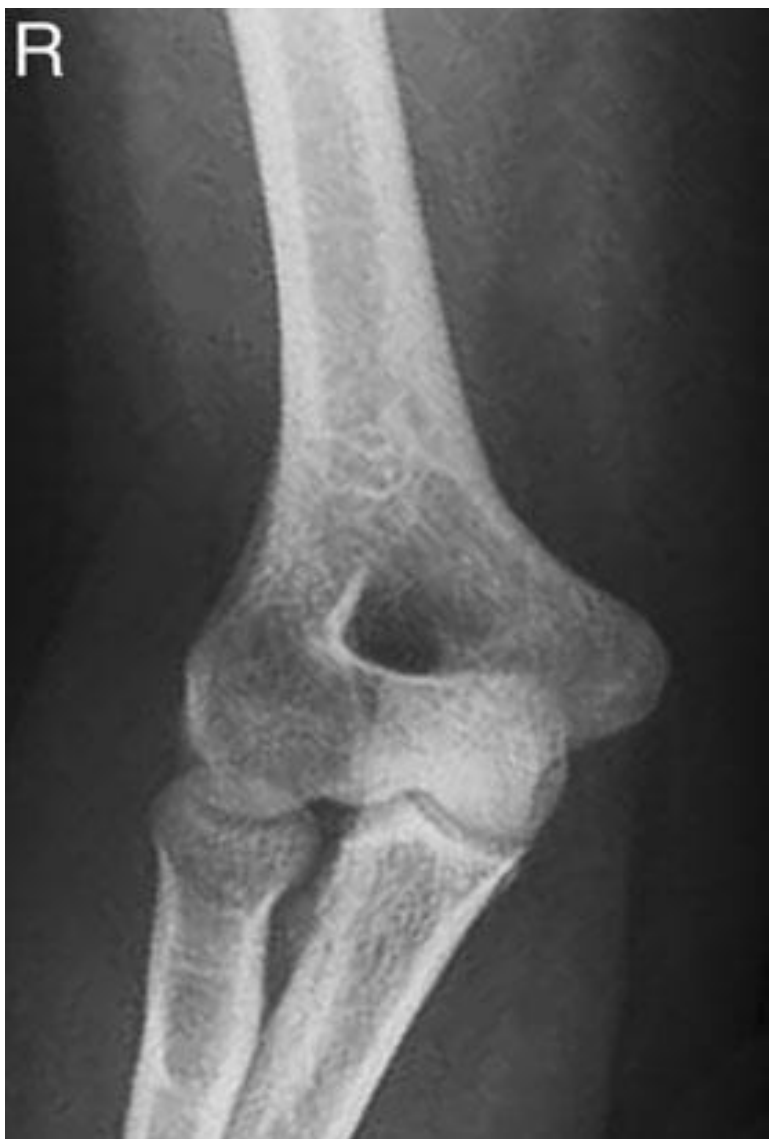2-Antero-posterior – upper arm in contact

Direction and centring of the X-ray beam

- The vertical central ray is centred midway between the epicondyles of the humerus.

Essential image characteristics

- The image should demonstrate the distal third of humerus and the proximal third of the radius and ulna



Elbow Full flexion

1 Axial – upper arm in contact

Position of patient and cassette

- The elbow is fully flexed, and the palm of the hand is facing the shoulder
- The posterior aspect of the upper arm is placed on the cassette, with the arm parallel to the long axis of the cassette.
- The patient's trunk is adjusted in order to bring the medial and lateral epicondyles of the humerus equidistant to the cassette

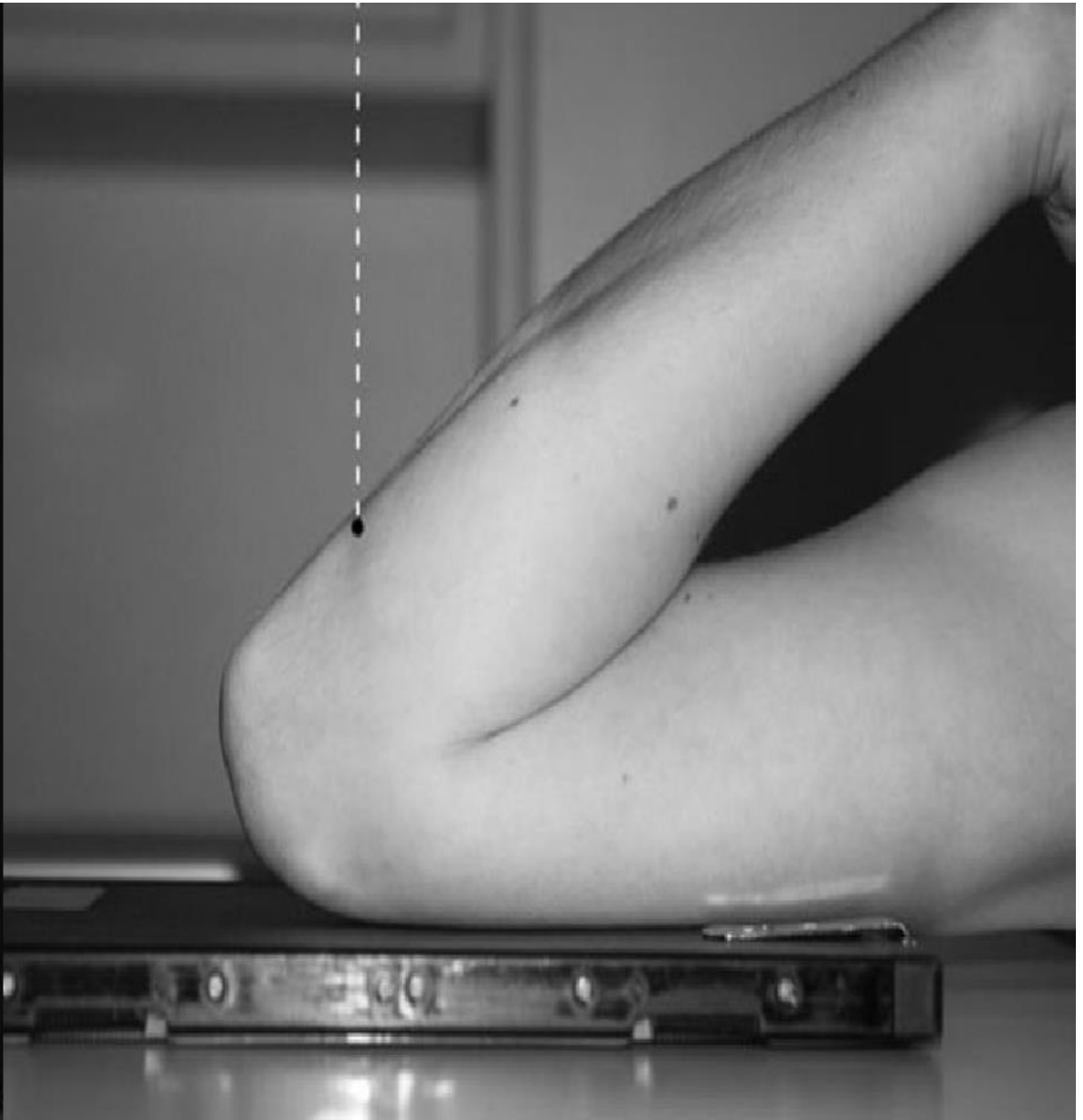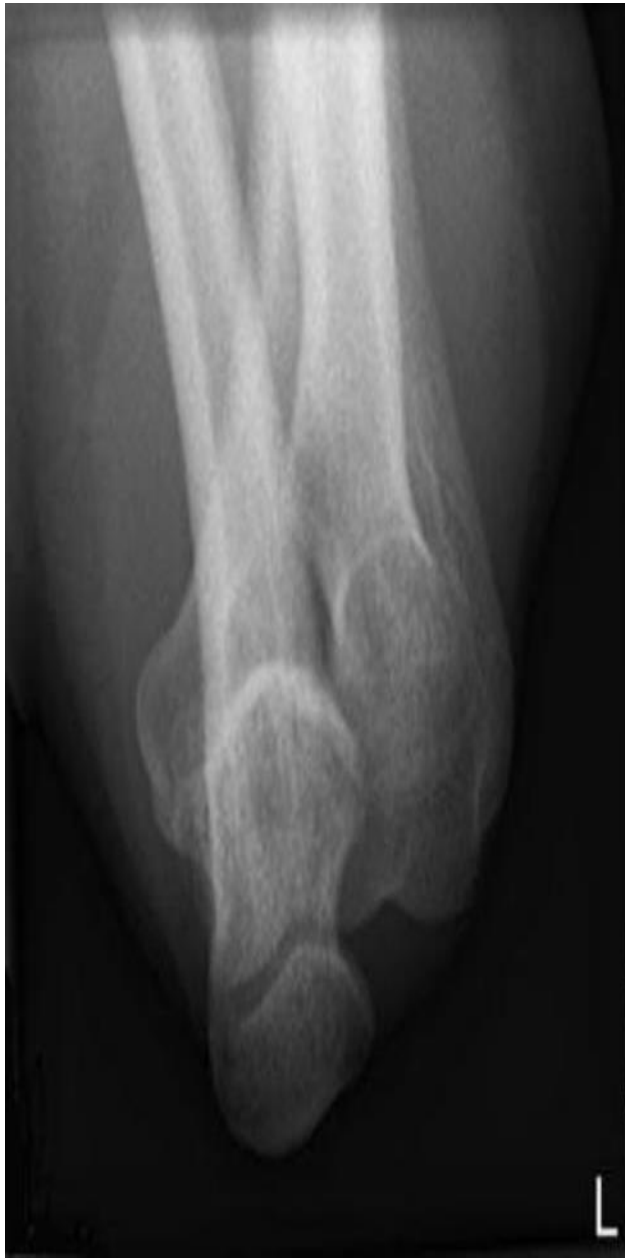1-Axial – upper arm in contact

Direction and centering of the X-ray beam

- For the lower end of the humerus and the olecranon process of ulna, the vertical central ray is centred 5 cm distal to the olecranon process.
- For the proximal ends of the radius and ulna, including the radio-humeral joint, the central ray is directed at right-angles to the forearm and centred 5 cm distal to the olecranon process.

Essential image characteristics

- The image will include the olecranon process and the lower third of the radius and ulna superimposed on the lower third of the humerus.
- The exposure should be adequate to visualize all three bones



2-Axial – forearm in contact

- 2-Axial – forearm in contact

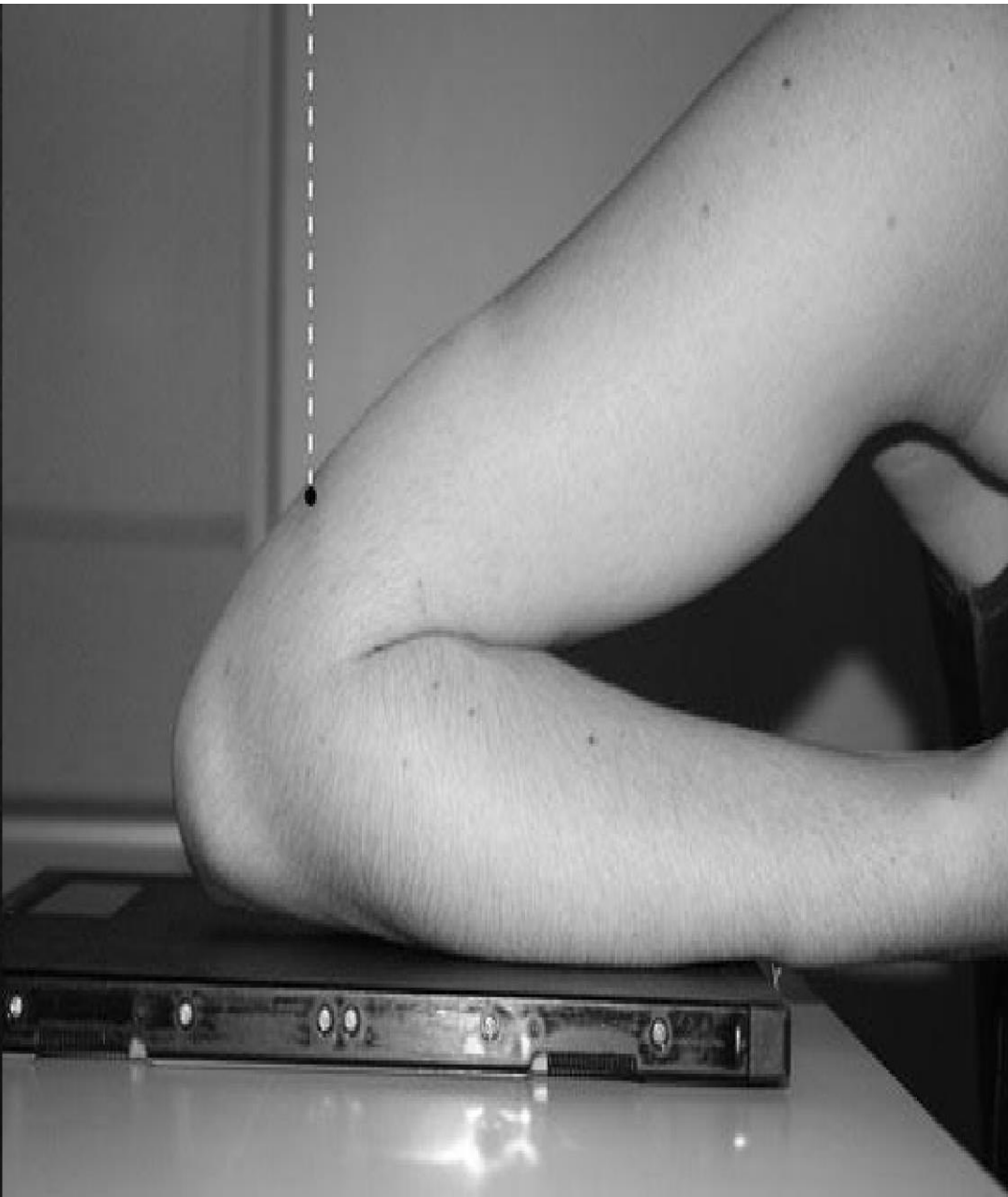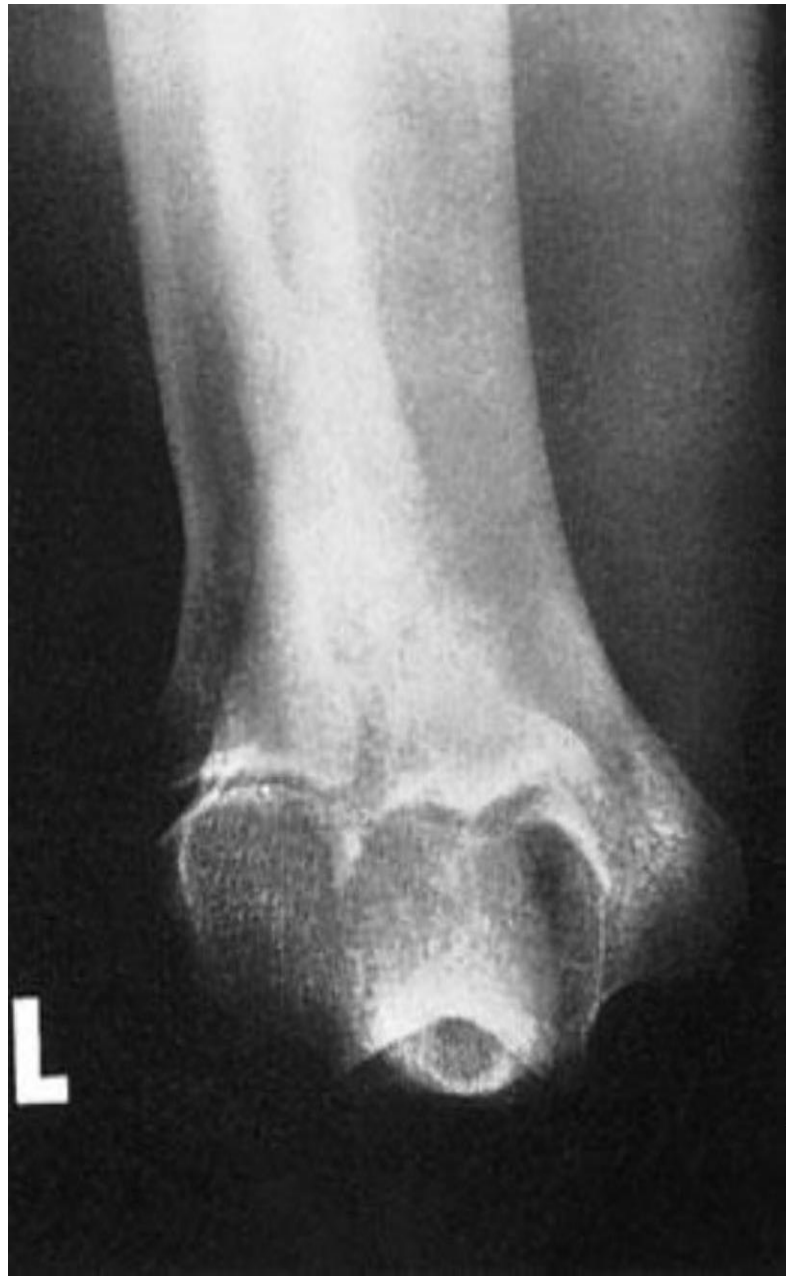Position of patient and cassette

- The elbow is fully flexed and the palm of the hand is facing upwards.
- The forearm is fully supinated, with the posterior aspect of the forearm resting on the cassette and the arm parallel to the long axis of the cassette
- The patient's trunk is adjusted in order to bring the medial and lateral epicondyles of the humerus equidistant to the cassette

2-Axial – forearm in contact

Direction and centering of the X-ray beam

- For the proximal ends of the radius and ulna and the radio-humeral joint, the vertical central ray is directed to a point on the posterior aspect of the upper arm 5 cm proximal to the olecranon process.
- For the lower end of the humerus and the olecranon process of the ulna, the central ray is directed at right-angles to the upper arm centred to a point 5 cm proximal to the olecranon process.



Lateral head of radius

- The elbow is positioned as for the lateral elbow.
- The hand is then moved through different degrees of rotation, enabling visualization of small fissure fractures through the head of the radius.

Lateral head of radius

Position of patient and cassette

- **For the first projection**, the patient is positioned as for a lateral elbow projection, with the palm of the hand vertical. The forearm is immobilized using a sandbag.
- **For the second exposure**, the upper arm and elbow are maintained in the same position, whilst the hand is rotated medially until the palm of the hand rests on the table. The forearm is immobilized using a sandbag.
- **For the third exposure**, the upper arm and elbow are maintained in the same position, whilst the hand is rotated further medially, until the palm of the hand is vertical, facing away from the body. The forearm is immobilized using a sandbag

Lateral head of radius

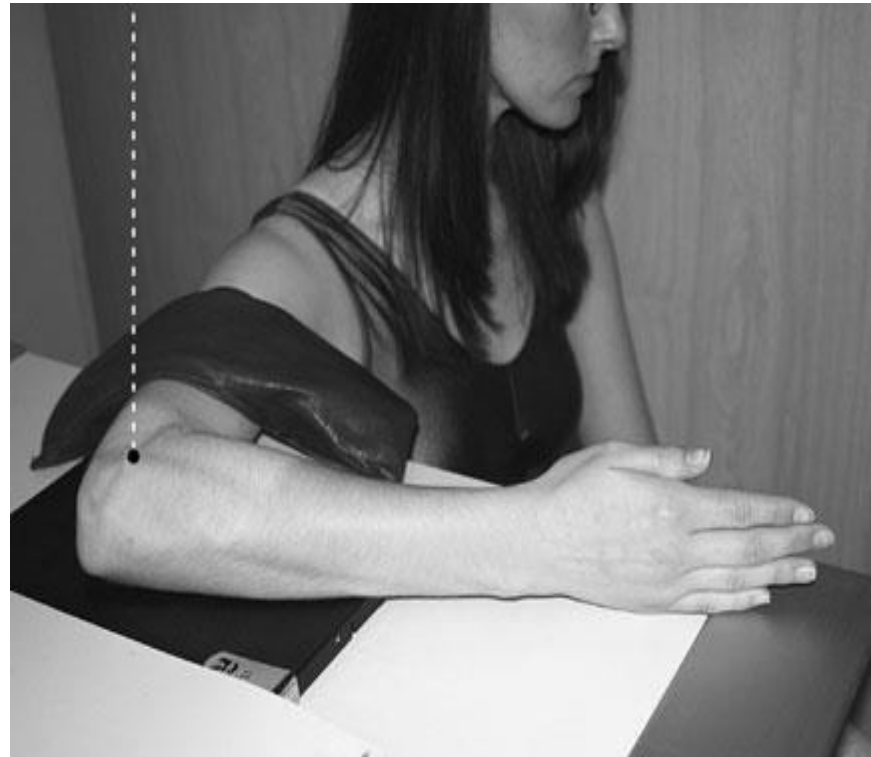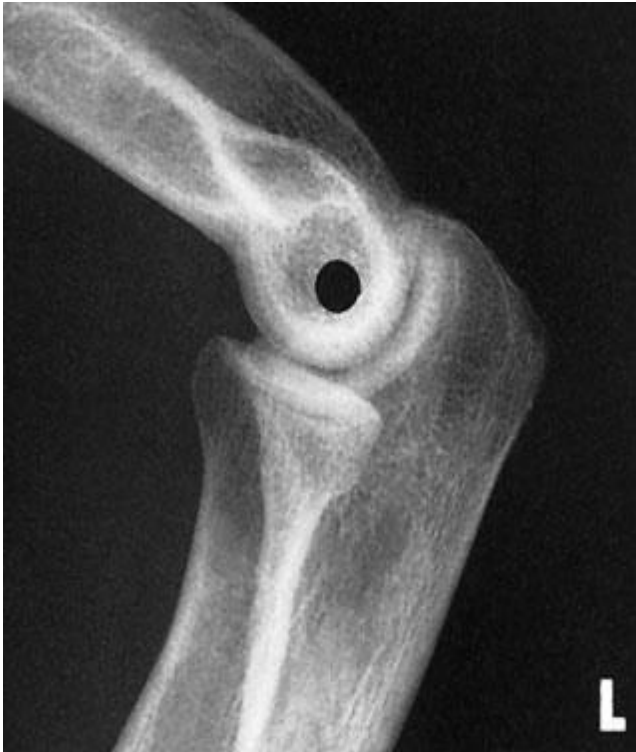Direction and centering of the X-ray beam

- In each case, the vertical central ray is centred to the lateral epicondyle of the humerus.

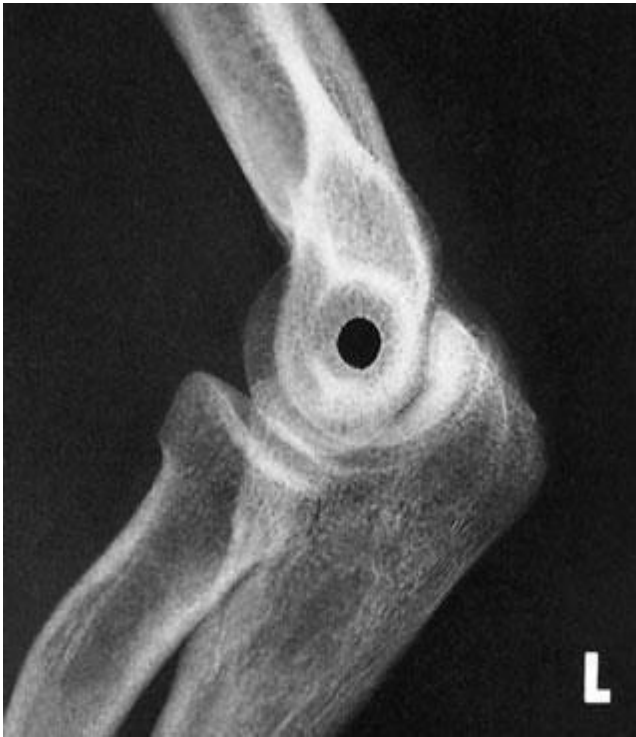Essential image characteristics

- The elbow joint should be seen in the true lateral position in each projection.
- Sufficient detail of bony trabeculae should be demonstrated to enable fine fractures to be detected.

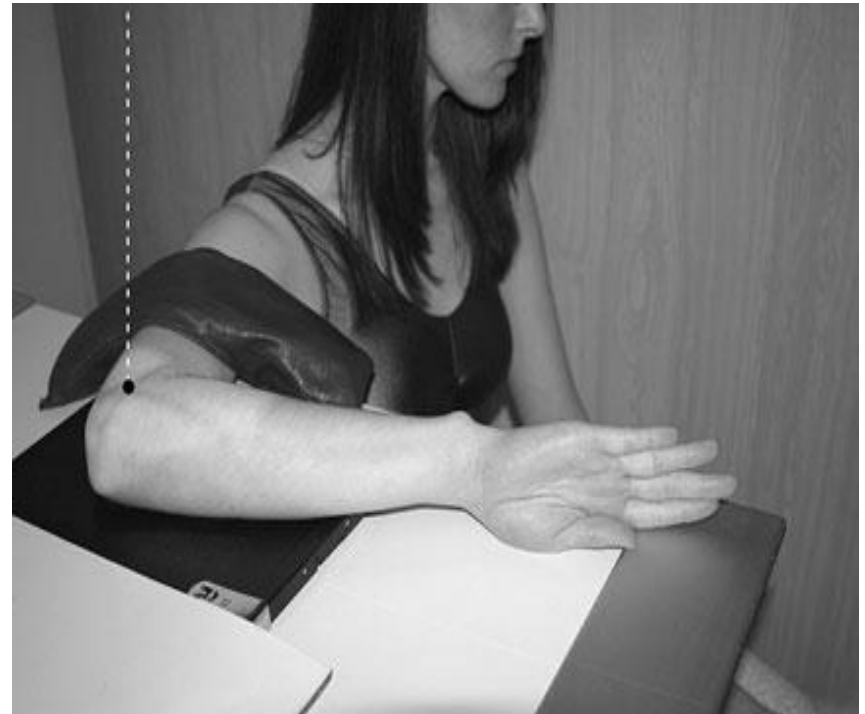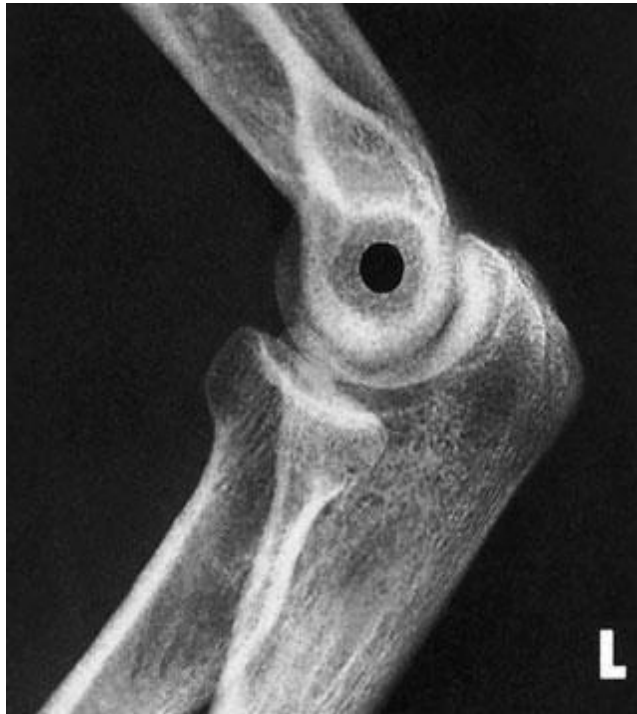1-Lateral radiograph of elbow for head of radius –
palm at right angles to the table



2-Lateral radiograph of elbow for head of radius –
palm in contact with the table



3-Lateral radiograph of elbow for head of radius –
palm facing away from the trunk



Proximal radio-ulnar joint – oblique

Position of patient and cassette

- The patient is positioned for an anterior projection of the elbow joint.
- The cassette is positioned under the elbow joint, with the long axis of the cassette parallel to the forearm.
- The humerus is then rotated laterally (or the patient leans towards the side under examination) until the line between the epicondyles is approximately 20 degrees to the cassette.
- The forearm is immobilized using a sandbag.

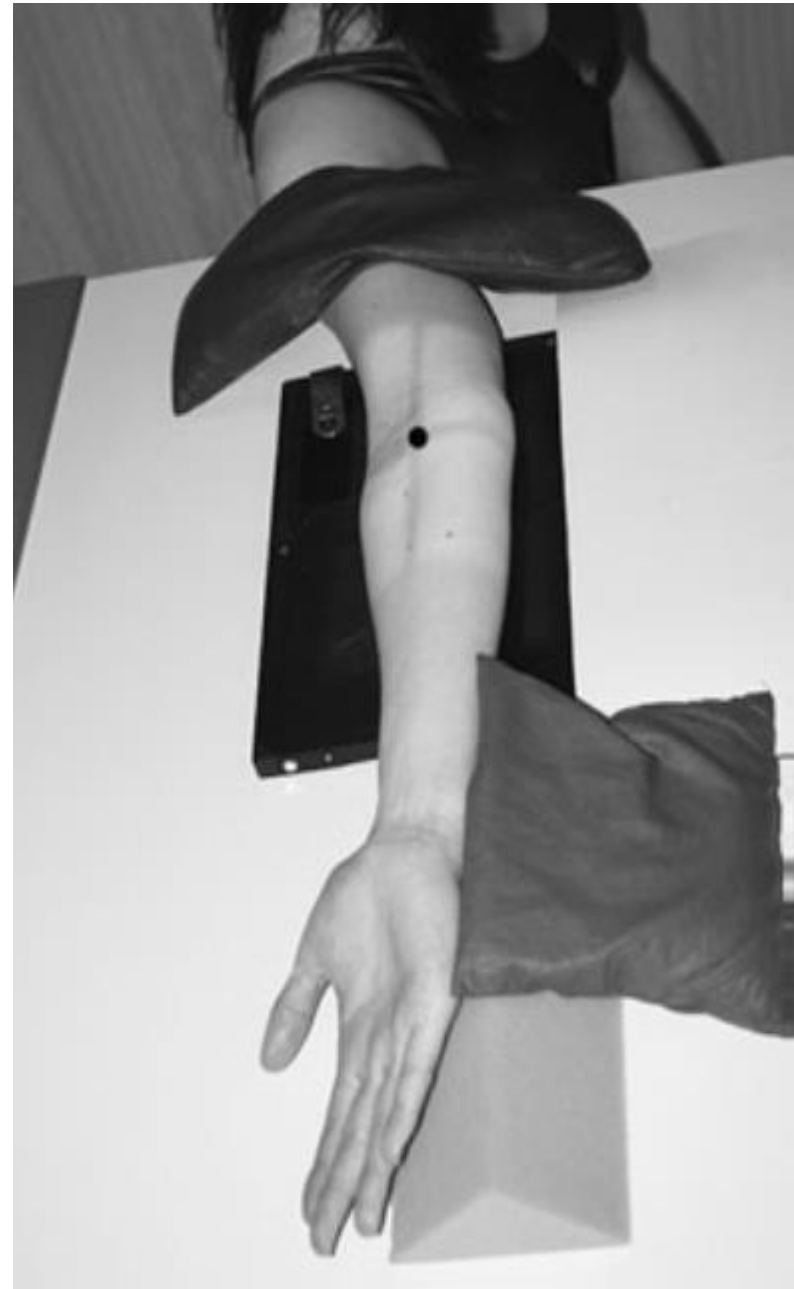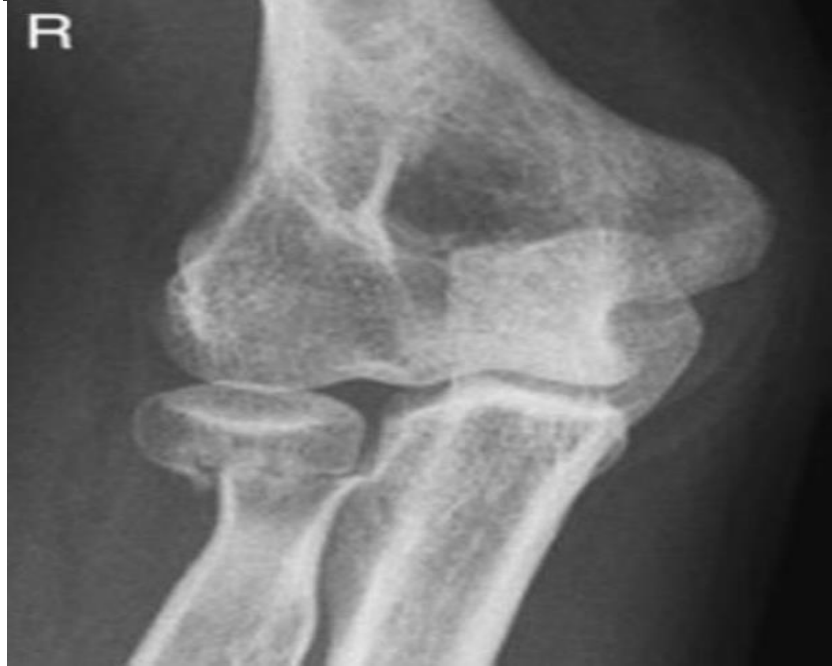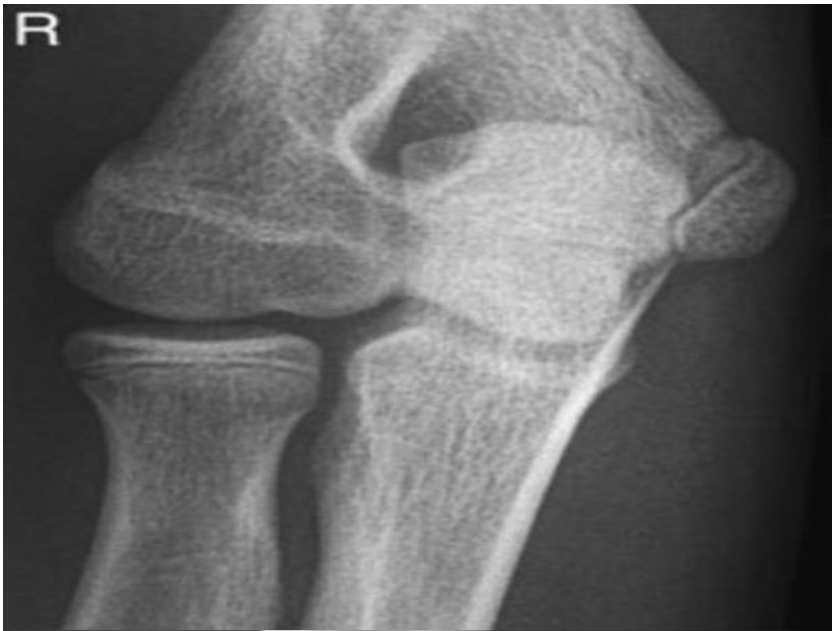Proximal radio-ulnar joint – oblique

Direction and centering of the X-ray beam

- The vertical central ray is centered 2.5 cm distal to the midpoint between the epicondyles.

Essential image characteristics

- The image should demonstrate clearly the joint space between the radius and the ulna.



Ulnar groove – axial

Ulnar groove – axial

The ulnar groove through which the ulnar nerve passes lies between the medial epicondyle and the medial lip of the trochlear of the humerus and is a possible site for ulnar nerve compression. A modified axial projection with the elbow joint fully flexed demonstrates the groove and any lateral shift of the ulna, which would lead to tightening of the ligaments overlying the ulnar nerve.

Ulnar groove – axial

- Position of patient and cassette
- The elbow is fully flexed, and the posterior aspect of the upper arm is placed in contact with the tabletop.
- The cassette is positioned under the lower end of the humerus, with its center midway between the epicondyles of the humerus.
- With the elbow still fully flexed, the arm is externally rotated through 45 degrees and

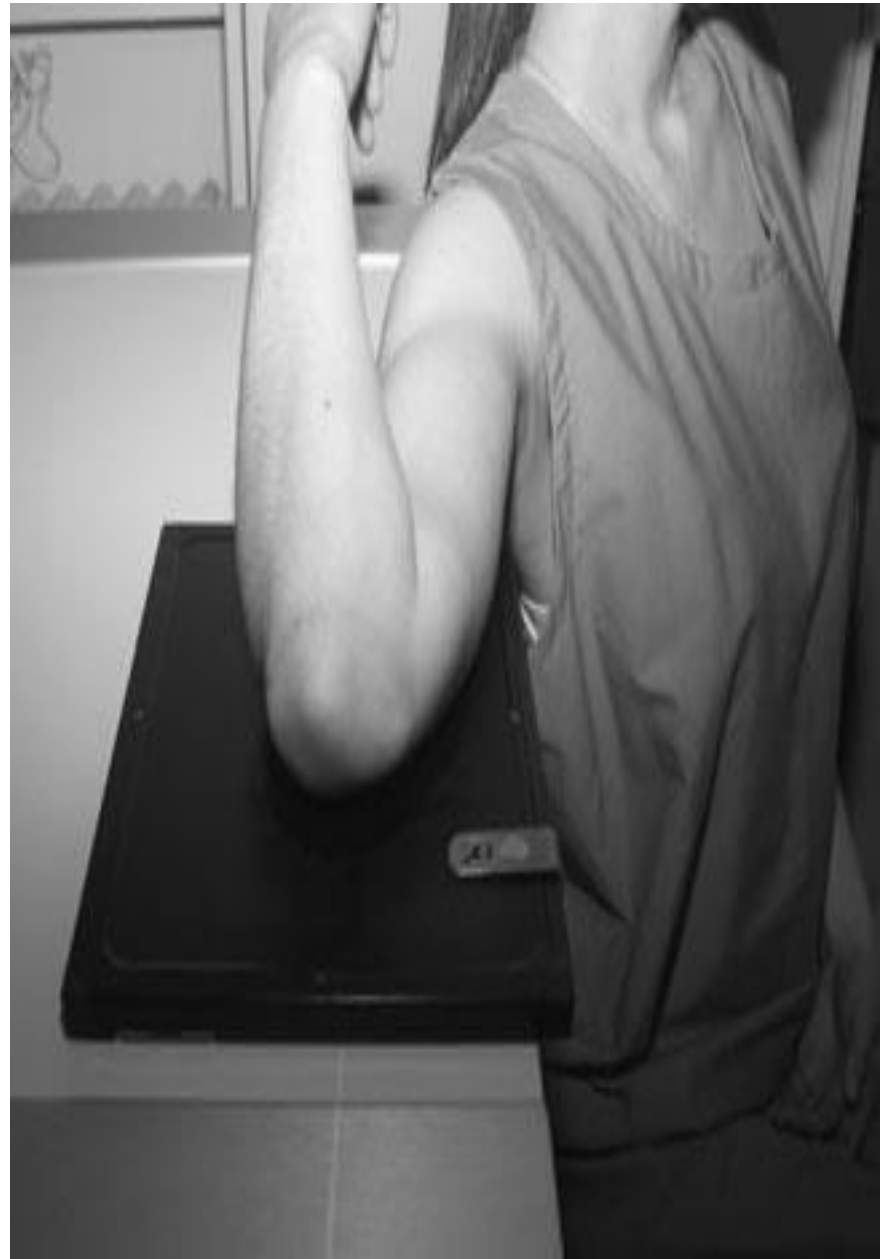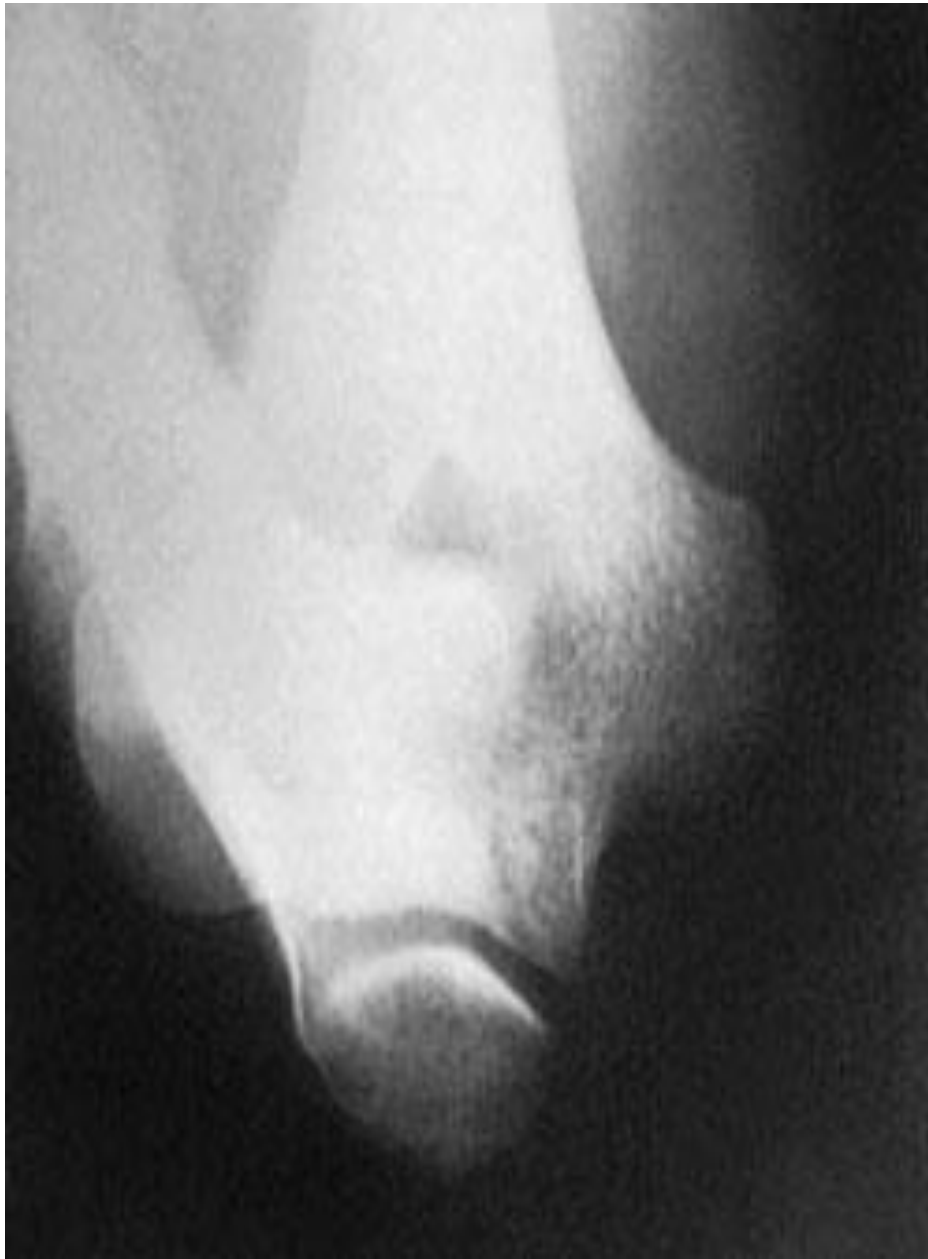Ulnar groove – axial

Direction and centering of the X-ray beam

- The vertical central ray is centred over the medial epicondyle of the humerus.

Essential image characteristics

- The exposure is chosen to demonstrate the ulnar groove in profile



Thank
you!





Radiology Techniques Department

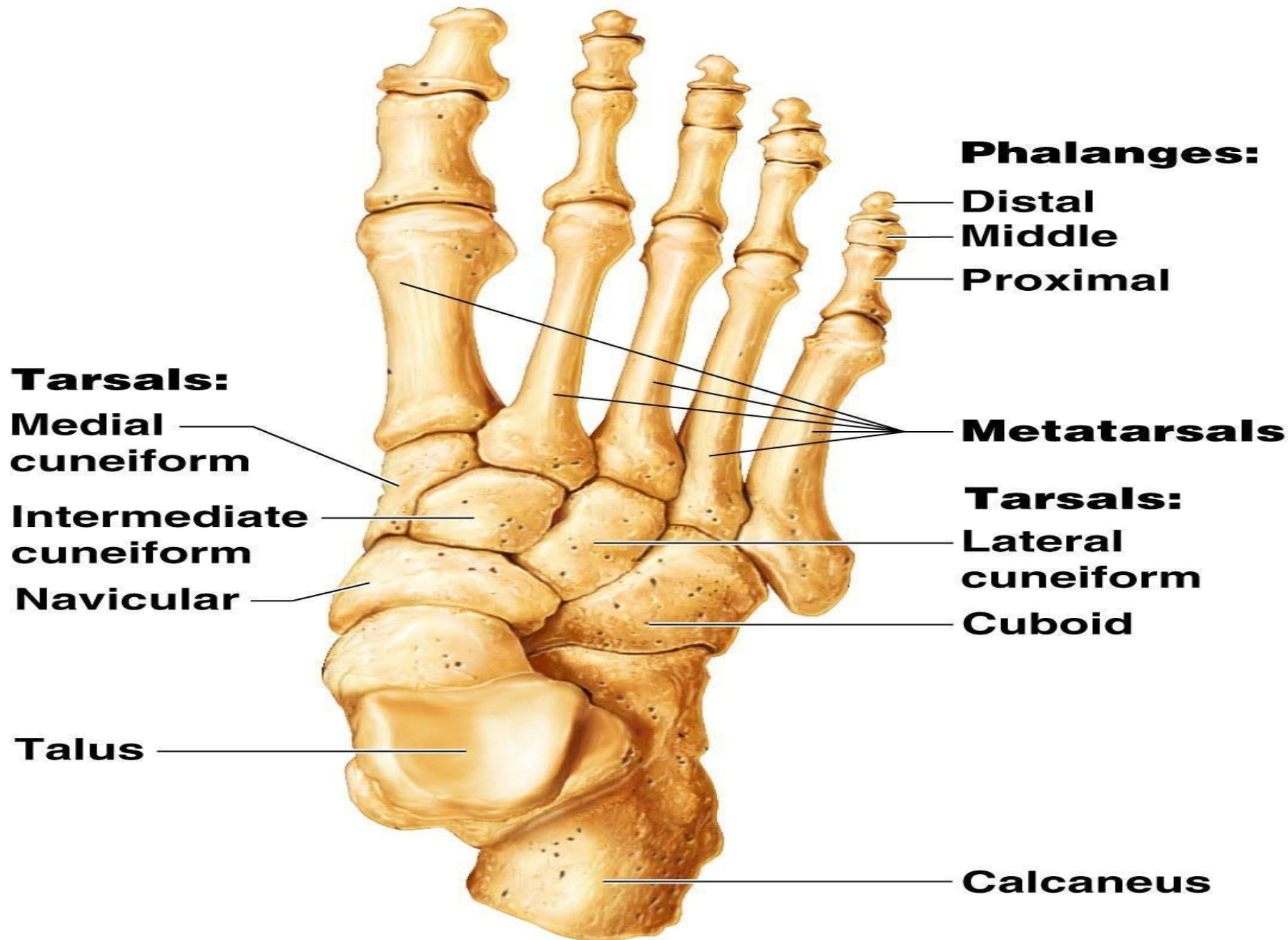
Radiographic imaging

Radiographic position of lower extremities , foot and toes

Lecture 10

د. حيدر سعيد شندل

M.B.CH.B MSc. RAD. (ASU)



Tarsals:
Medial cuneiform

Intermediate cuneiform
Navicular

Talus

Phalanges:
Distal
Middle
Proximal

Metatarsals

Tarsals:
Lateral cuneiform
Cuboid

Calcaneus

FOOT

Basic positions of foot

- 1 Anterio-posterior(AP)Position
- 2 Oblique Position
- 3 Lateral Position

Anterio-posterior(AP)Position

Position of patient and cassette

- The patient is seated on the X-ray table, supported if necessary, with the knee flexed.
- The plantar aspect of the affected foot is placed on the cassette.
- The cassette out bucky
- Use sandbags of necessary to prevent cassette from slipping on tabletop
- size of cassette 24×30 cm(10×12 inch).

Anterio-posterior(AP)Position

Direction and centering of x-ray

The X-ray tube is angled 10° or 15 degrees cranially (toward heel), centered to base of third metatarsal

Note /

A high arch requires a greater angle (15 degree) and a low arch nearer 5 degree to be perpendicular to the metatarsals.

For foreign body, CR should be perpendicular to IR with no CR angle.

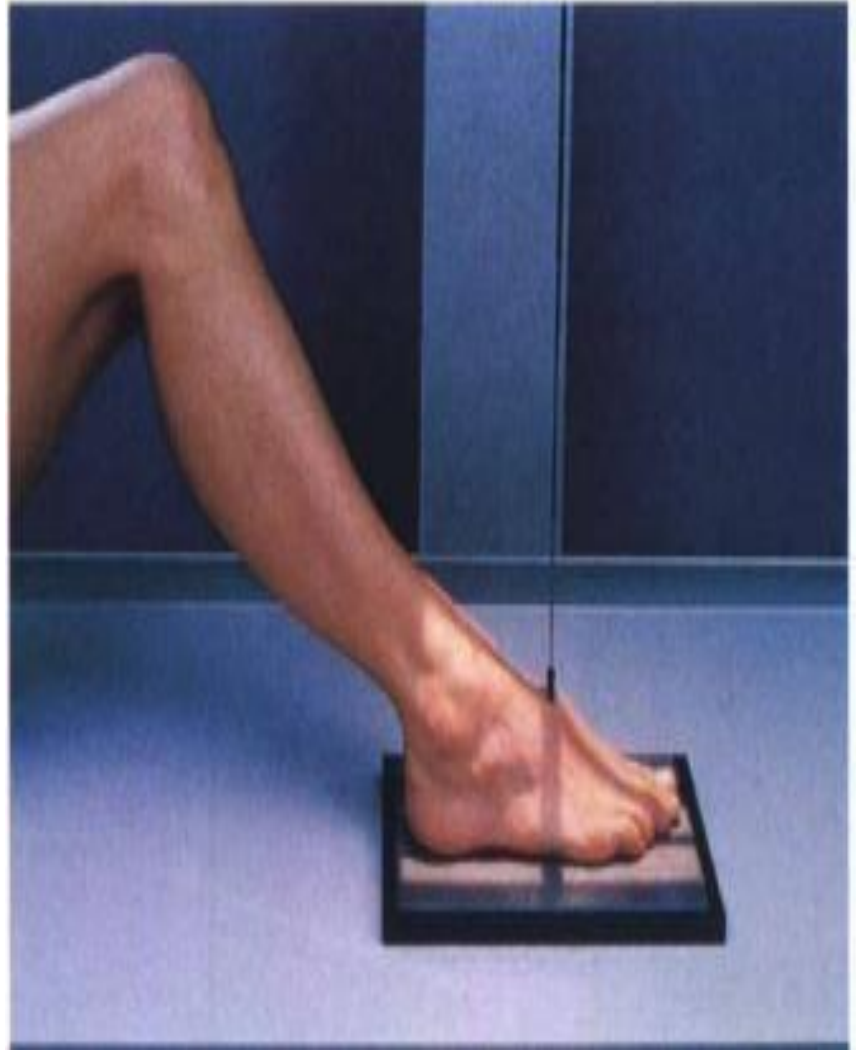
Anterio-posterior(AP)Position

Essential image characteristics

- Entire foot should be demonstrated, including all phalanges and metatarsals and the navicular, cuneiforms, and cuboids
- The kVp selected should reduce the difference in subject contrast between the thickness of the toes and the tarsus to give uniform radiographic contrast over the range of foot densities

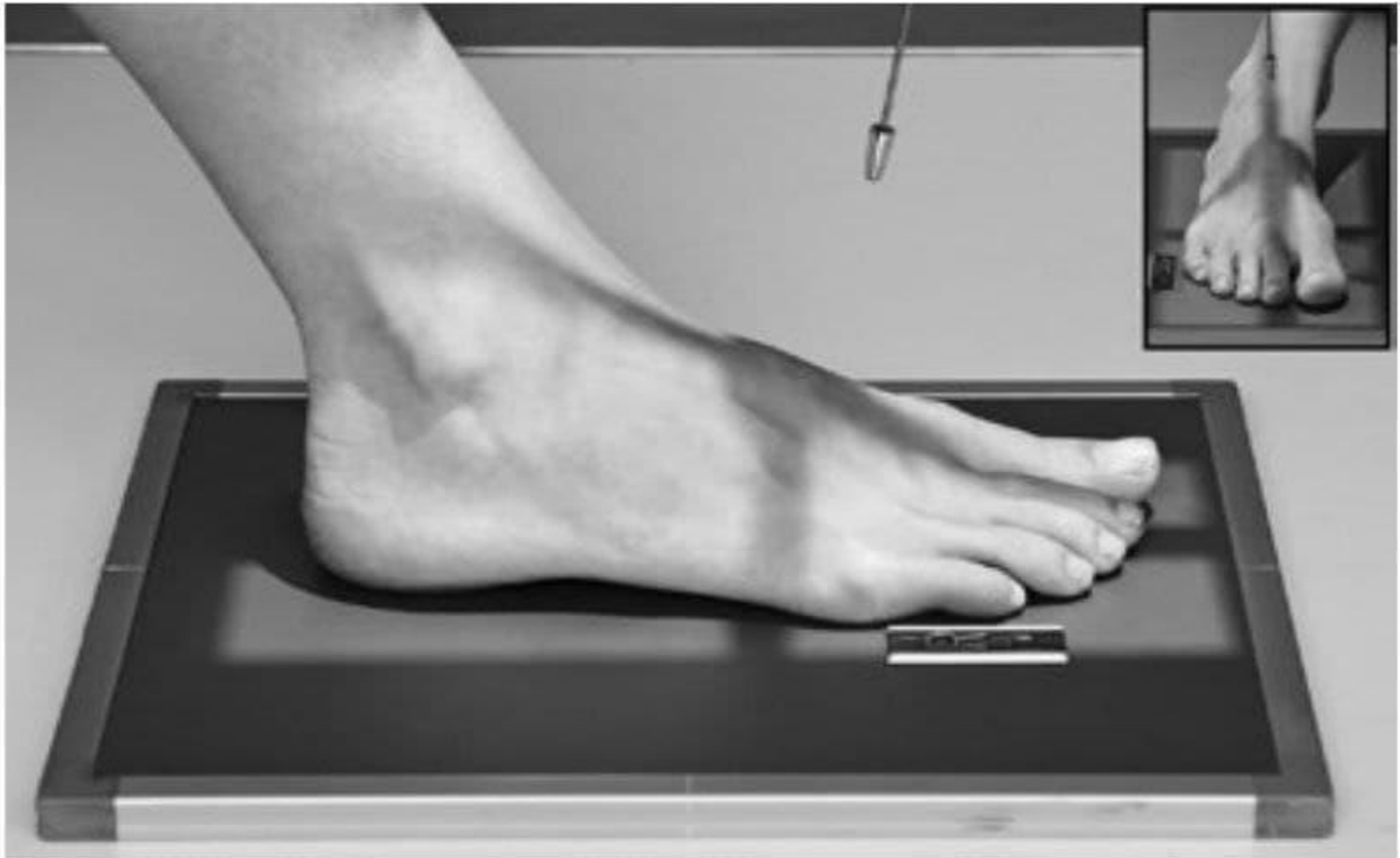

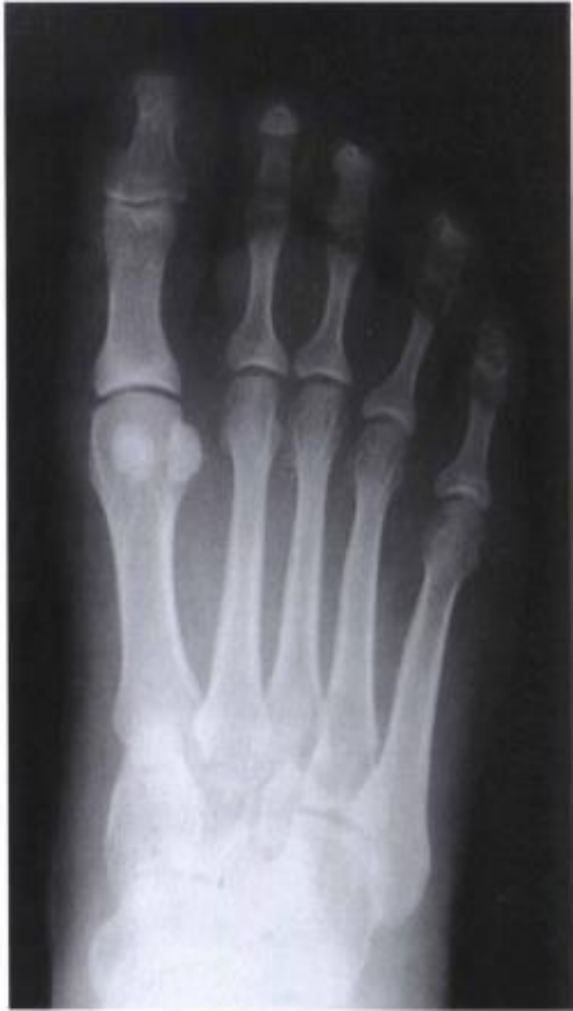Fig. 4.12 AP foot, CR 10° posteriorly.



Oblique

Position of patient and cassette

- the affected limb is allowed to lean medially to bring the plantar surface of the foot approximately 30–45 degrees to the cassette
- Use 45 degree radiolucent support block to prevent motion.
- Use sandbags of necessary to prevent cassette from slipping on tabletop

Oblique

Direction and centring of the X-ray beam

- The vertical central ray is directed to base of third metatarsal.

Note/

Some references suggest only 30degree oblique routinely. This text recommends greater obliquity 40 to 50 degrees, to best demonstrate tarsals and proximal metatarsals relatively free of superimposition for the foot with an average transverse arch.

Oblique

Essential image characteristics

- The kVp selected should reduce the difference in subject contrast between the thickness of the toes and the tarsus to give a uniform radiographic contrast over the range of foot densities.

Optional Lateral Oblique

- Rotate the foot laterally 30 degrees (less oblique required because of the natural arch of the foot).

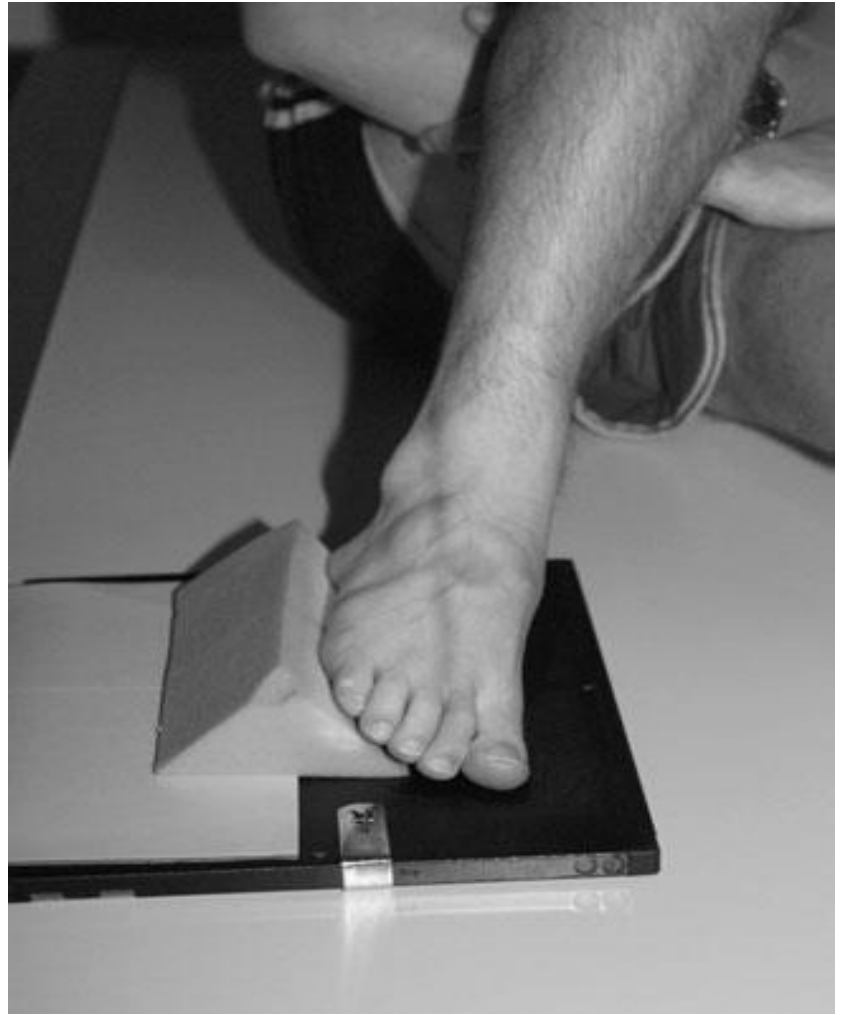
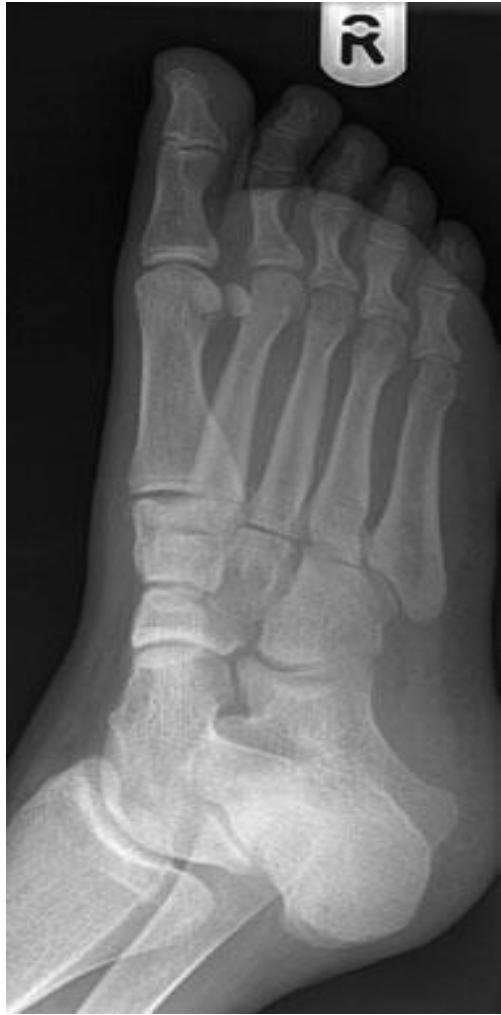- A lateral oblique will best demonstrate the space between first and second metatarsals and between first and second cuneiforms.


The navicular also will be well visualized on the lateral oblique.

- Entire foot should be demonstrated from distal phalanges to posterior calcaneus and proximal talus

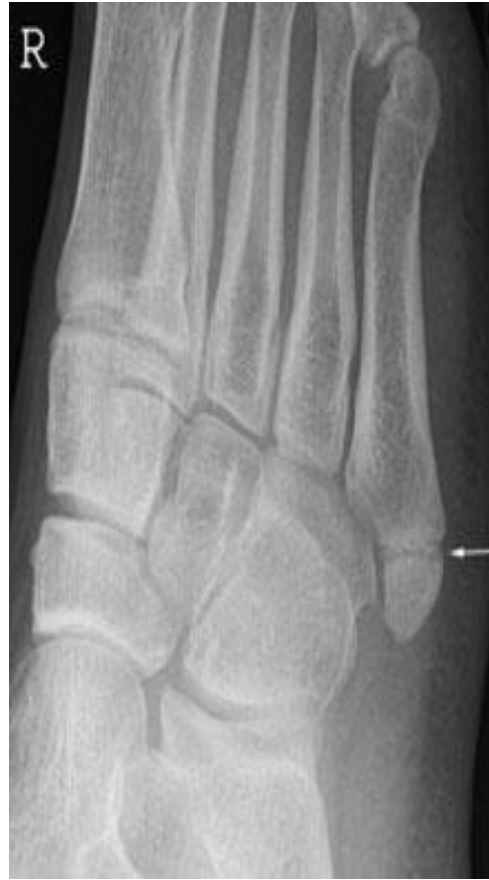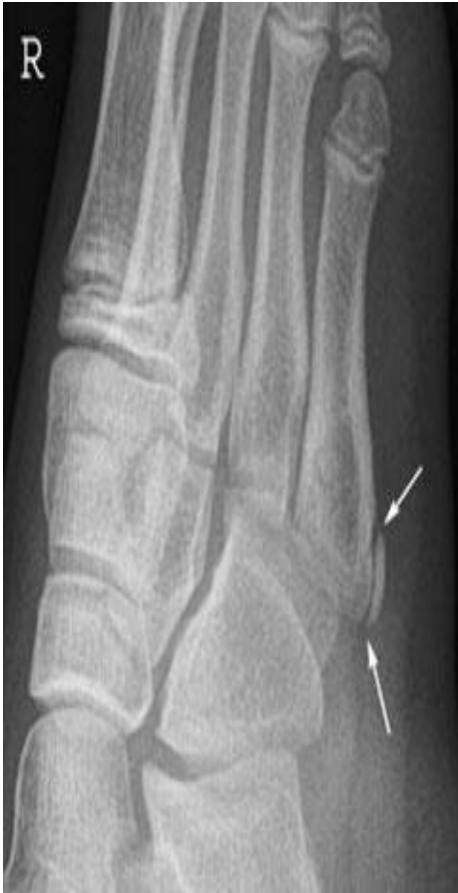Optional Lateral Oblique

- Correct obliquity is demonstrated when third through fifth metatarsals are free of superimposition
- First and second metatarsals also should be free of superimposition except for base area.
- Tuberosity at base of fifth metatarsal are seen in profile and is well visualized.
- Joint spaces around cuboid and the tarsi are open and well demonstrated when foot is oblique correctly





Optional Lateral Oblique



Radiographs showing normal fifth metatarsal ossification center on the left, and fracture base fifth metatarsal on right

Lateral

Position of patient and cassette

-From AP position, the leg is rotated outwards to bring the lateral aspect of the foot in contact with the cassette.

-The position of the foot is adjusted slightly to bring the plantar aspect perpendicular to the cassette.

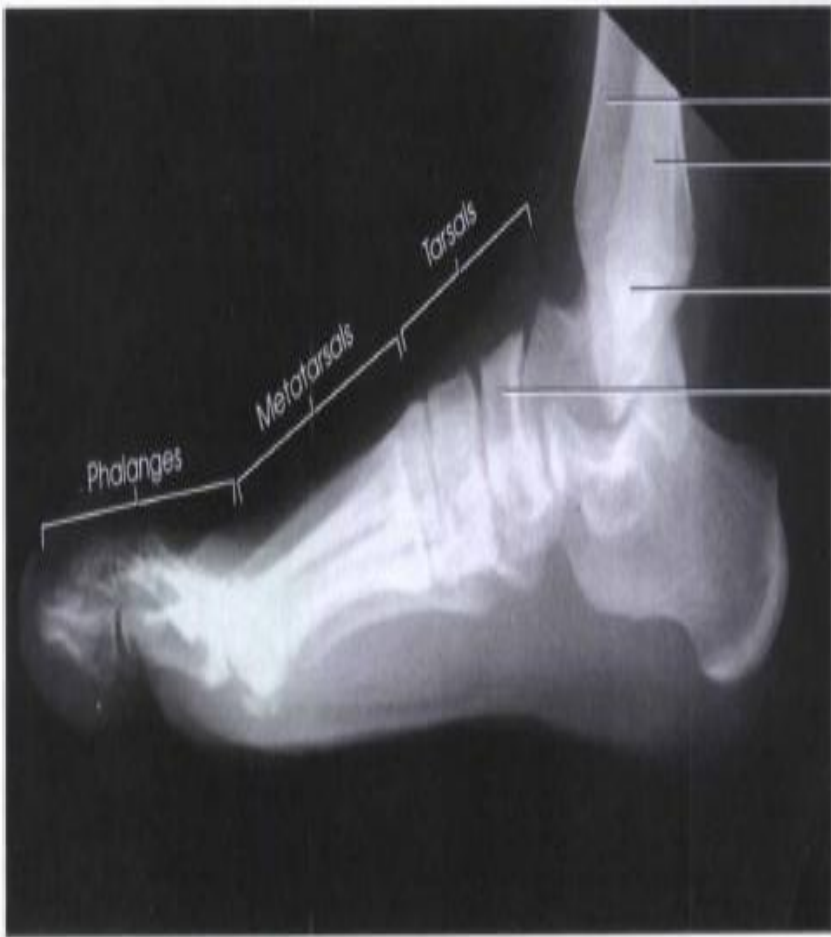Direction and centring of the X-ray beam

-The vertical central ray is centred over the navicular cuneiform joint or medial cuneiform.


Lateral

Essential image characteristics

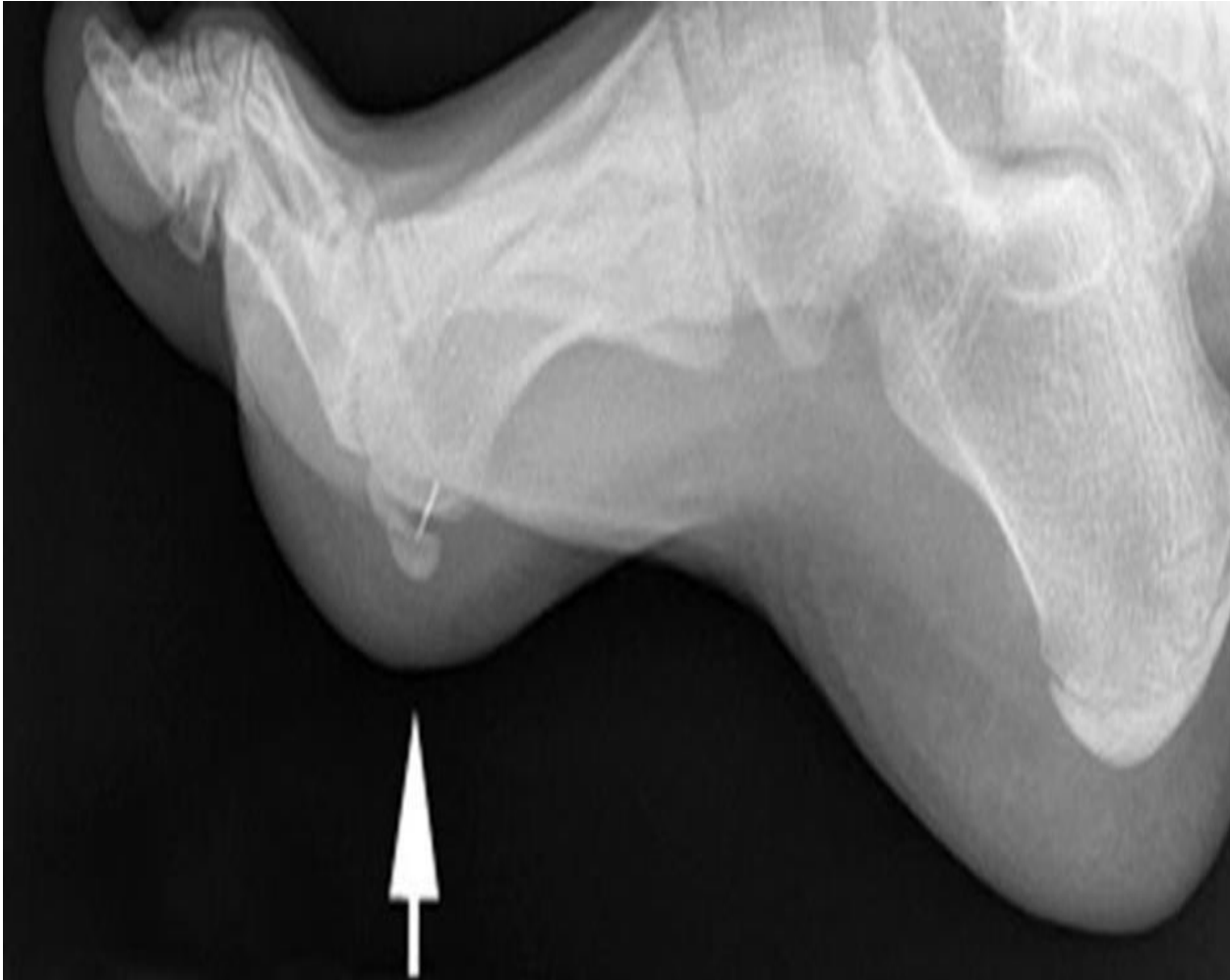- If examining for a suspected foreign body, the kVp selected should be adequate to show the foreign body against the soft tissue structures



Tibia
Fibula
Tibiotalar joint
Navicular



Lateral



Lateral
radiograph
of foot
showing
metallic
foreign body

Thank
you!





Radiology Techniques Department

Radiographic imaging

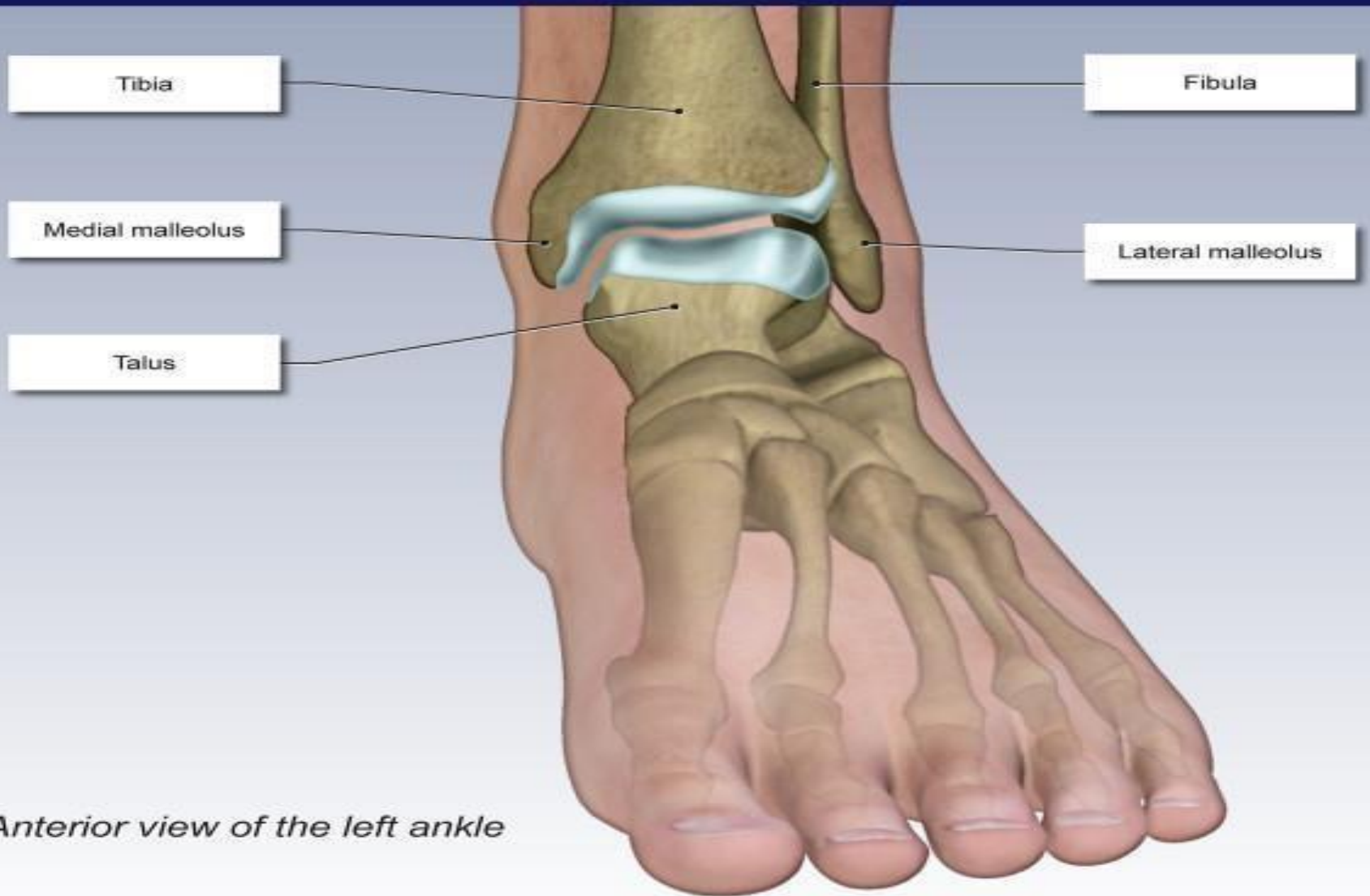
Radiographic position of ankle joint

Lecture 11

د. حيدر سعيد شندل

M.B.CH.B MSc. RAD. (ASU)

Anatomy of the Ankle



Anterior view of the left ankle

Ankle Joint

Basic position of ankle

- Antero-posterior(AP)Position
- Oblique Position
- Lateral Position

Antero-posterior (AP) position

Position of patient and cassette

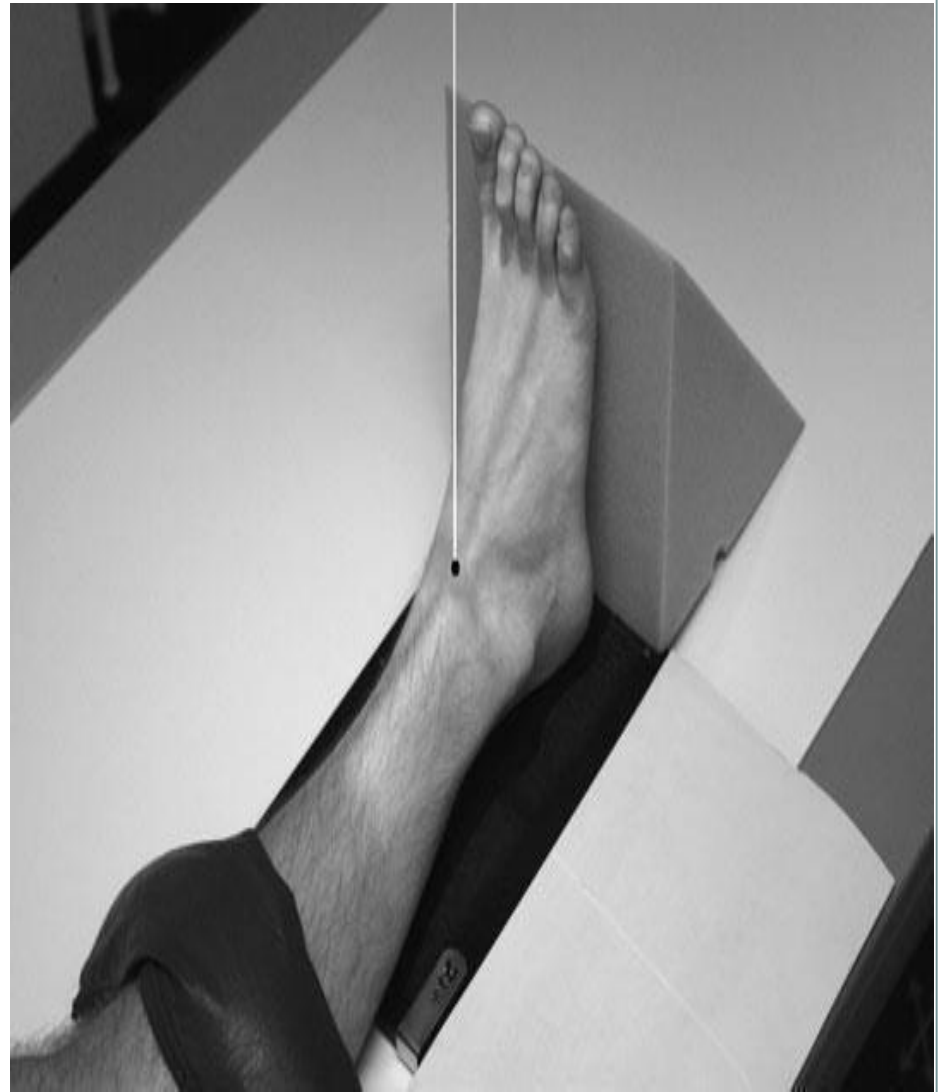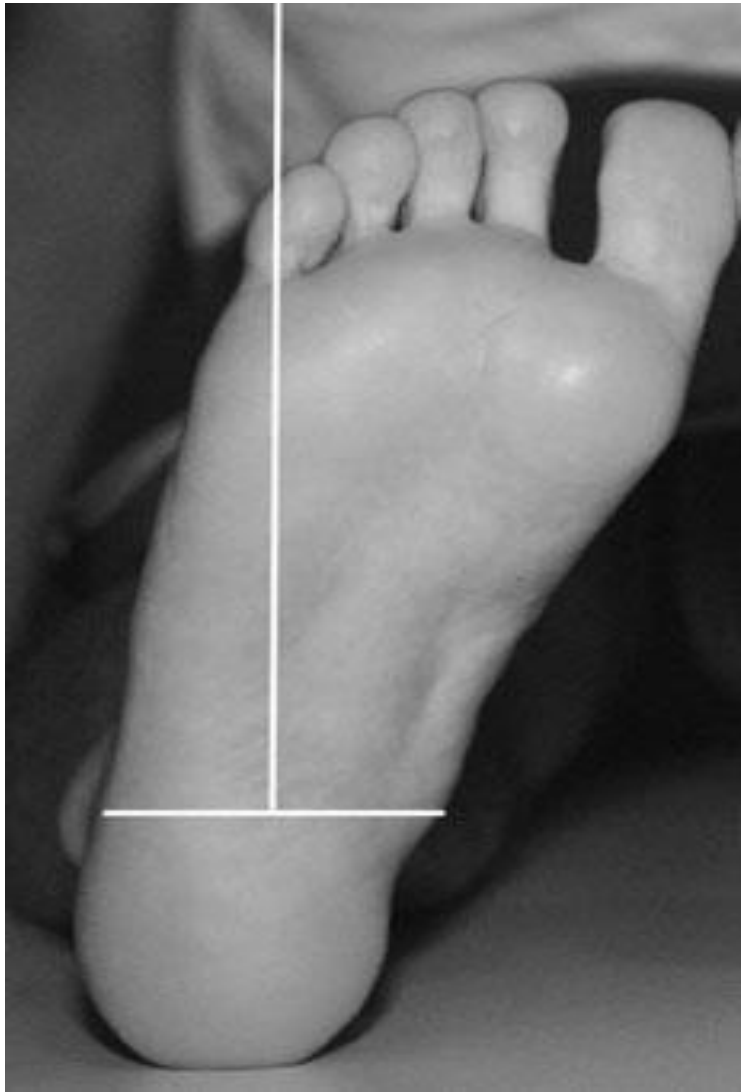- The patient is either **supine** or **seated** on the X-ray table with both legs extended.
- Place the lower leg in the AP position
- The foot is dorsiflexed so that the **plantar surface** is perpendicular to the table
- The affected ankle is rotated **medially** (approximately **20 degrees**) until the medial and lateral malleoli are equidistant from the cassette.
- The cassette is positioned **out Bucky** (10x12).

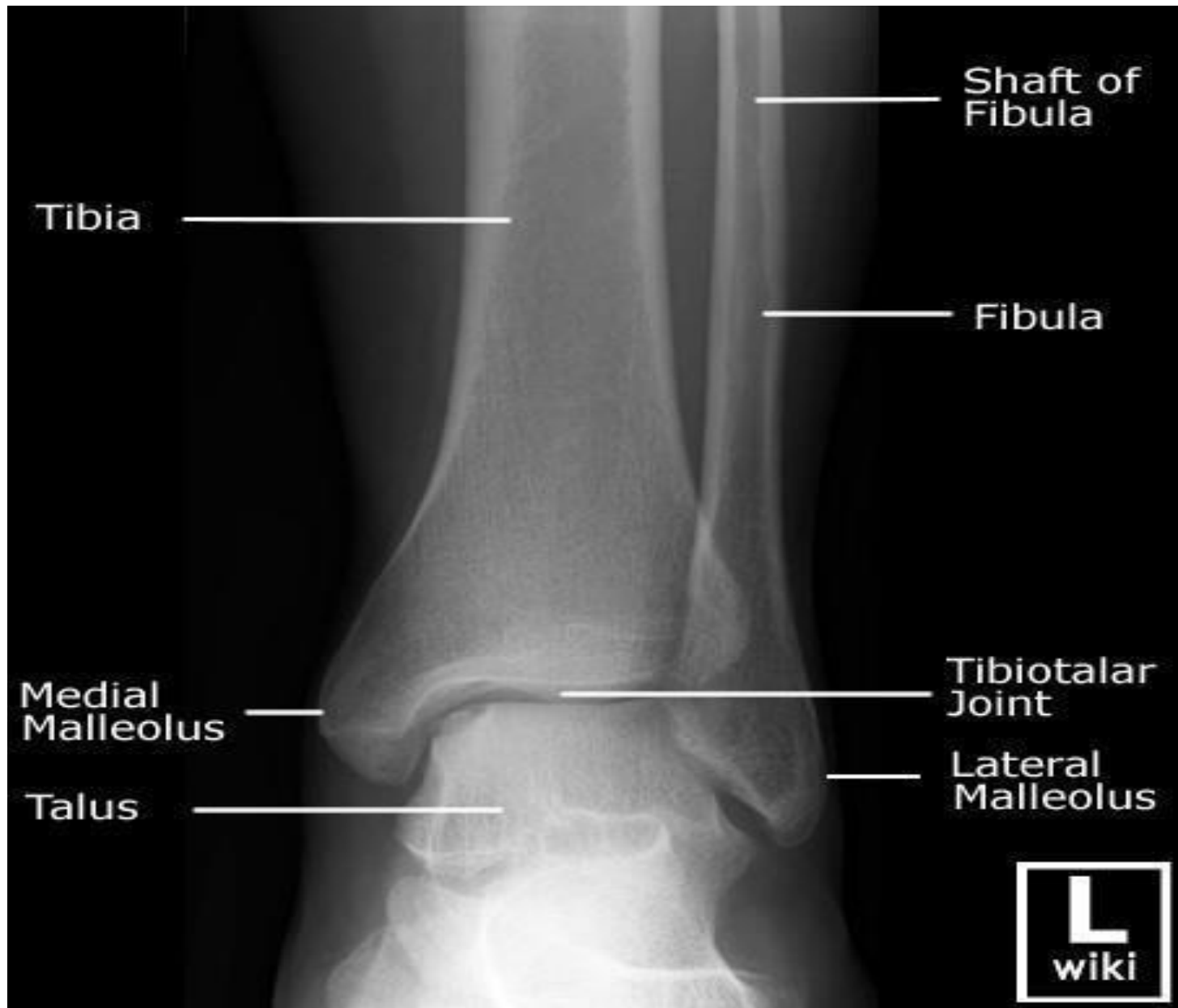
Direction and centering of the X-ray beam

- Centre midway between the malleoli.

Essential image characteristics

- The lower third of the tibia and fibula should be included.
- A clear joint space between the tibia, fibula and talus should be demonstrated





Note

The effect of not achieving the lower leg in AP position

- Internal rotation of the leg will show no superimposition of the **talus** on the **fibula**
- External rotation of the leg will show greater superimposition of the tibia and talus on the fibula

(commonly called the Mortise view)

Lateral position

Position of patient and cassette

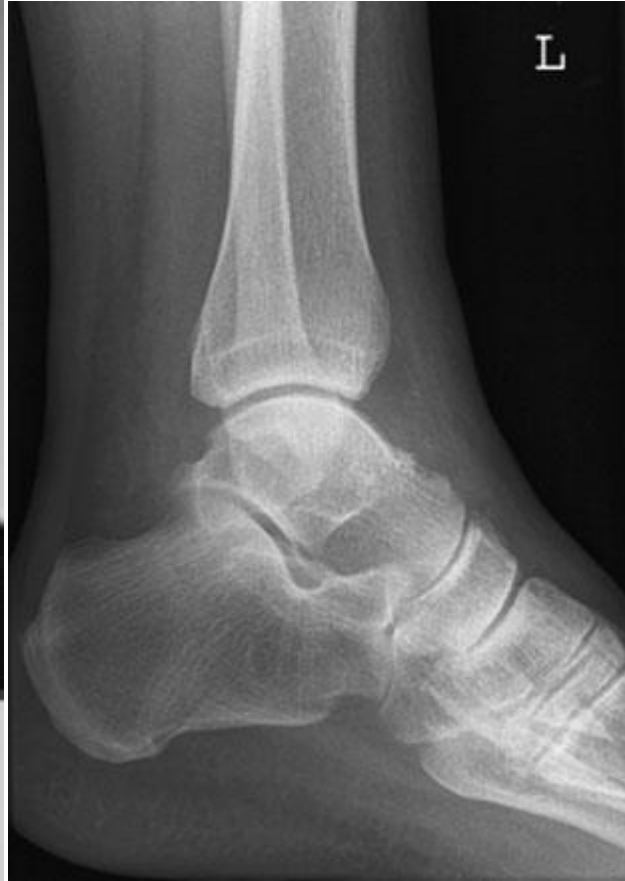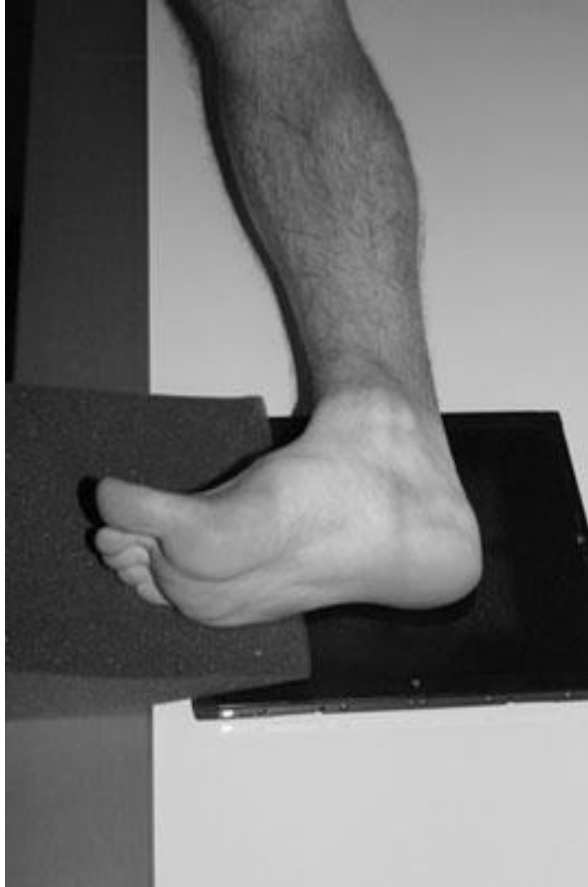- The leg is rotated until the **medial** and **lateral** malleoli are superimposed **vertically**
- Rotate the leg and foot of the affected side so that the lateral foot surface against the IR
- The cassette is placed **out Bucky(10x12)**.
- Ask the patient to dorsiflex , if possible, so that the plantar surface is at 90° to the lower leg.
- The **malleoli** are **superimposed**

Direction and centering of the X ray beam

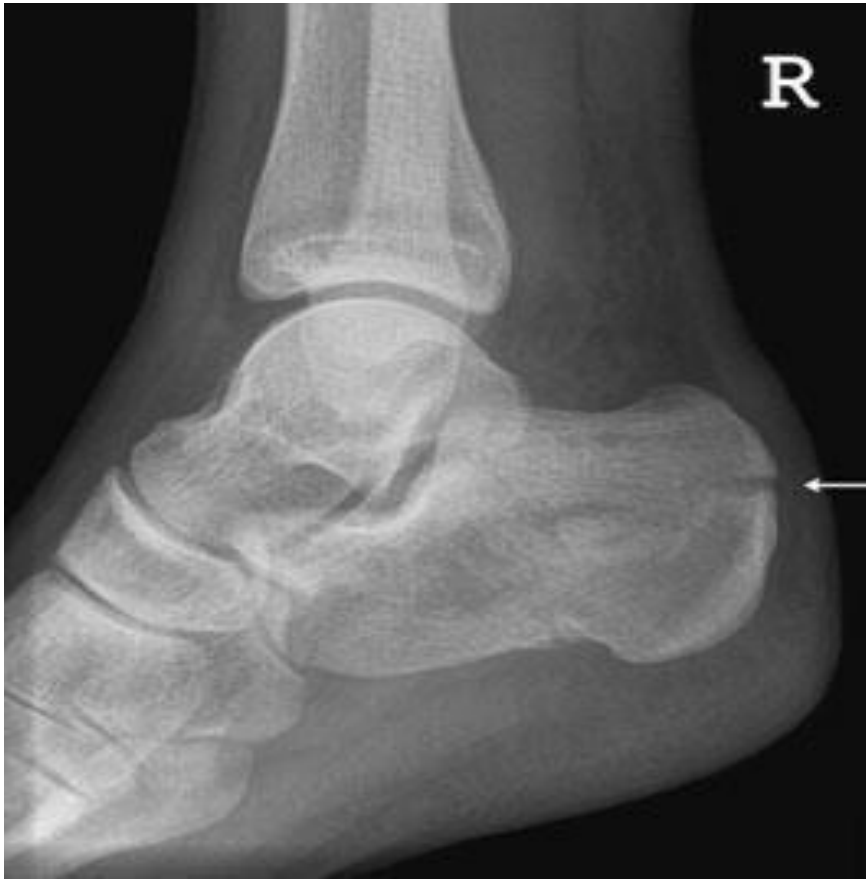- Centre to the medial malleolus, with the vertical central ray **perpendicular** to the cassette.

Essential image characteristics

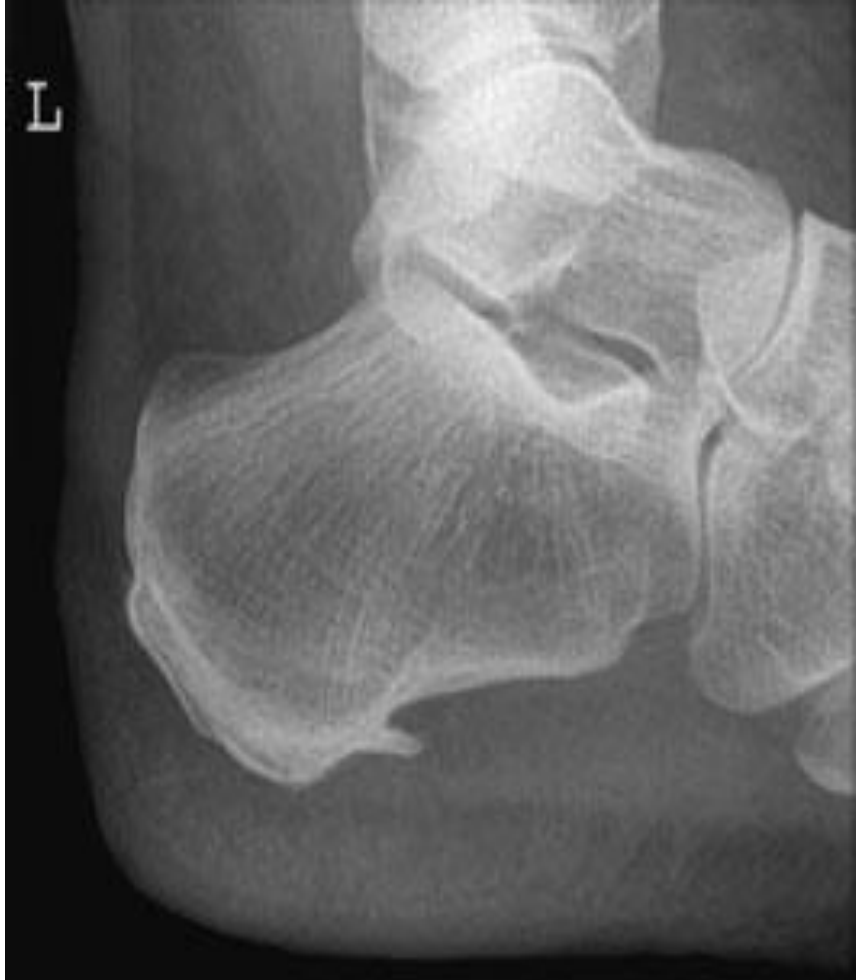- The adjacent tarsal bones should be included in the lateral projection, together with the ankle joint.



Normal lateral radiograph of ankle



Fracture of the
calcaneum Lateral
calcaneum radiographs
of the ankle



Calcaneal spur

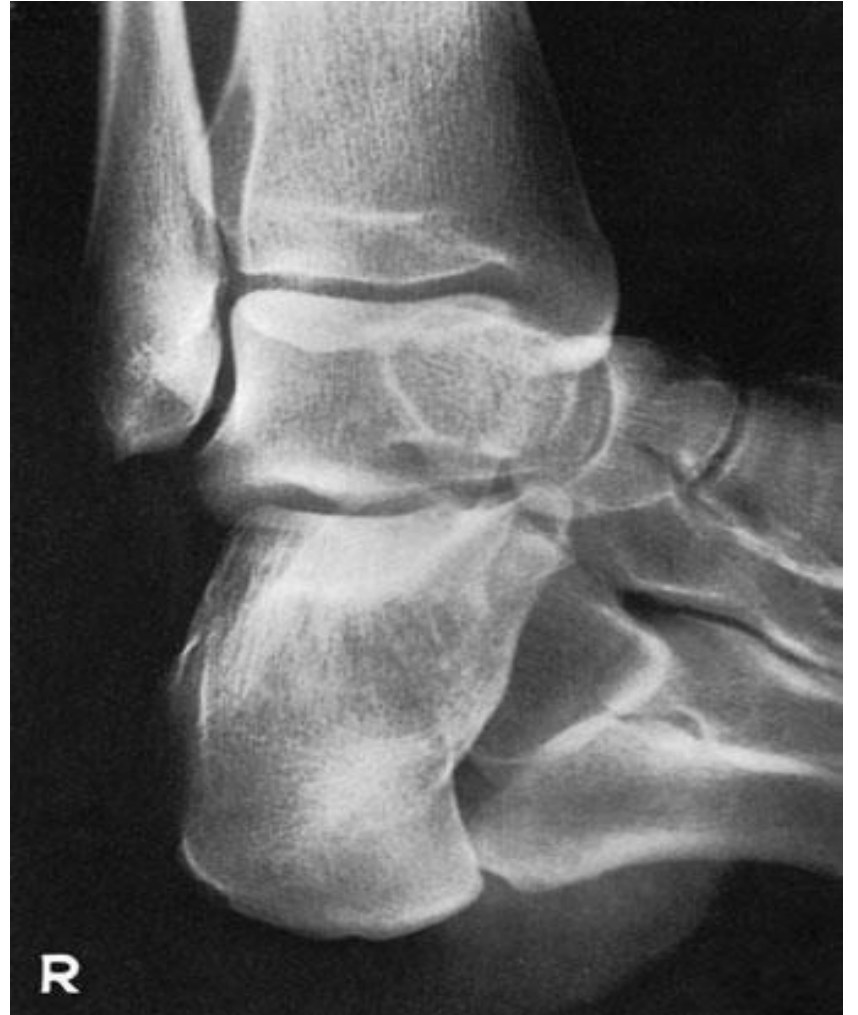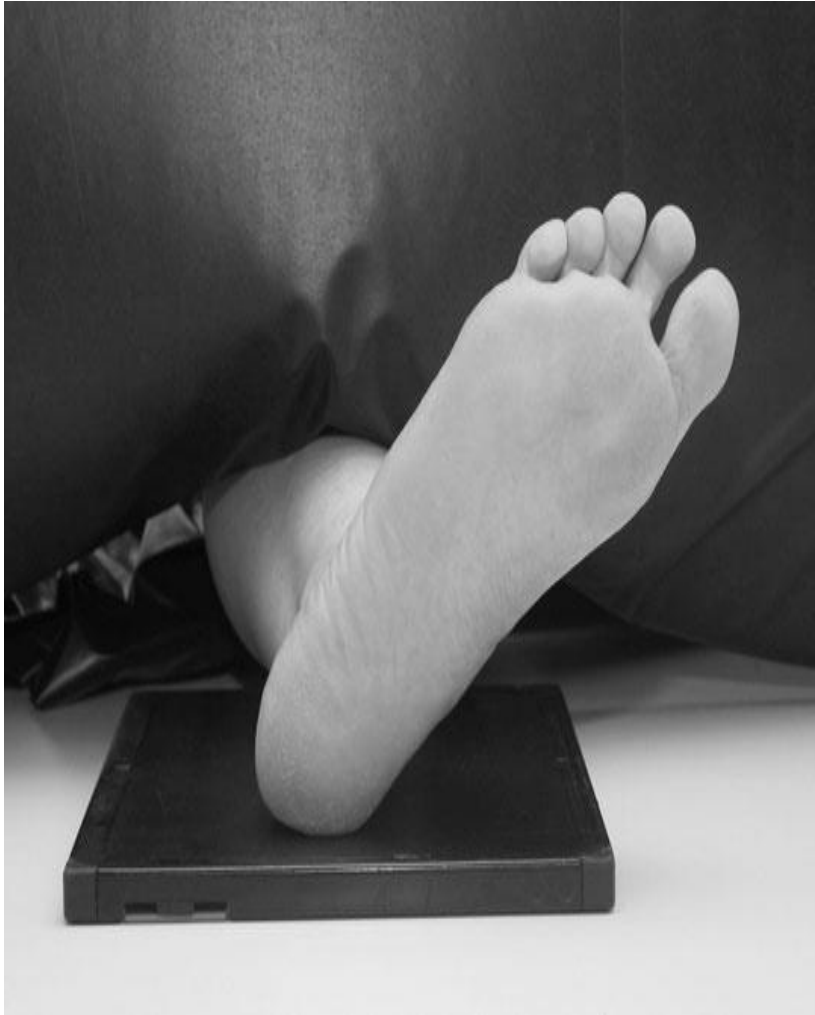Oblique medial

Position of patient and cassette

- The patient sits or lies supine on the X-ray table, with the affected limb extended.
- The leg is internally rotated through 45 degrees.
- cassette (8x10) out Bucky.

Direction and centering of the X-ray beam

- Centre to the lateral malleolus.



Oblique lateral

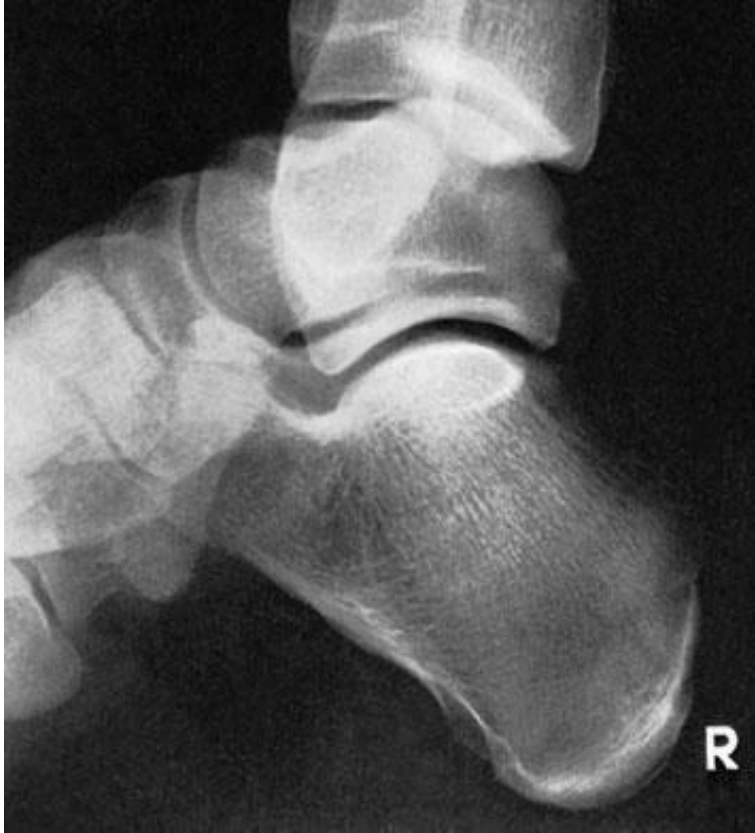Position of patient and cassette

The patient sits or lies supine on the X-ray table, with the affected limb extended

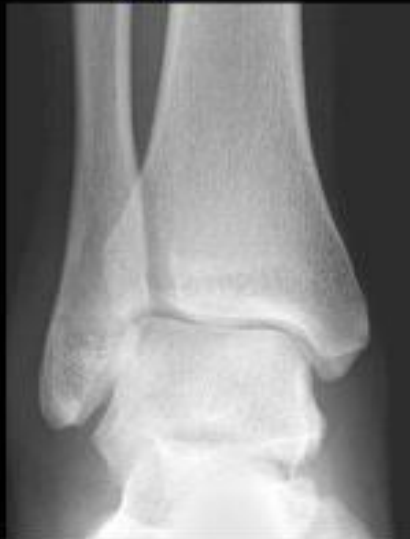- The leg is externally rotated through 45degrees
- cassette (8x10) out Bucky.

Direction and centering of the X-ray beam

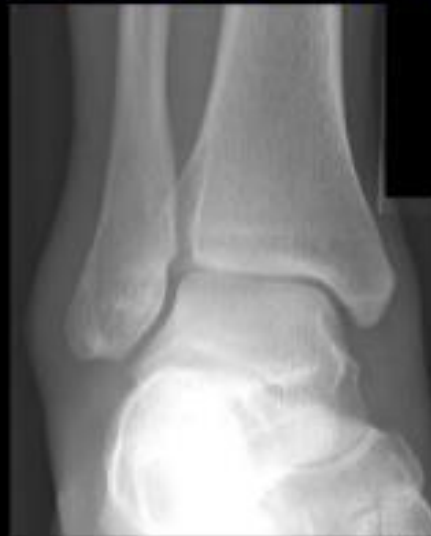- Centre to the medial malleolus



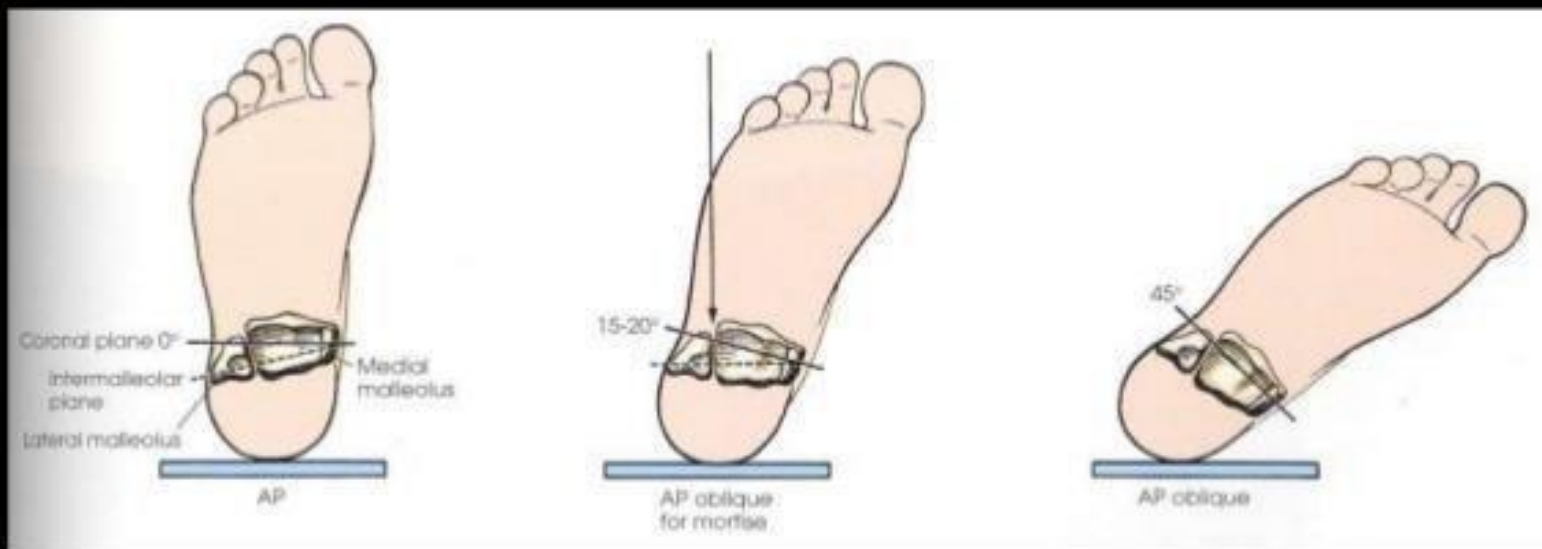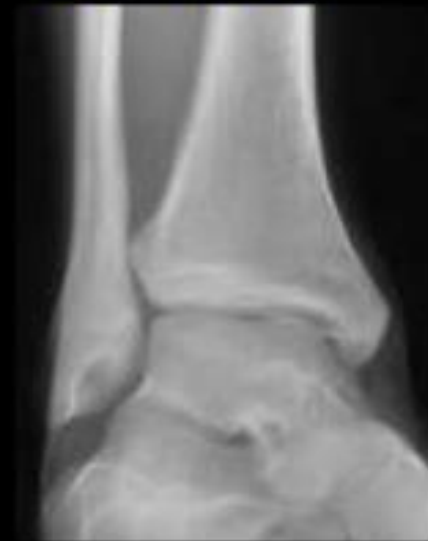AP



15°-20° Oblique (Mortise)



45° Oblique



HEEL AXIAL (PLANTODORSAL)

Purpose of this position

- 1 No rotation of calcaneus
- 2 Anterior portion of calcaneus without excessive density over posterior portion.

Structures Shown

Clear demonstration of calcaneus and subtalar joint.

Position of patient and cassette

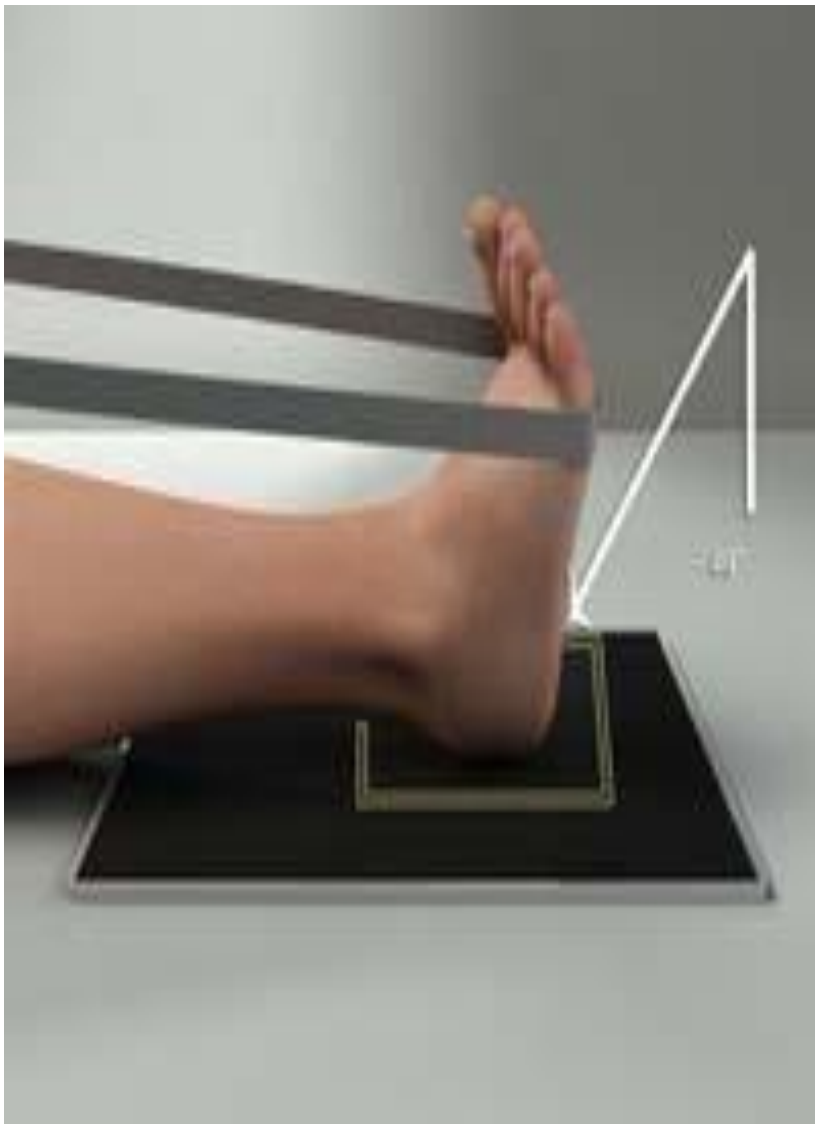
-Position of patient Supine or seated position with legs fully extended.

-Radiologic technologists may place IR under patient's ankle, centered to midline of ankle. Place long strip of gauze around ball of foot.

- Have patient pull gauze to hold ankle in right angle. If patient's ankle cannot be dorsiflexed enough to place plantar surface of foot perpendicular to IR, raise leg on sandbags to obtain the correct position.

Direction and centering of the X-ray beam

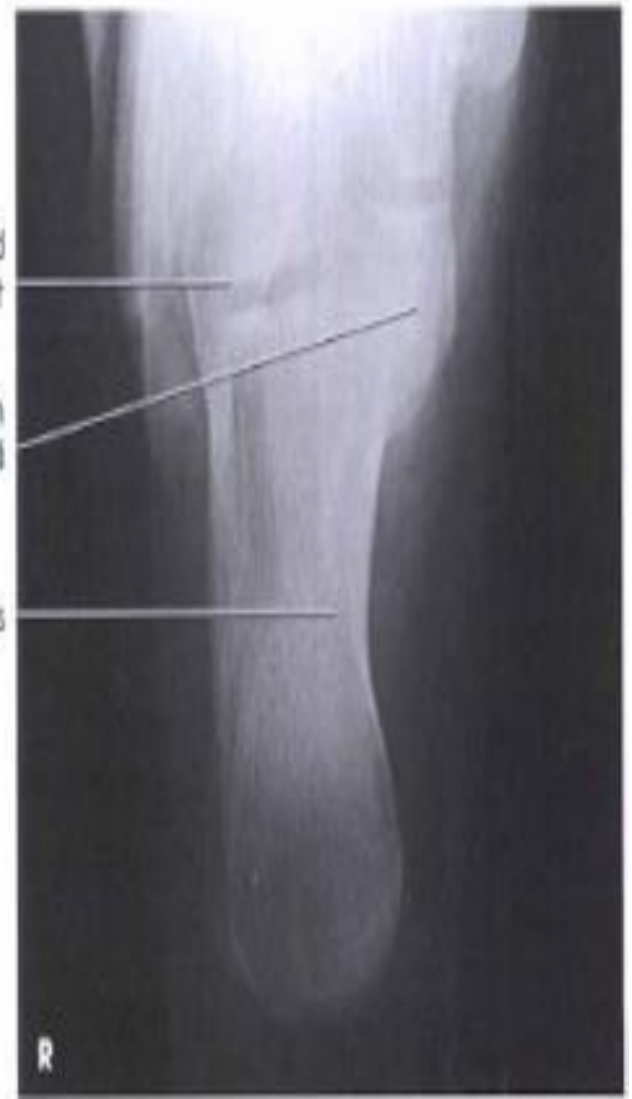- Central ray Directed to midpoint of IR at cephalic angle of 40 degrees to long axis of foot.
- CR enters base of third metatarsal.



Calcaneocuboid
joint

Sustentaculum
tal

Calcaneus



HEEL AXIAL (DORSOPLANTAR)

Position of patient and cassette

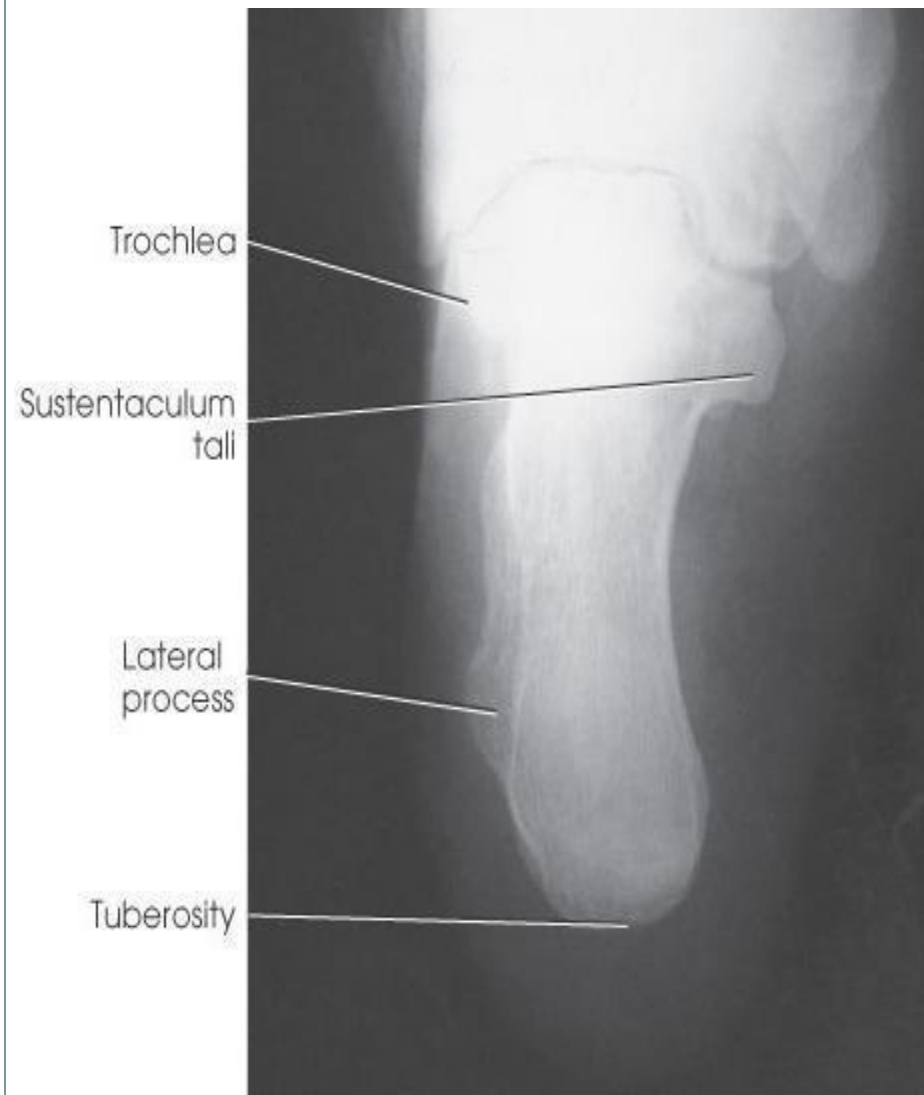
- Position of patient Prone position.
- X-ray technologists can help elevate patient's ankle on sandbags.
- Adjust height and position of sandbags so patient can dorsiflex ankle enough to place long axis of foot perpendicular to tabletop.
- Place IR against plantar surface of foot and support it in position with sandbags or a portable IR holder

Direction and centering of the X-ray beam

- Central ray Midpoint of IR at caudal angle of 40 degrees to long axis of foot.
- CR enters proximal anterior calcaneus.

Structures Shown

the x-ray should clearly demonstrate calcaneus and subtalar joints.



Thank
you!





Radiology Techniques Department

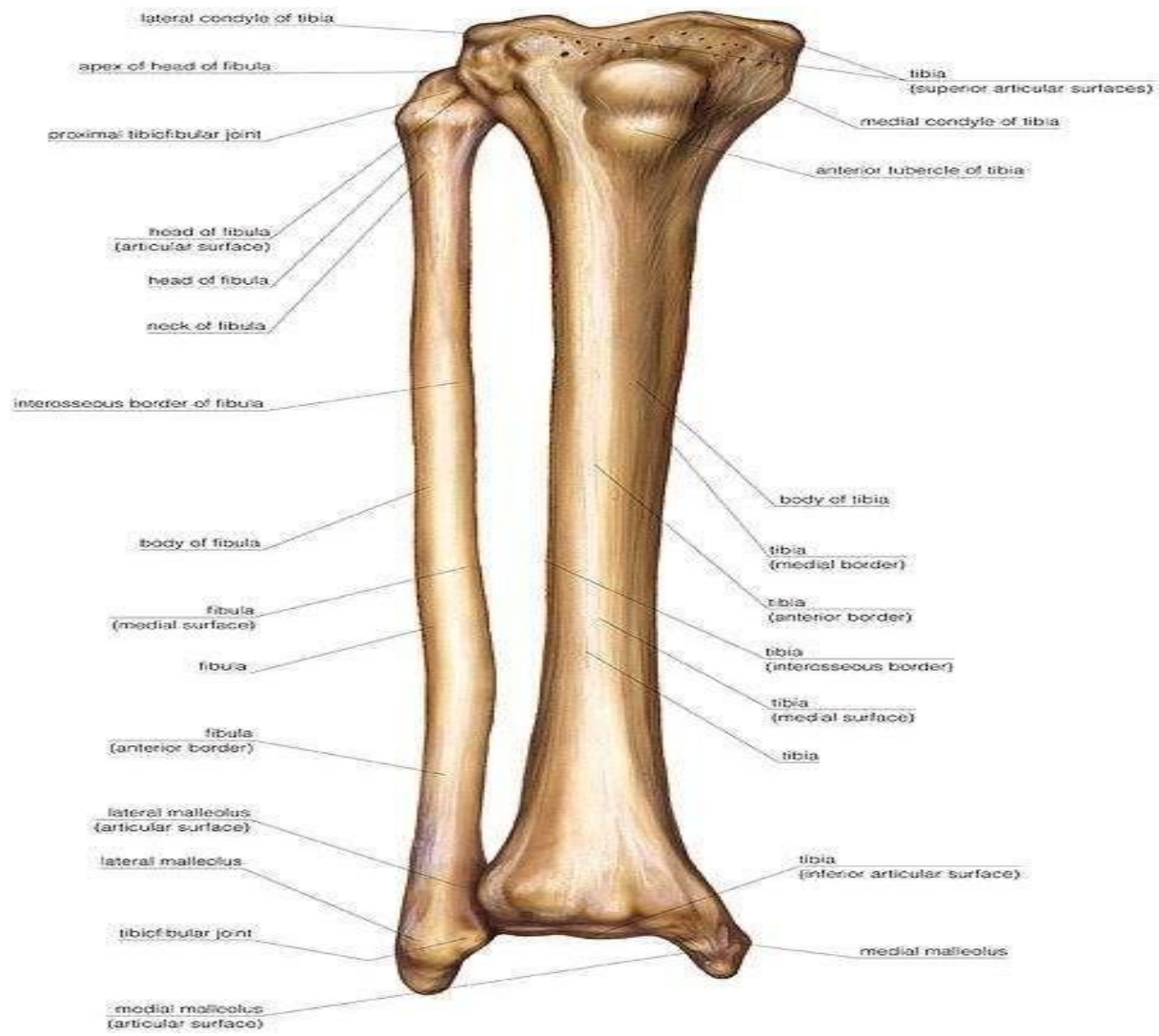
Radiographic imaging

Radiographic position of leg

Lecture 12

د. حيدر سعيد شندل

M.B.CH.B MSC. RAD. (ASU)





There are two bones

1 tibia

2 fibula

There are 2 basic positions 1- AP

2- Lateral

Anterio-posterior



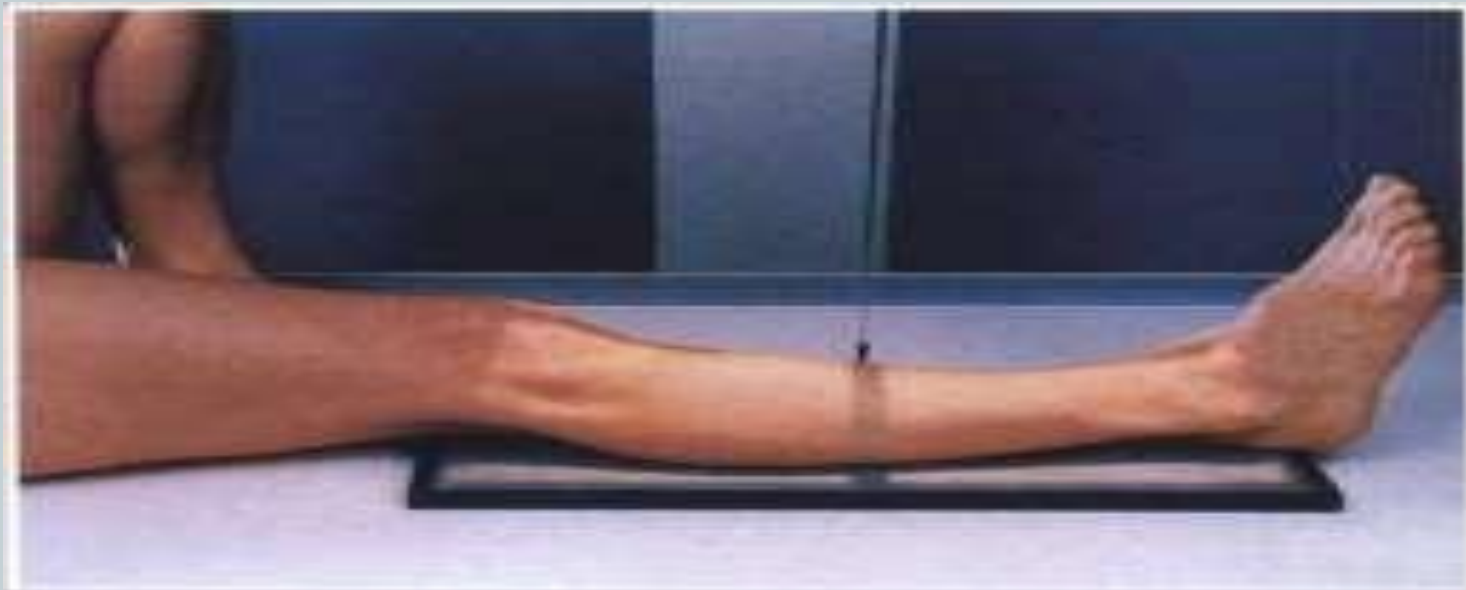
Position of patient and cassette

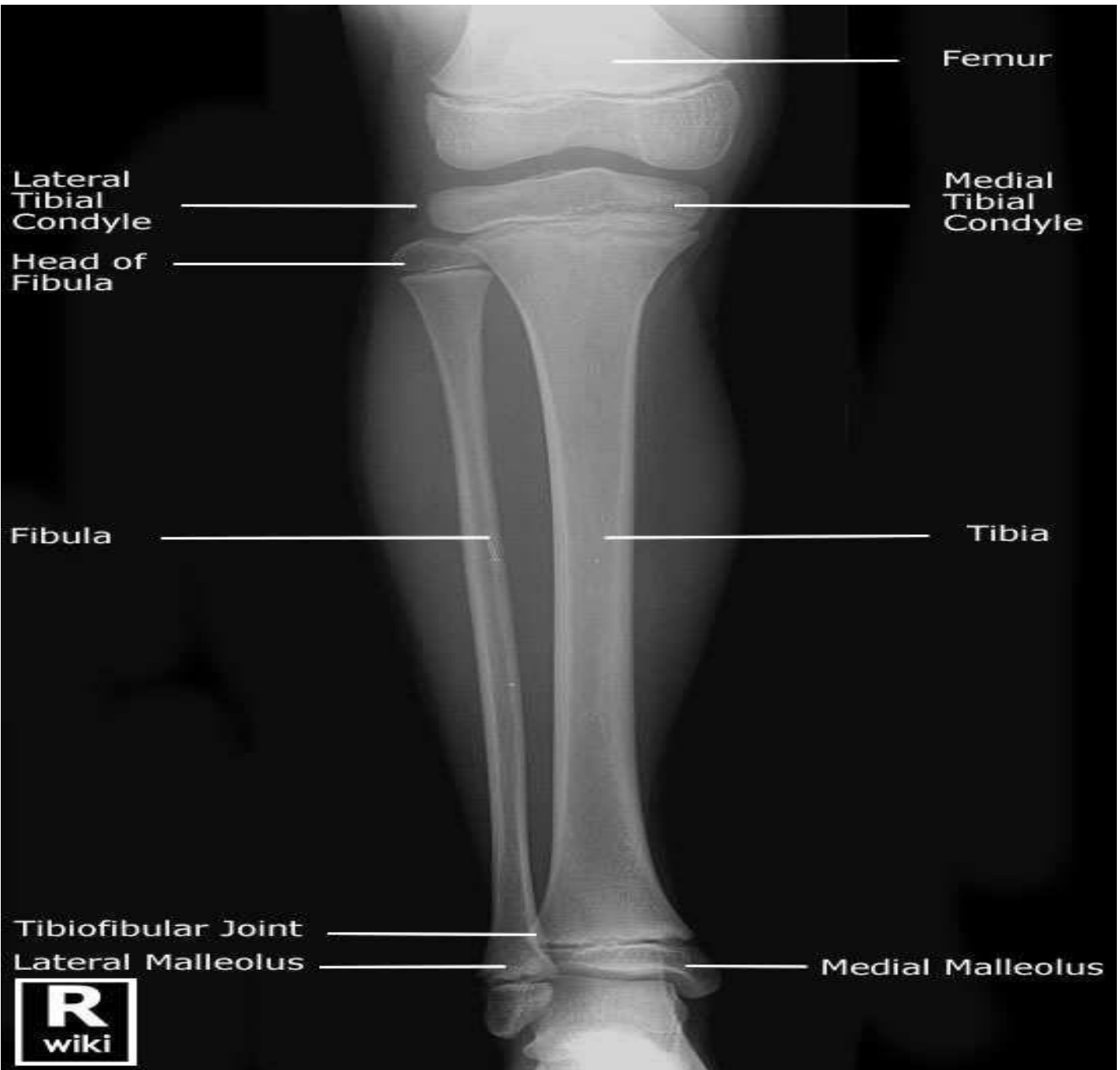- The patient is either supine or seated on the X-ray table, with both legs extended.
- The limb is rotated medially until the **medial** and **lateral malleoli** are equidistant from the cassette
- The cassette is (14x17) positioned **out Bucky**.



Direction and centering of the X-ray beam

- Centre to the **middle** of the **tibia** vertically





Femur

Lateral
Tibial
Condyle

Medial
Tibial
Condyle

Head of
Fibula

Fibula

Tibia

Tibiofibular Joint

Lateral Malleolus

Medial Malleolus



Lateral position

Position of patient and cassette

- From the **supine/seated** position, the patient rotates on to the affected side.
- The leg is rotated further until the malleoli are superimposed vertically.
- The **tibia** should be **parallel** to the cassette.

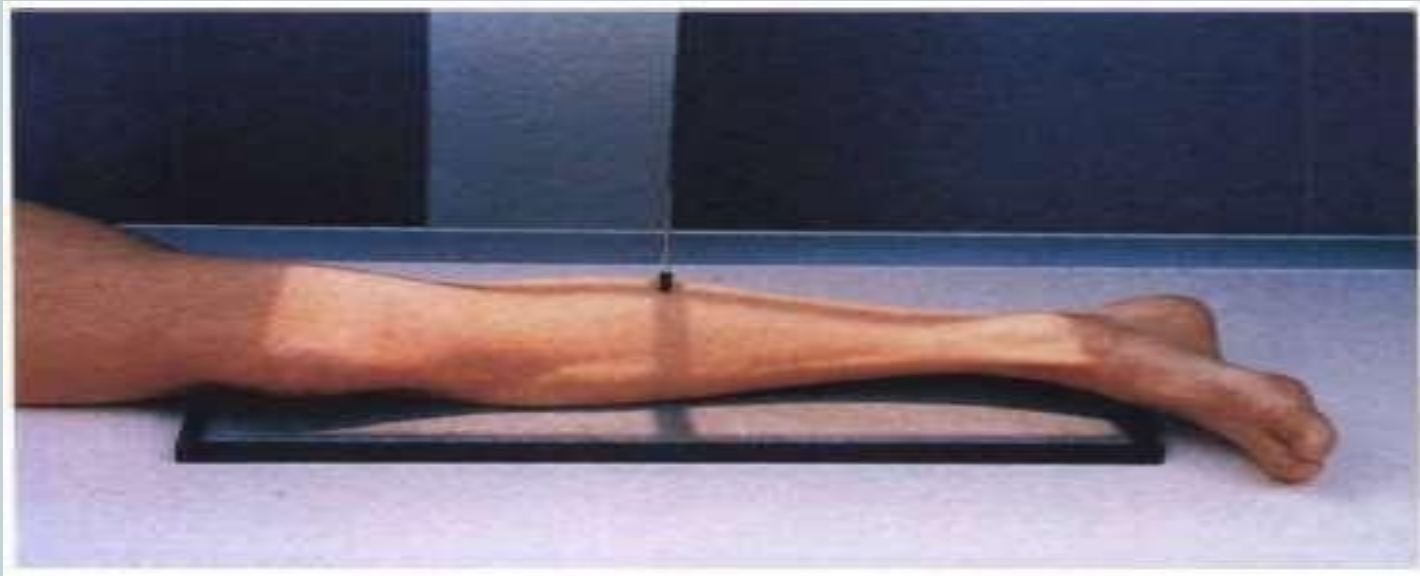
Direction and centering of the X-ray beam

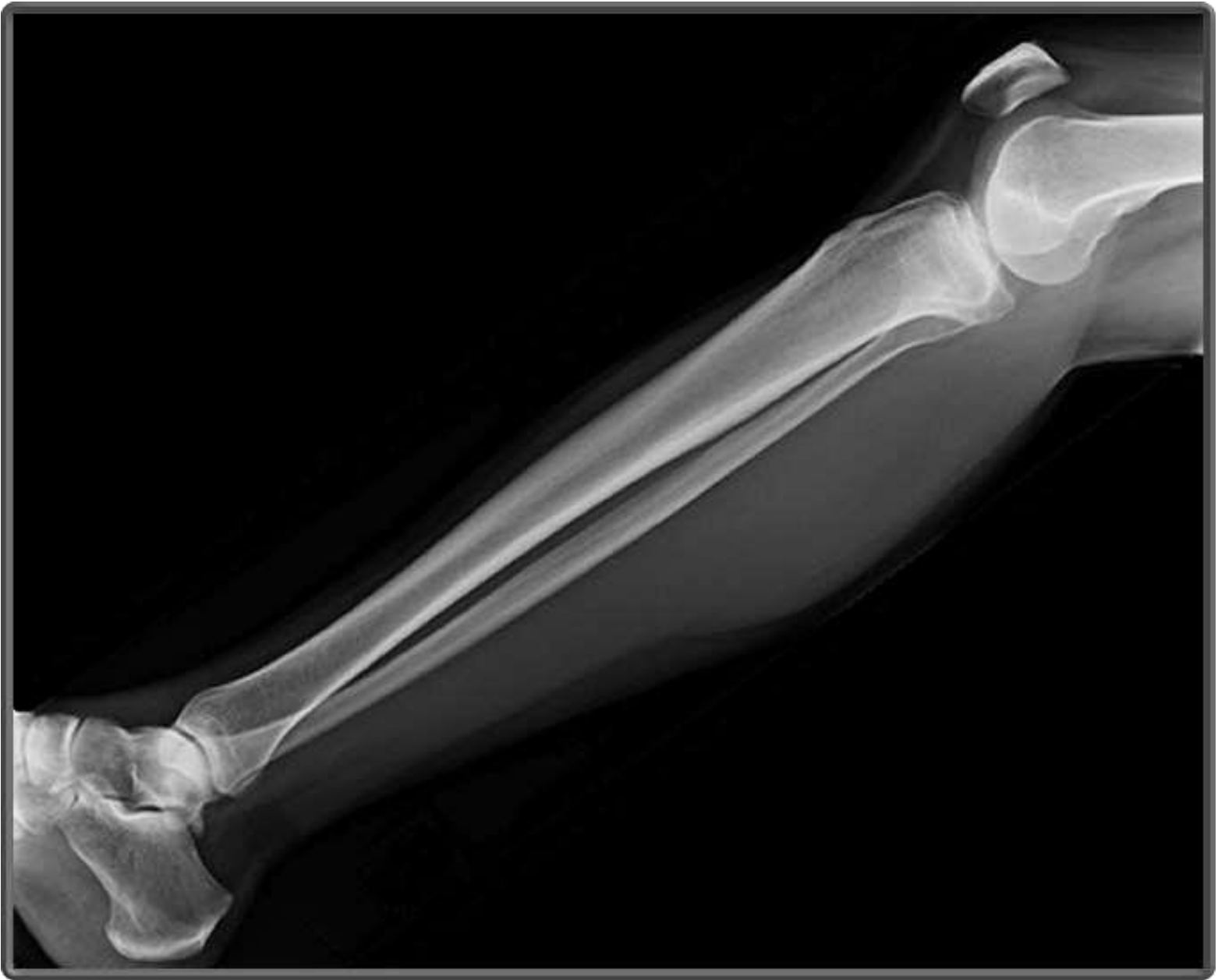- Centre to the **middle of the tibia**.



Essential image characteristics

-The **knee** and **ankle** joints must be included





Knee
joint

AP position

Position of patient and cassette

- The patient is either **supine** or **seated** on the X-ray table, with both legs extended.
- The affected limb is rotated to centralize the **patella** between the **femoral condyles**.
- The cassette (10x12) out Bucky.

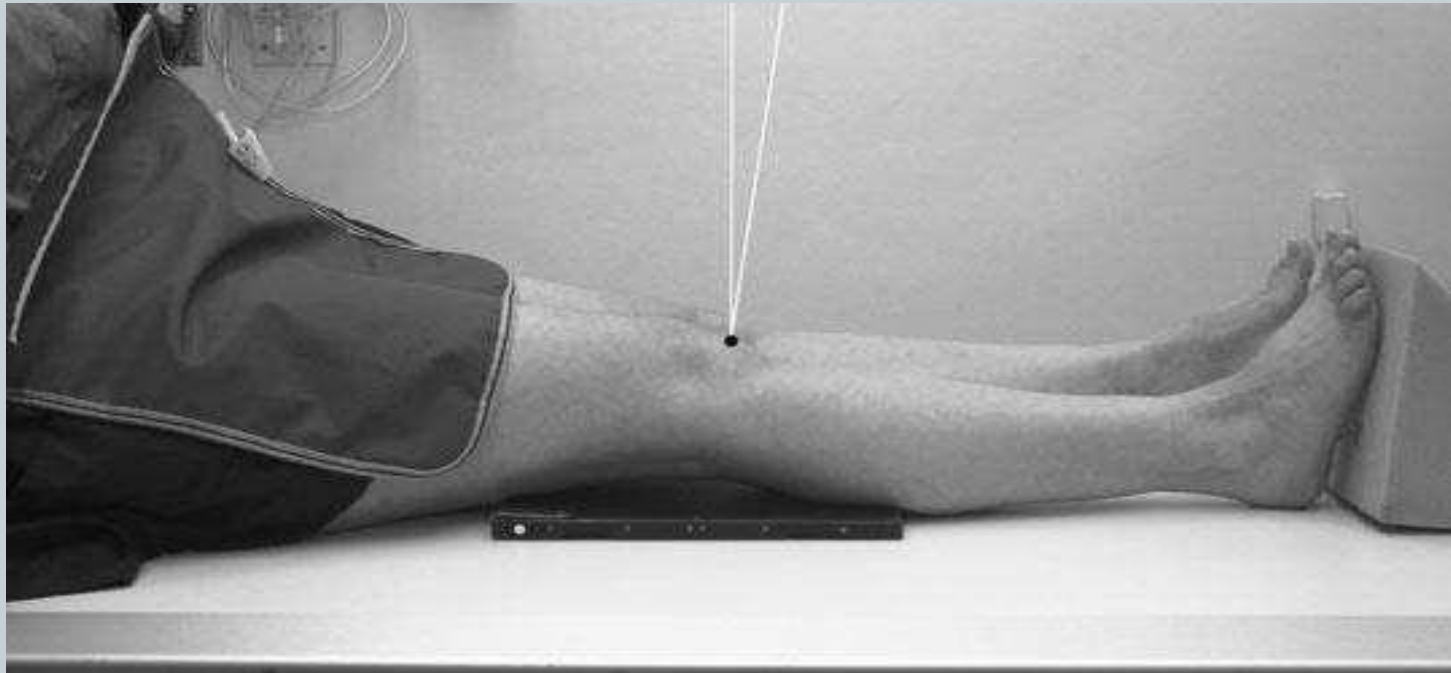
Direction and centering of the X-ray beam

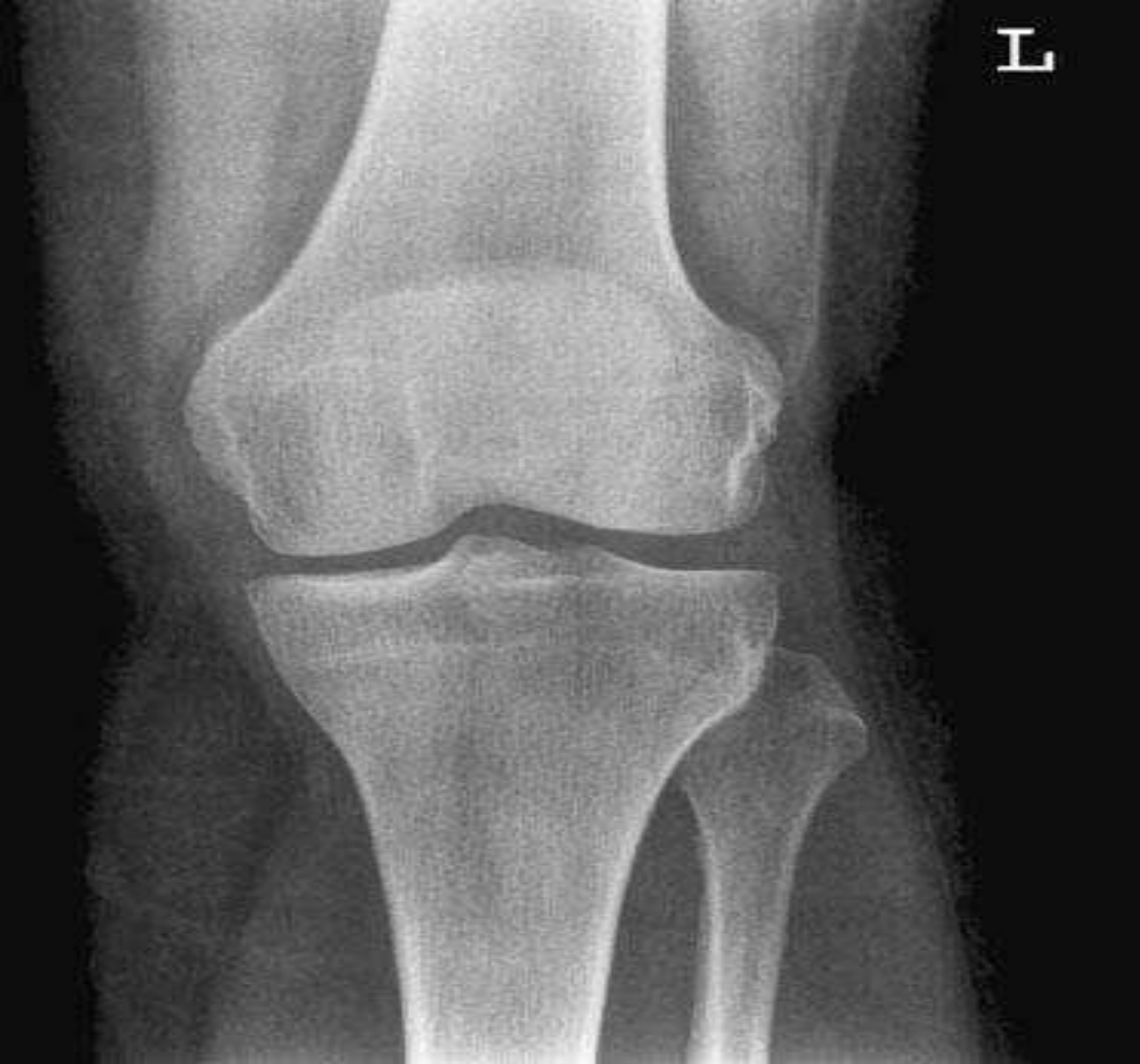- Centre **2.5 cm** below the **apex** of the **patella** through the joint space, with the central ray at 90 degrees to the long axis of the tibia.



Essential image characteristics

-The **patella** must be centralized over the **femur**.





Lateral

Position of patient and cassette

- The patient lies on the side to be examined, with the knee **flexed** at **45** or **90** degrees .
- The position of the limb is now adjusted to ensure that the femoral condyles are superimposed vertically.

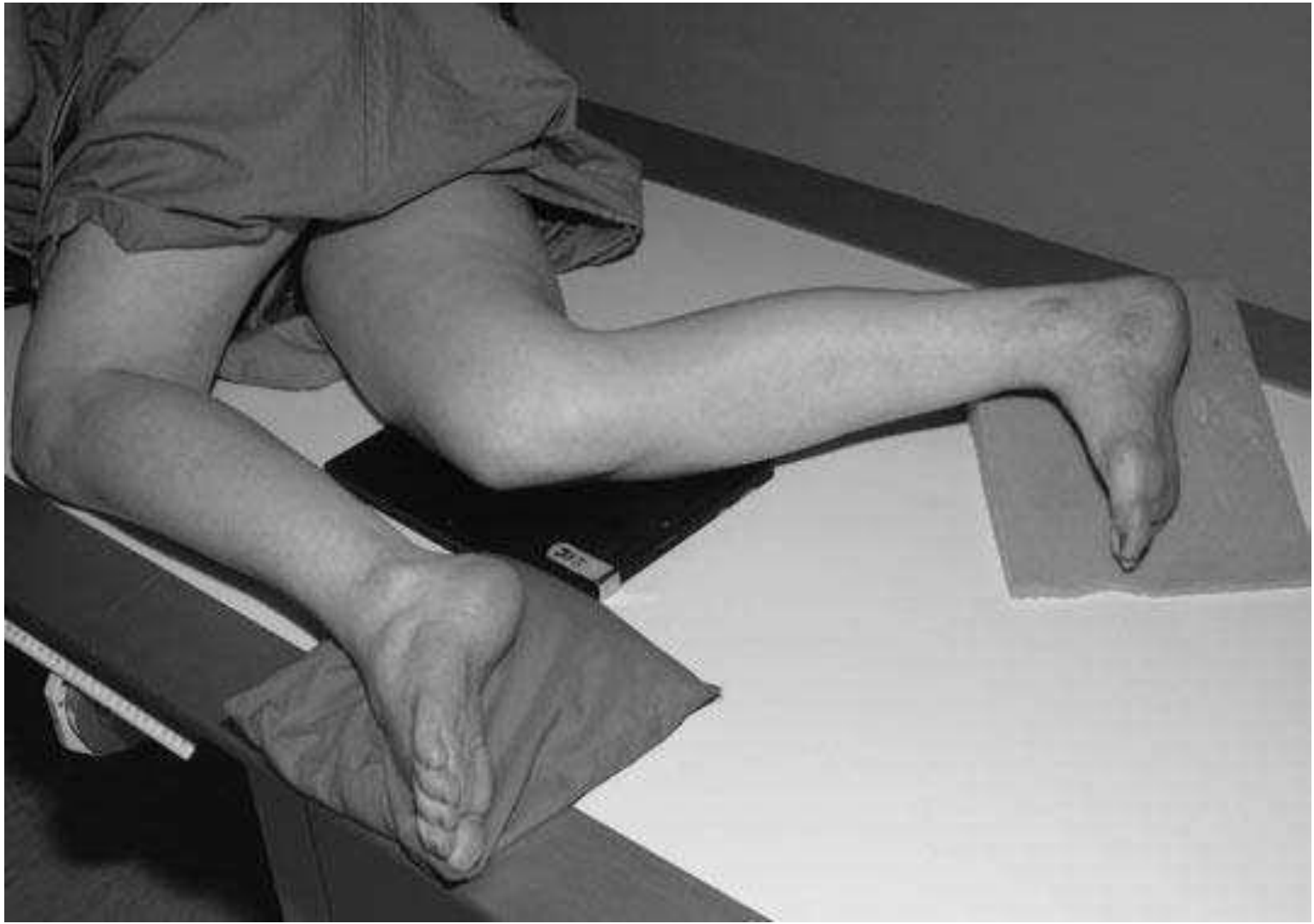Direction and centering of the X-ray beam

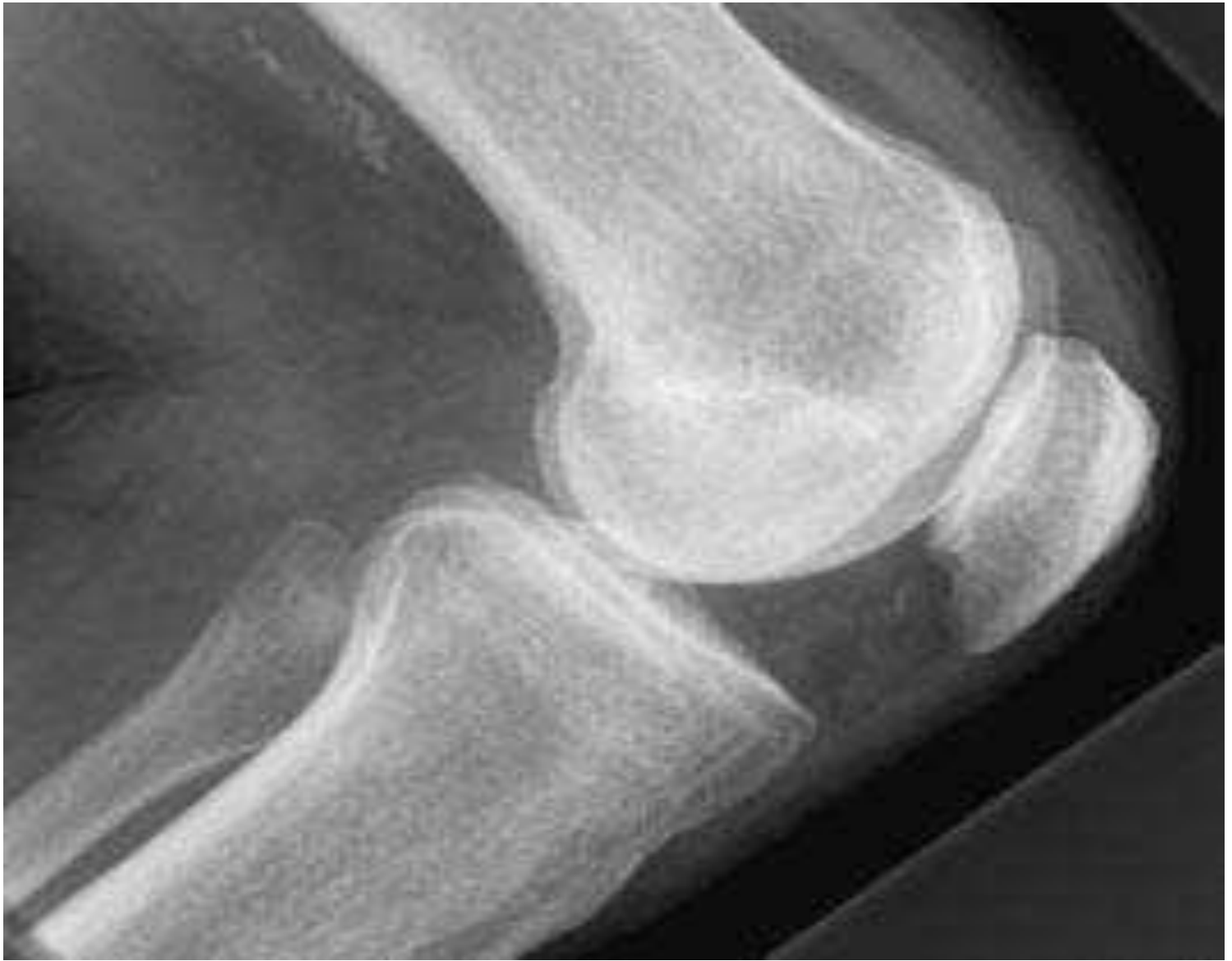- Centre to the **middle** of the superior border of the **medial tibial Condyle**



Essential image characteristics

- The patella should be projected clear of the femur.
- The femoral condyles should be superimposed.
- The proximal tibio-fibular joint is not clearly visible.





Antero-posterior – standing projection

This projection is **useful** to demonstrate **alignment** of the **femur** and **tibia** in the investigation of **valgus** or **varus** deformity.

It is commonly requested to assess alignment prior to joint replacement, as narrowing of one side to the joint space more than the other will produce varus or valgus tilt.

Both knees may be included for comparison

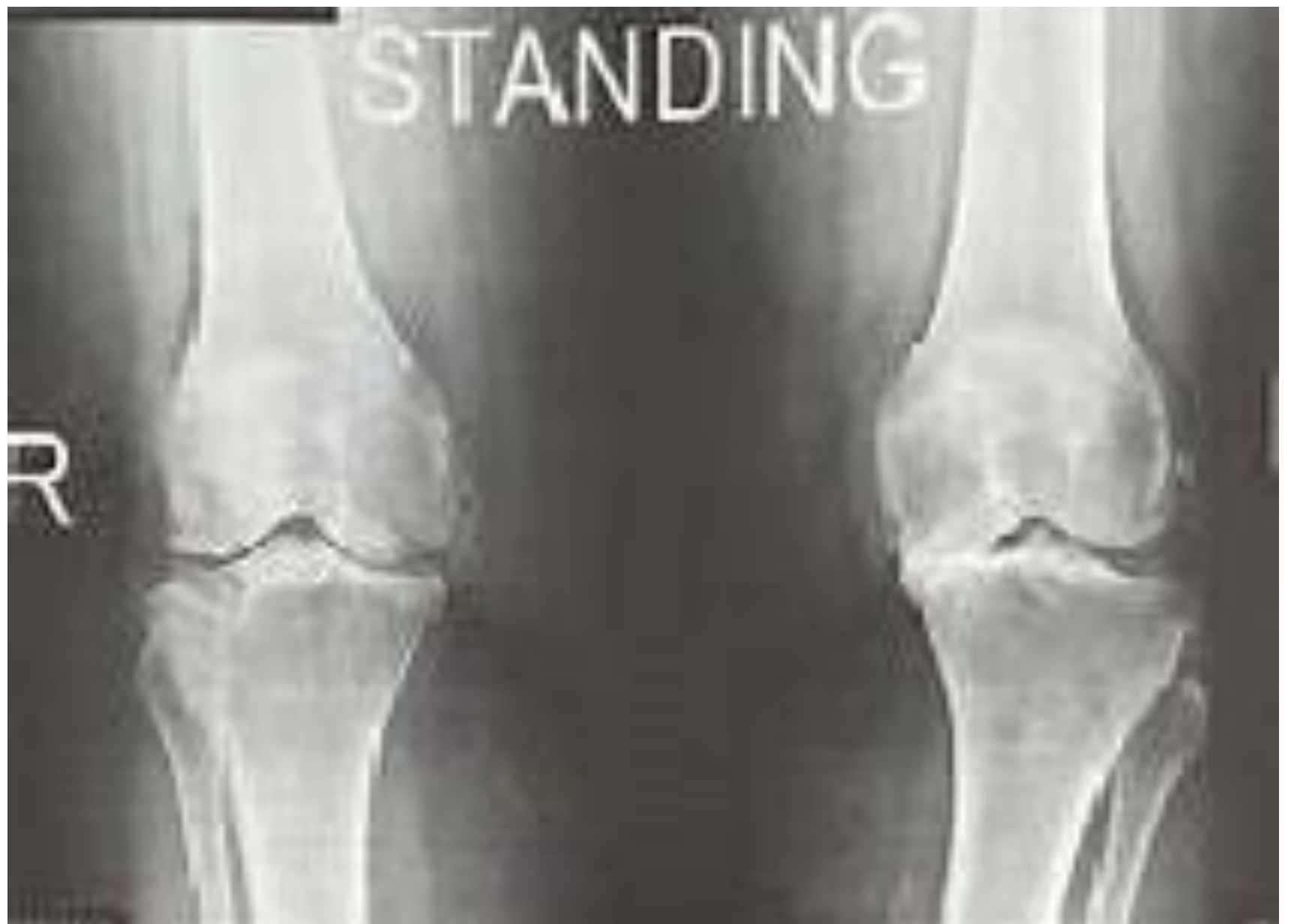

Position of patient and cassette

- The cassette is supported in the chest stand.
- The patient stands with their back against the vertical Bucky, using it for support if necessary.
- The patient's weight is distributed equally.
- The knee is rotated so that the patella lies equally between the femoral condyles.

Direction and centering of the X-ray beam

- The **horizontal** beam is **centred** midway between upper borders of the **tibial condyles**.



Skyline projections

On a sunrise view of the patella, a line is drawn between the highest points on the medial (M) and lateral (L) femoral condyles.

Three methods of skyline projection:

- conventional infero superior;
- supero-inferior – beam directed downwards;
- infero-superior – patient prone

conventional infero- superior

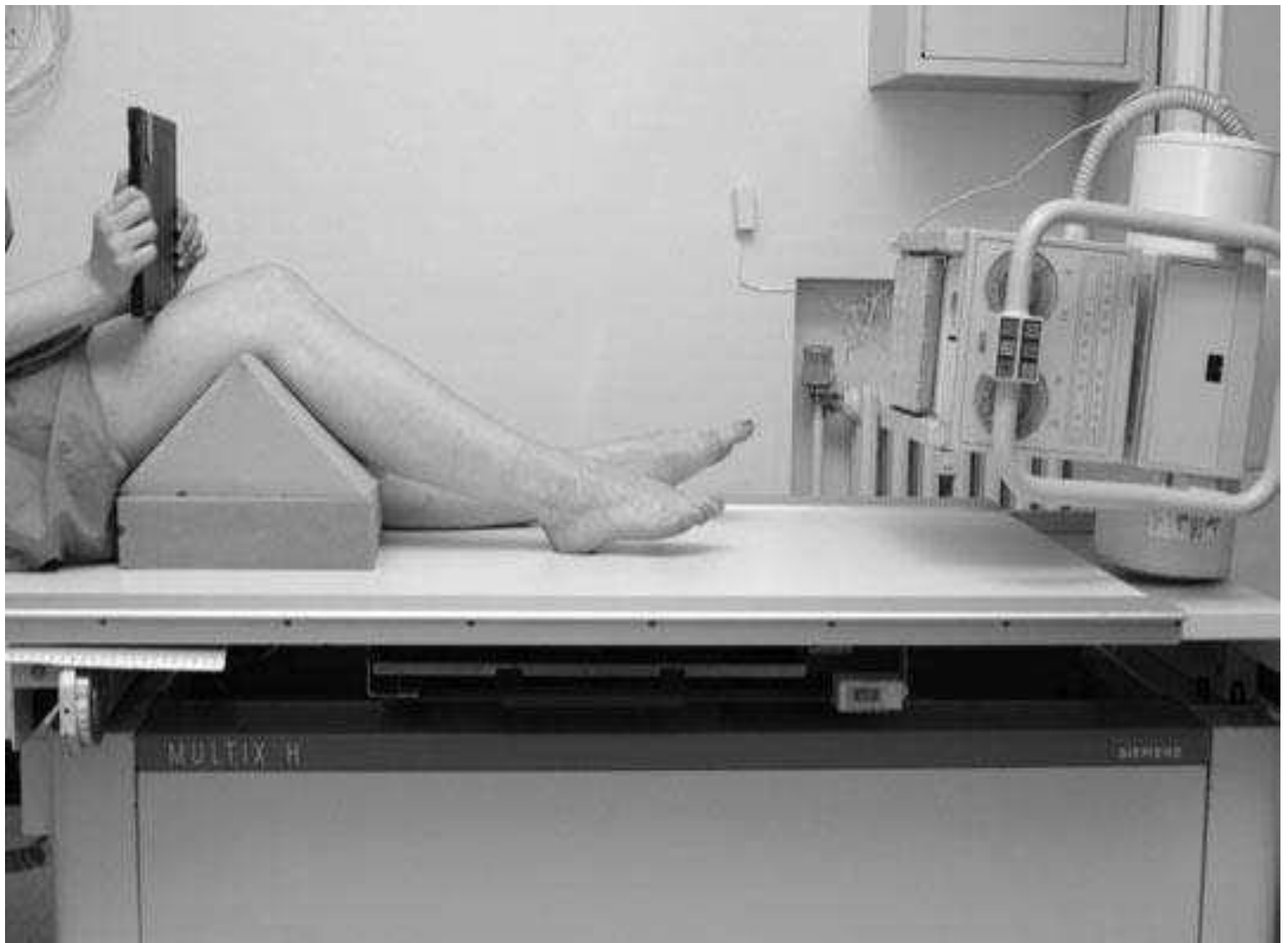
Position of patient and cassette

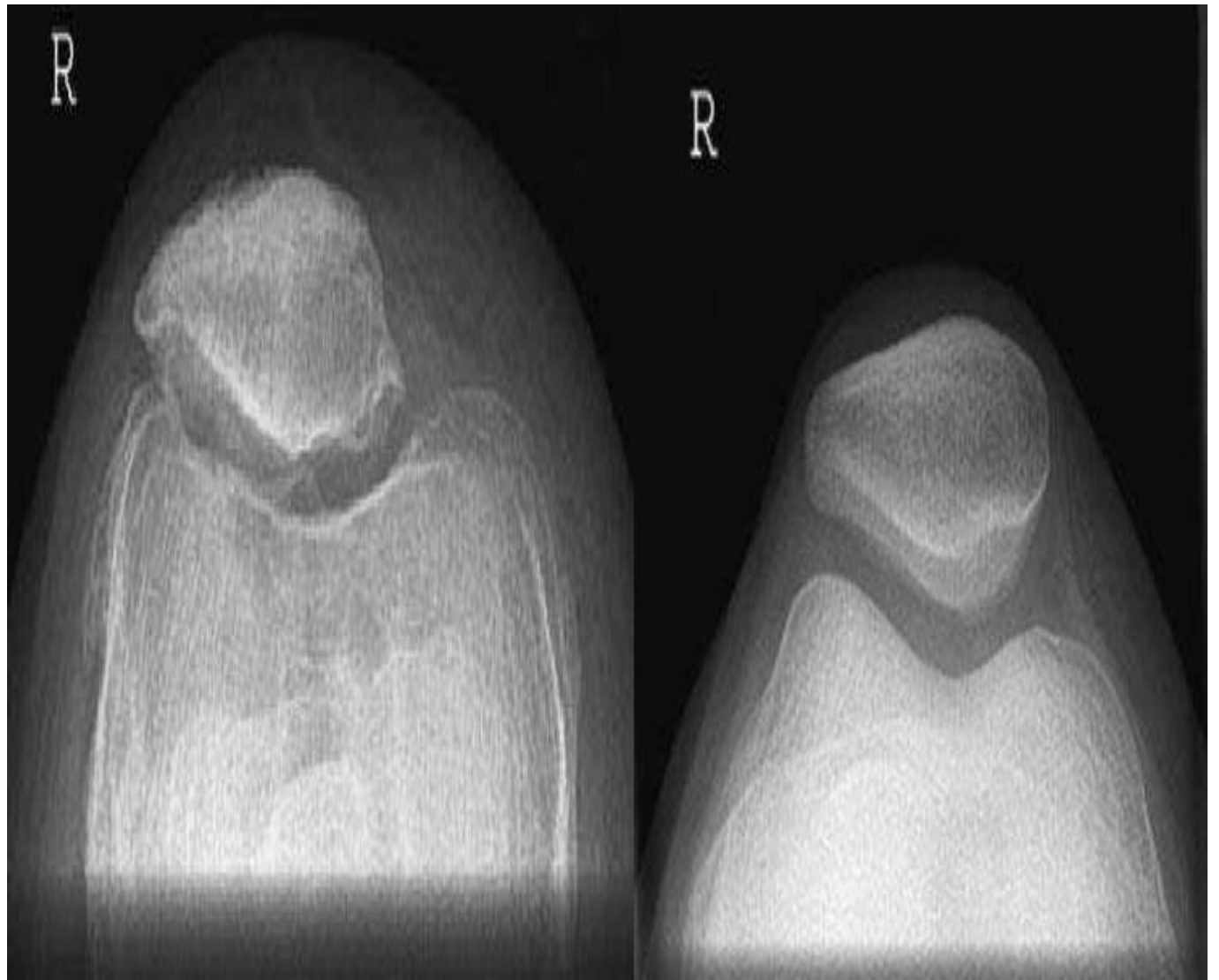- The patient sits on the X-ray table, with the knee flexed 30–45 degrees and supported on a pad placed
 - below the knee.
 - - A cassette is held by the patient which rests on the anterior aspect of the thigh against the anterior aspect of femur and supported using a non-opaque pad,



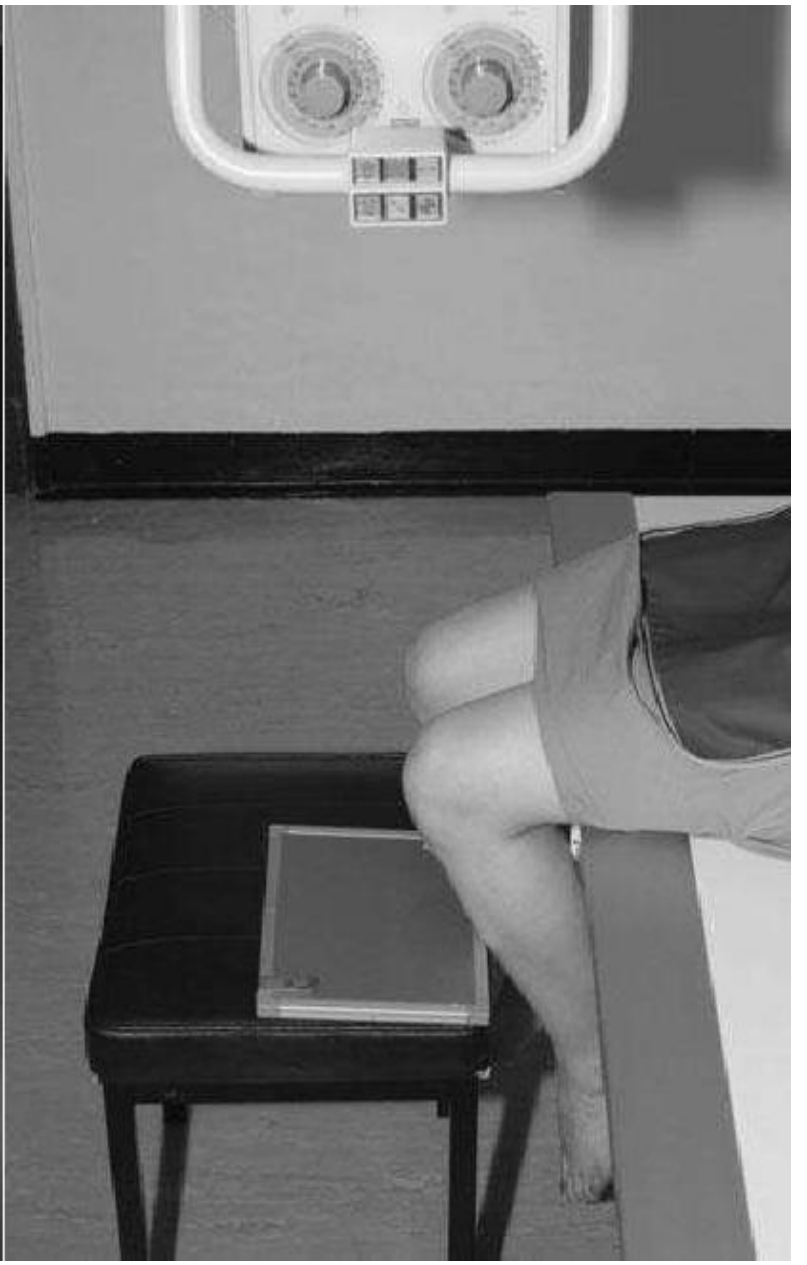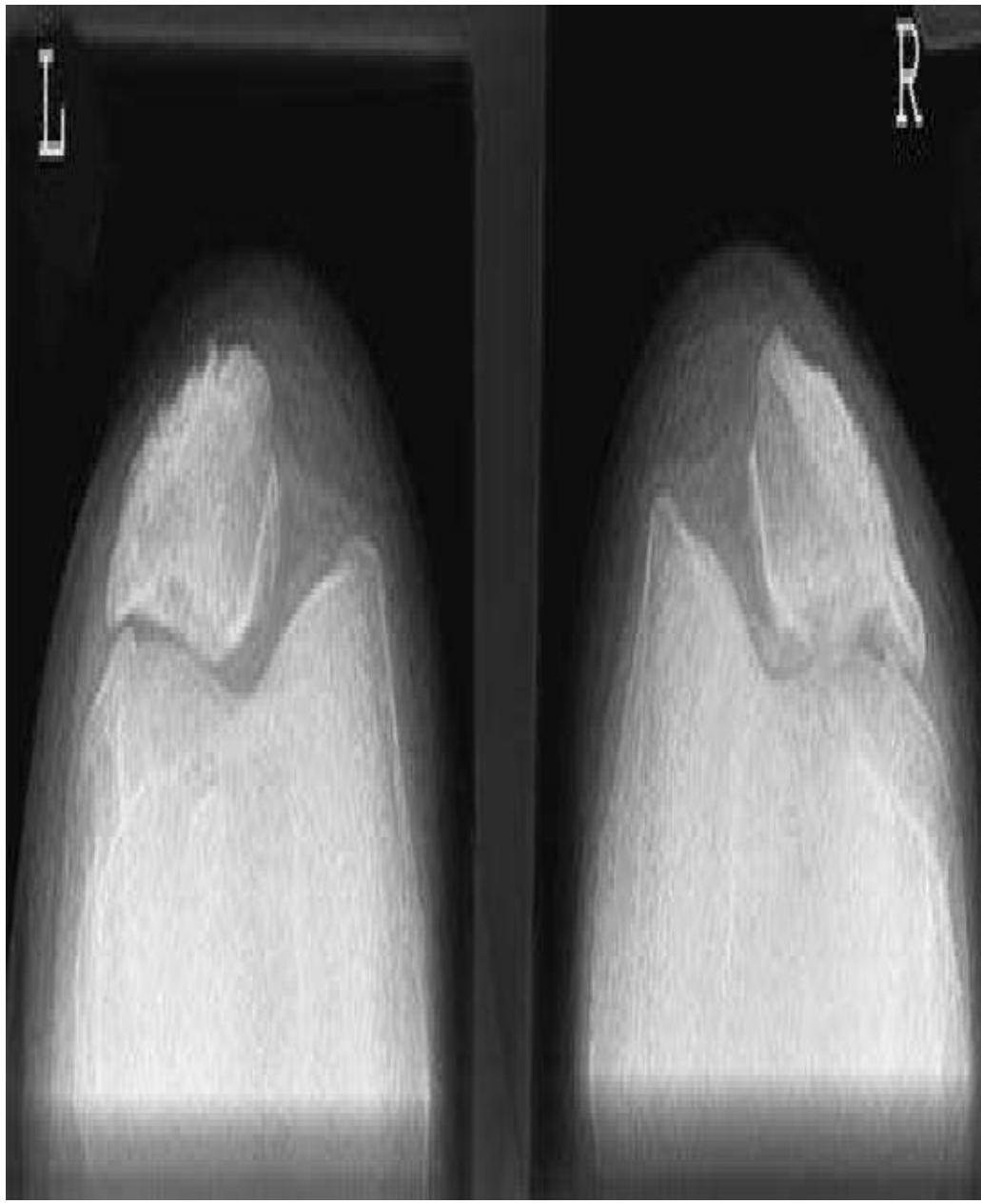Direction and centring of the X-ray beam

- The tube is lowered. Avoiding the feet, the central ray is directed cranially to pass through the apex of the patella





Conventional
infero-superior
projection
showing
osteophytosis
affecting the
retro-patellar
joint



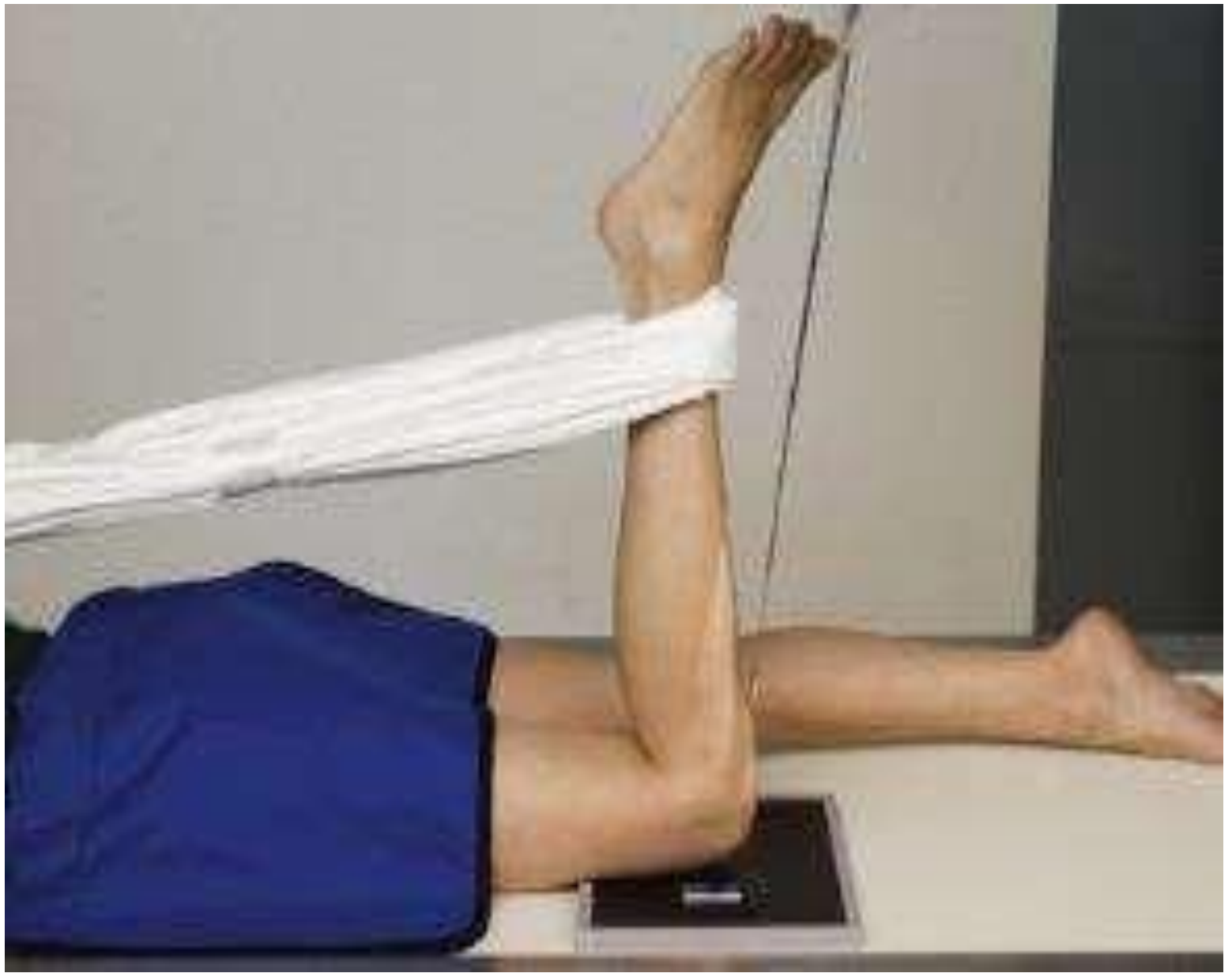Inferio-superior – patient prone

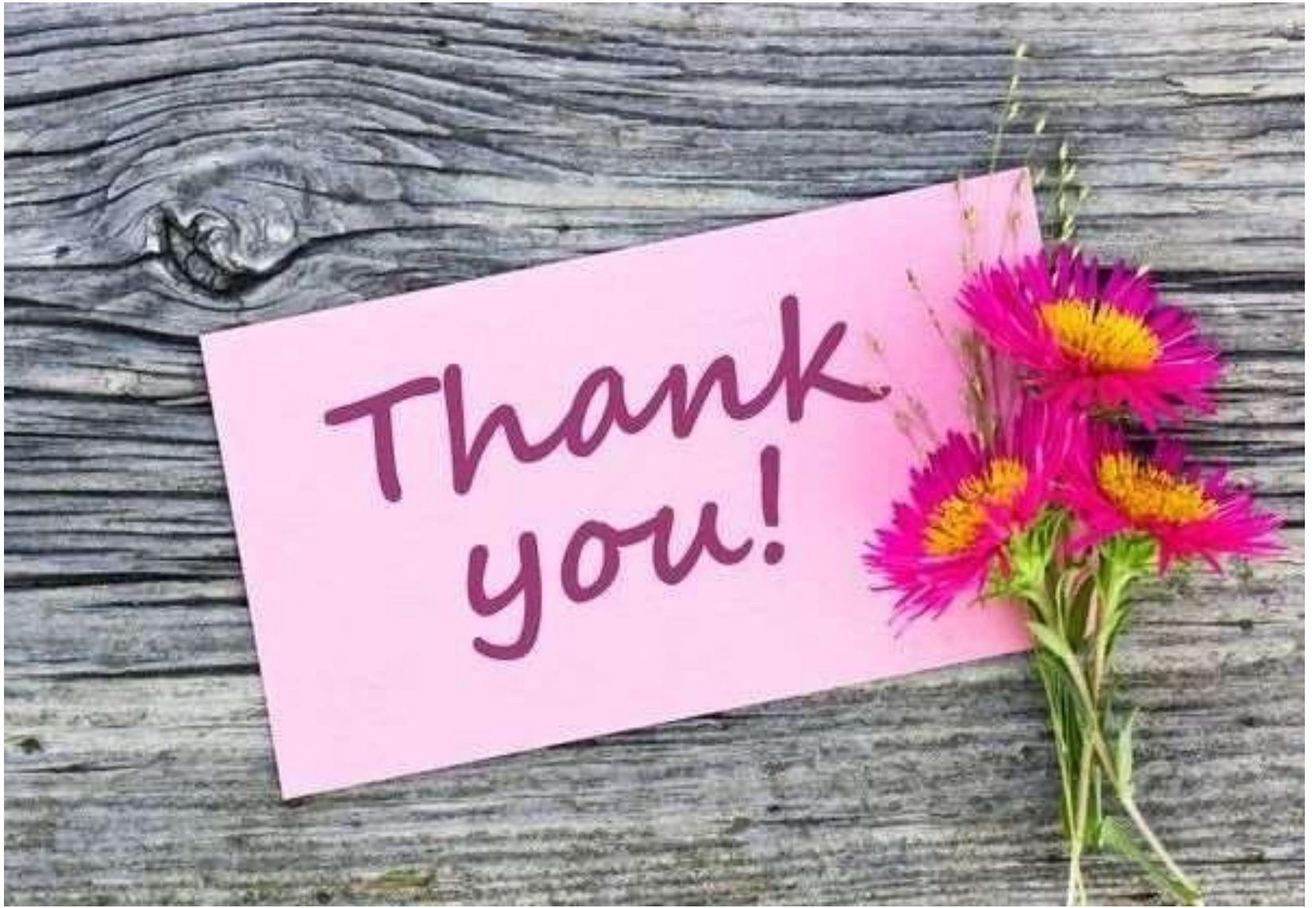Position of patient and cassette

- The patient lies prone on the X-ray table, with the cassette placed under the knee joint and the knee flexed through **90 degree**
- A bandage placed around the ankle and either tethered to a vertical support or held by the patient may prevent unnecessary movement.

Direction and centering of the X-ray beam

- Centre behind the patella, with the vertical central ray angled approximately 15 degrees towards the knee, avoiding the toes.







Radiology Techniques Department

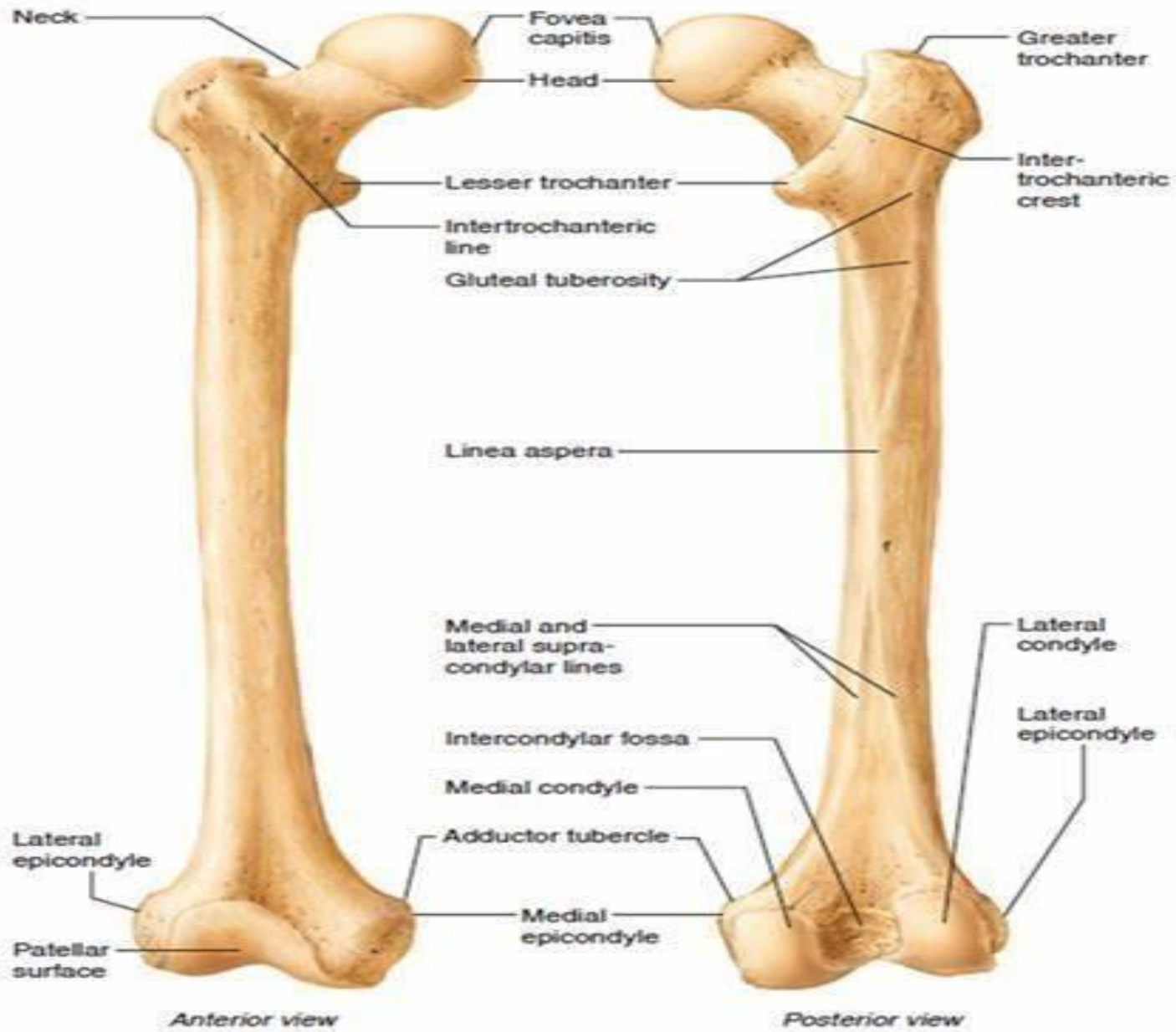
Radiographic imaging

Radiographic position of femur , pelvis and hip joint

Lecture 13

د. حيدر سعيد شندل

M.B.CH.B MSc. RAD. (ASU)



(b) Femur (thigh bone)

Shaft of Femur

Basic projections

- 1 Antero-posterior
- 2 Lateral

Antero posterior

Position of patient and cassette

- The patient lies **supine** on the X-ray table, with both legs extended and the affected limb positioned to the centre line of the table.
- The affected limb is rotated to centralise the patella over the femur.
- Sandbags are placed below the knee to help maintain the position.
- **Film size 6x15 , 12x15 or 14x17 inches**



Direction and center of the X-ray beam

- The collimated vertical beam is centred to the **mid-shaft of the femur**.

Essential image characteristics

- Ideally, the length of the femur should be visualised, including the hip and knee joints.

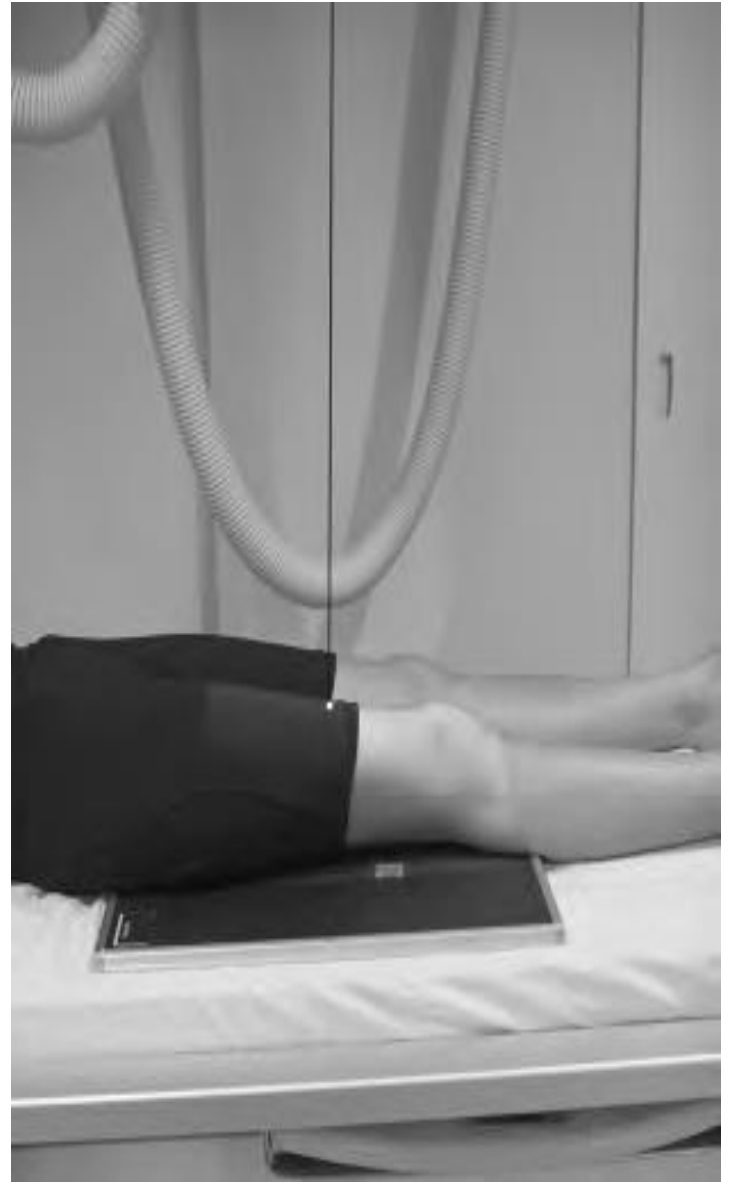
This may be difficult to obtain and an additional projection of the knee or hip joint may be required if coverage is not initially achieved; however, this will depend on the clinical information required.

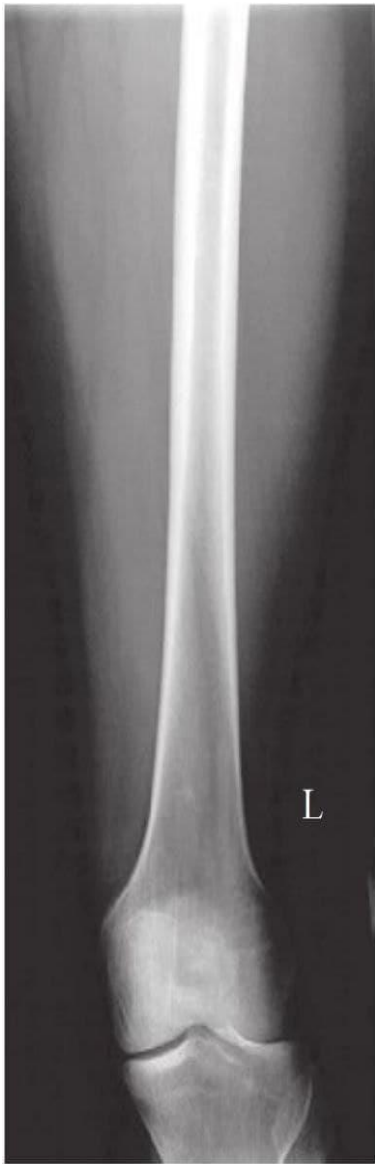

Fig. 5.7 AP.

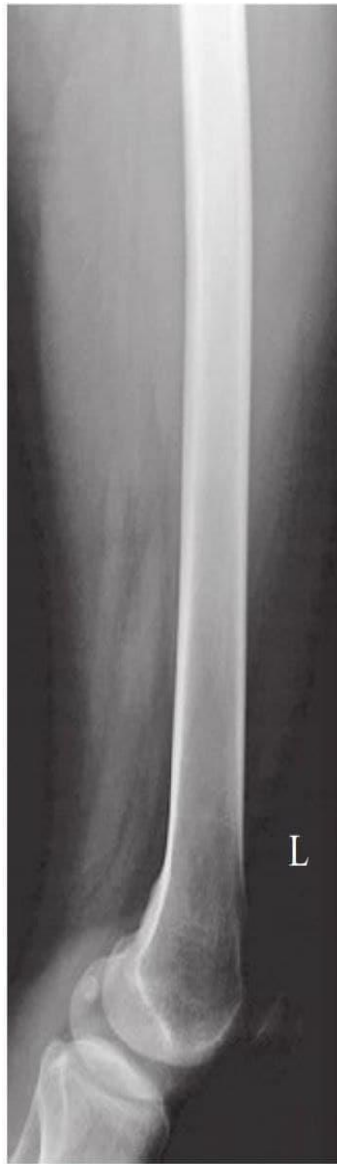

Fig. 5.8 Lateral.



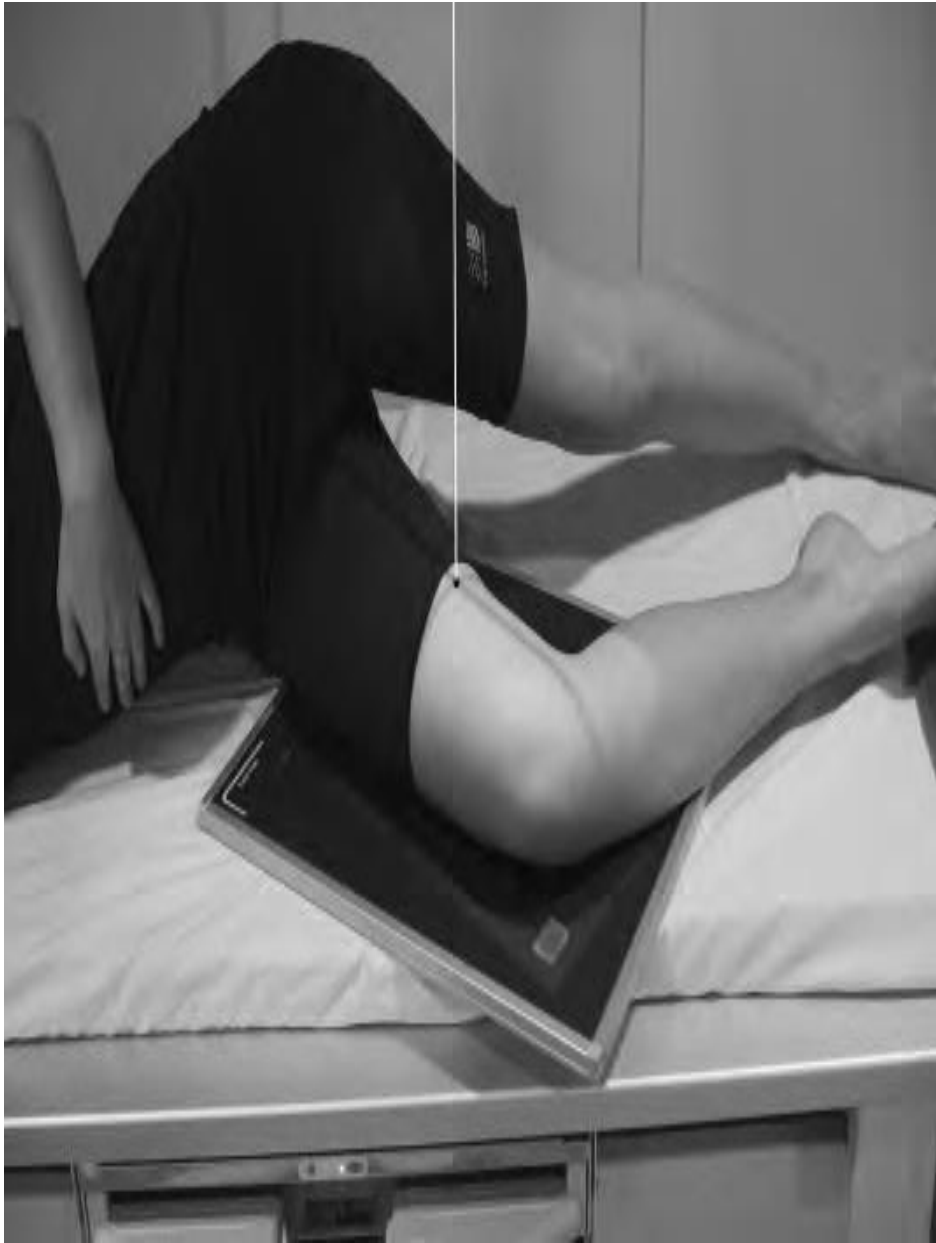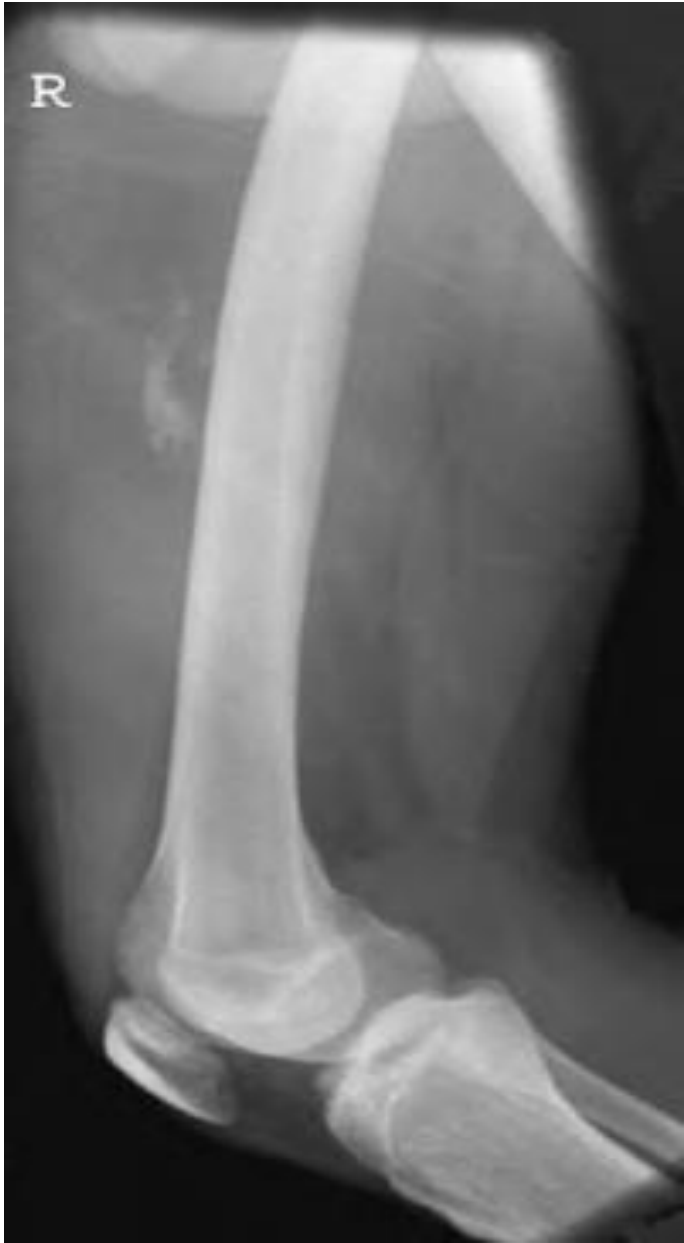Lateral

Position of patient and cassette

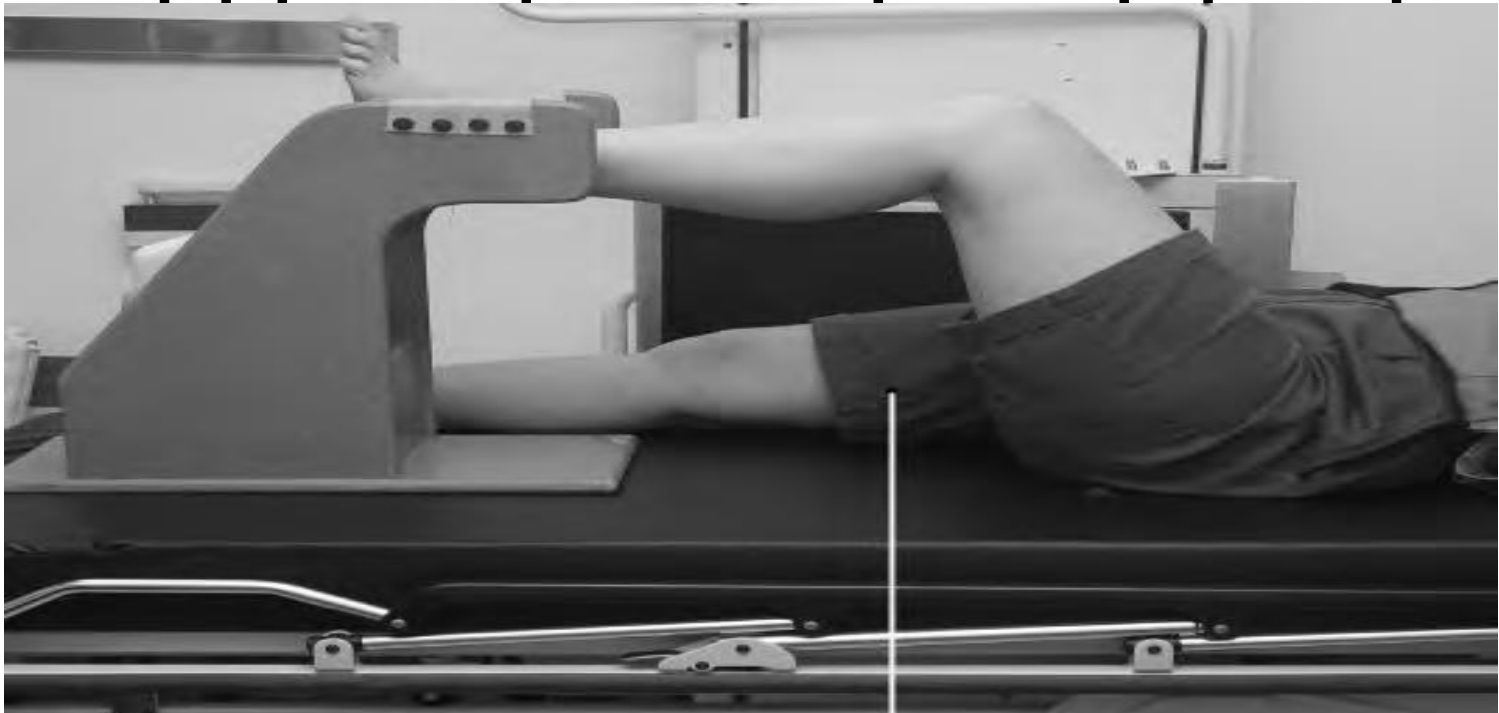
- From the anterior-posterior position, the patient **rotates** on to **the affected side**, and the knee is slightly flexed.
- The position of the limb is then adjusted to vertically superimpose the femoral condyles.
- Pads are used to support the opposite limb behind the one being examined.
- The cassette is positioned in the **Bucky** tray under the lateral aspect of the thigh to include the knee joint and as much of the femur as possible.

Direction and centering of the X-ray beam

- The collimated vertical beam is centred to the mid-shaft of the femur



This projection replaces the basic lateral in all cases of gross **injury** and suspected **fracture**





Position of patient and image receptor

- The patient remains on the **trolley/bed**. If possible, the leg may be slightly rotated to centralise the patella between the femoral condyles.
- The vertical image receptor is positioned against the **lateral aspect** of the thigh, with the lower border of the receptor level with the upper border of the tibial condyle
- The **unaffected limb** is raised above the injured limb, with the knee flexed and the lower leg supported on a stool or specialised support.



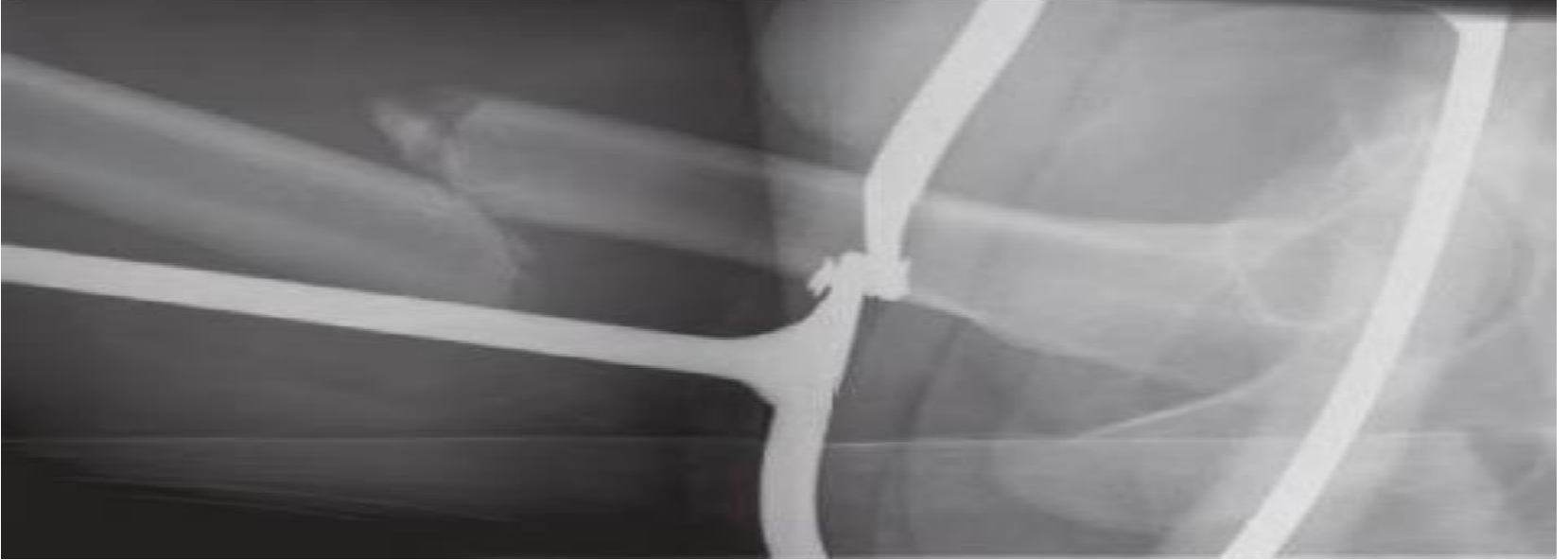

Direction and location of the X-ray beam

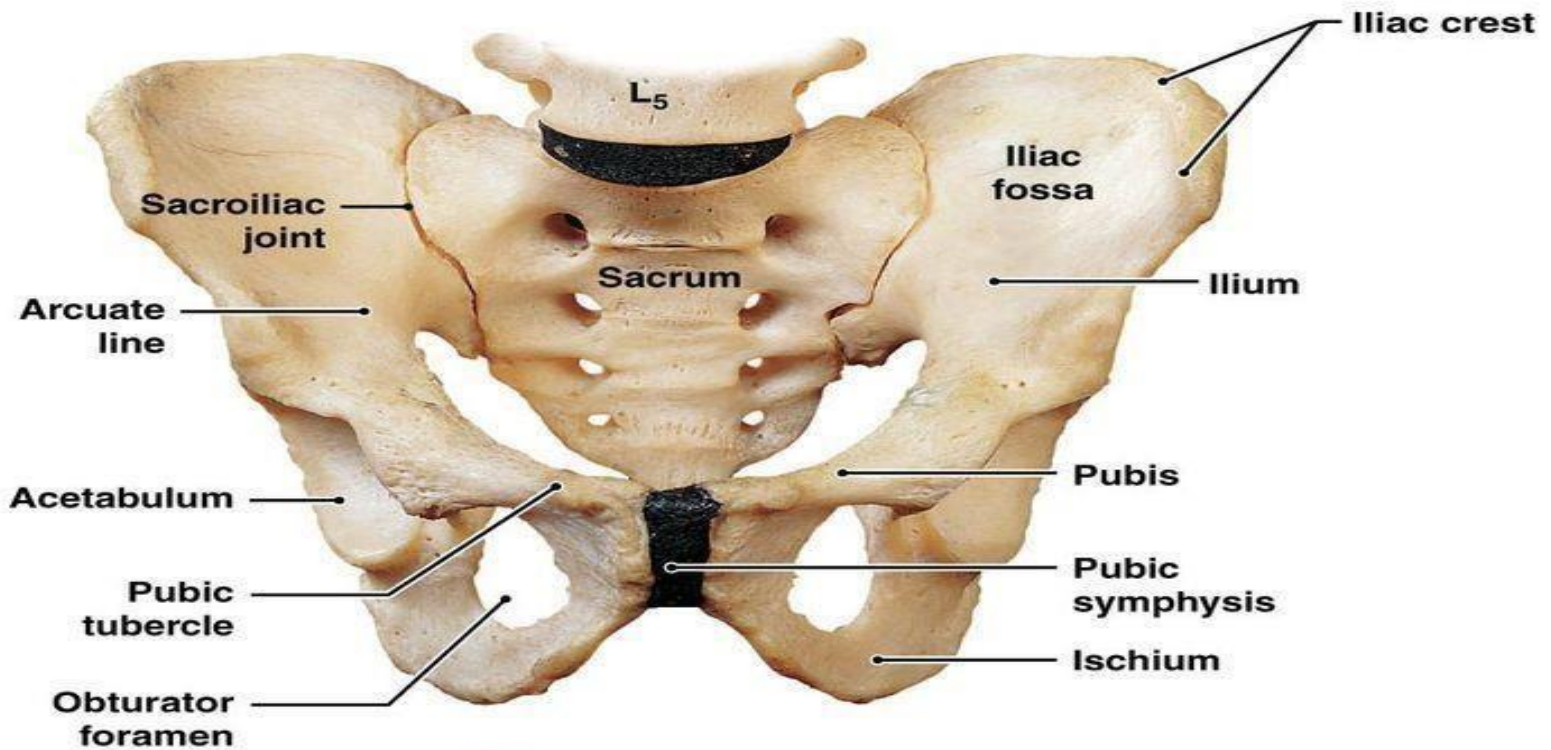
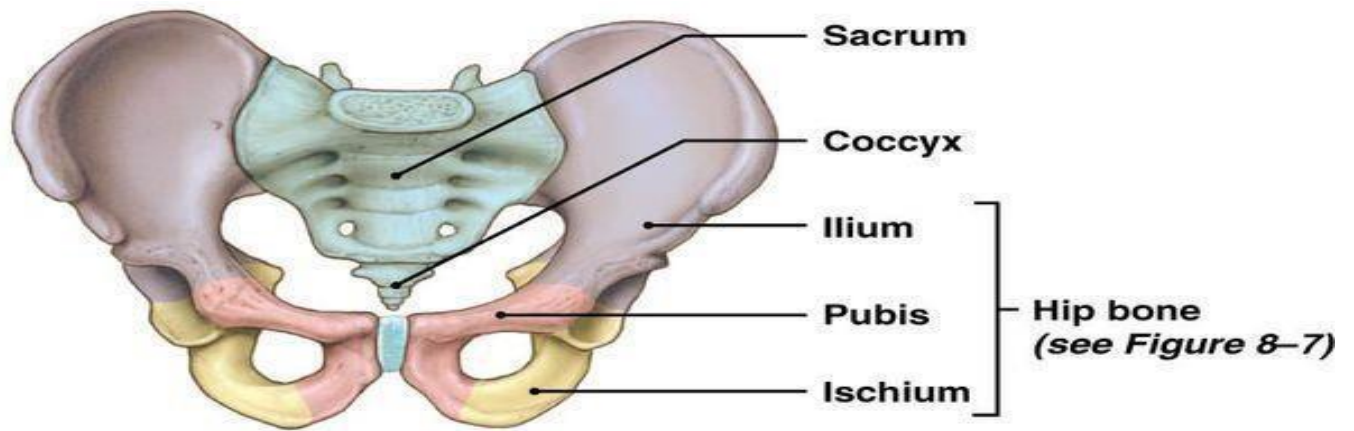
-The collimated **horizontal** beam is directed to the mid **shaft** of the **femur**, to include as much of the proximal shaft as possible

Essential image characteristics

-The knee joint and **distal 2/3** of the femur should be included.

-The knee should be in a true lateral position, with broad superimposition of the **femoral condyles**.





a Anterior view

pelvis

Antero-posterior (basic projection)

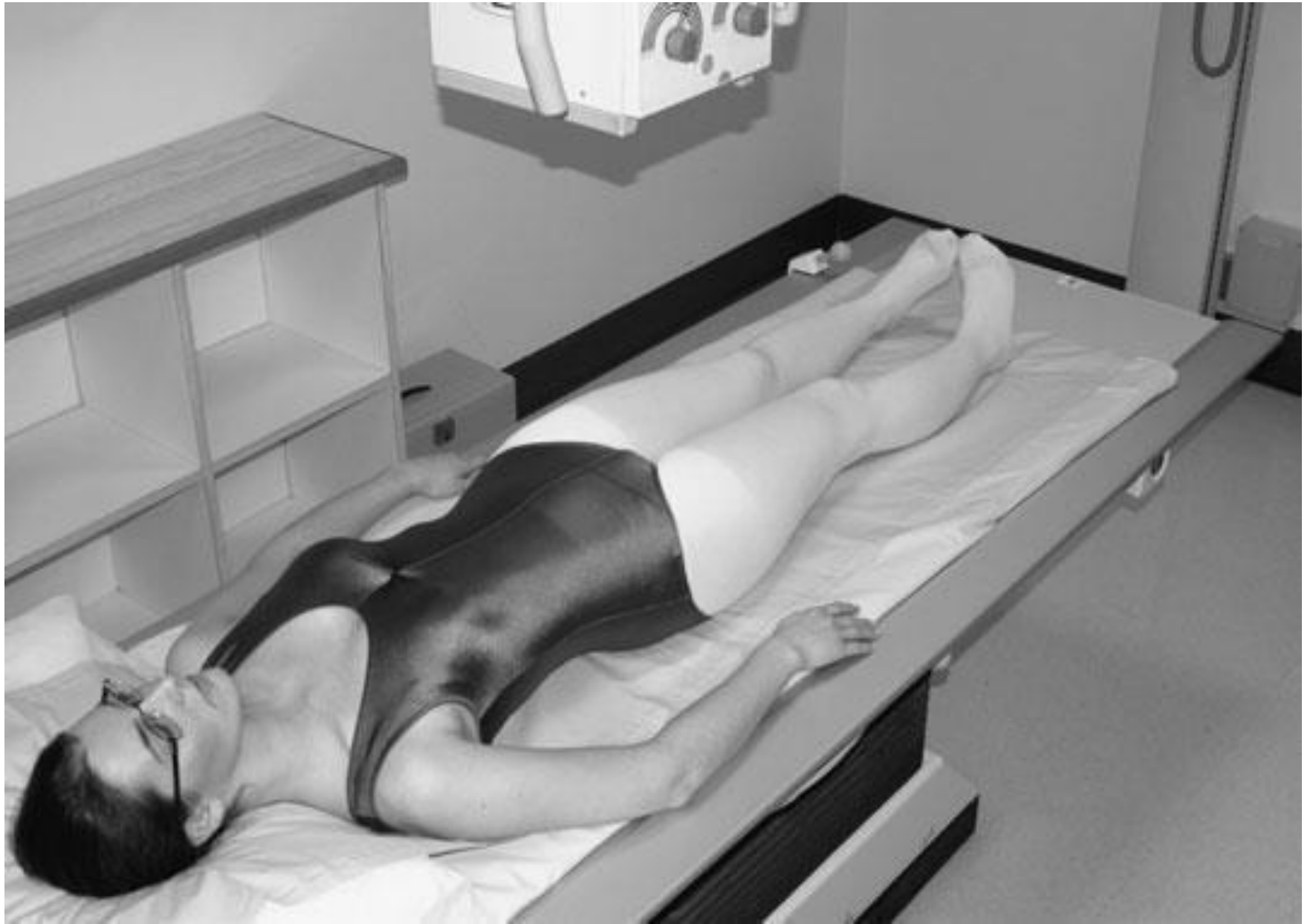Position of patient and cassette

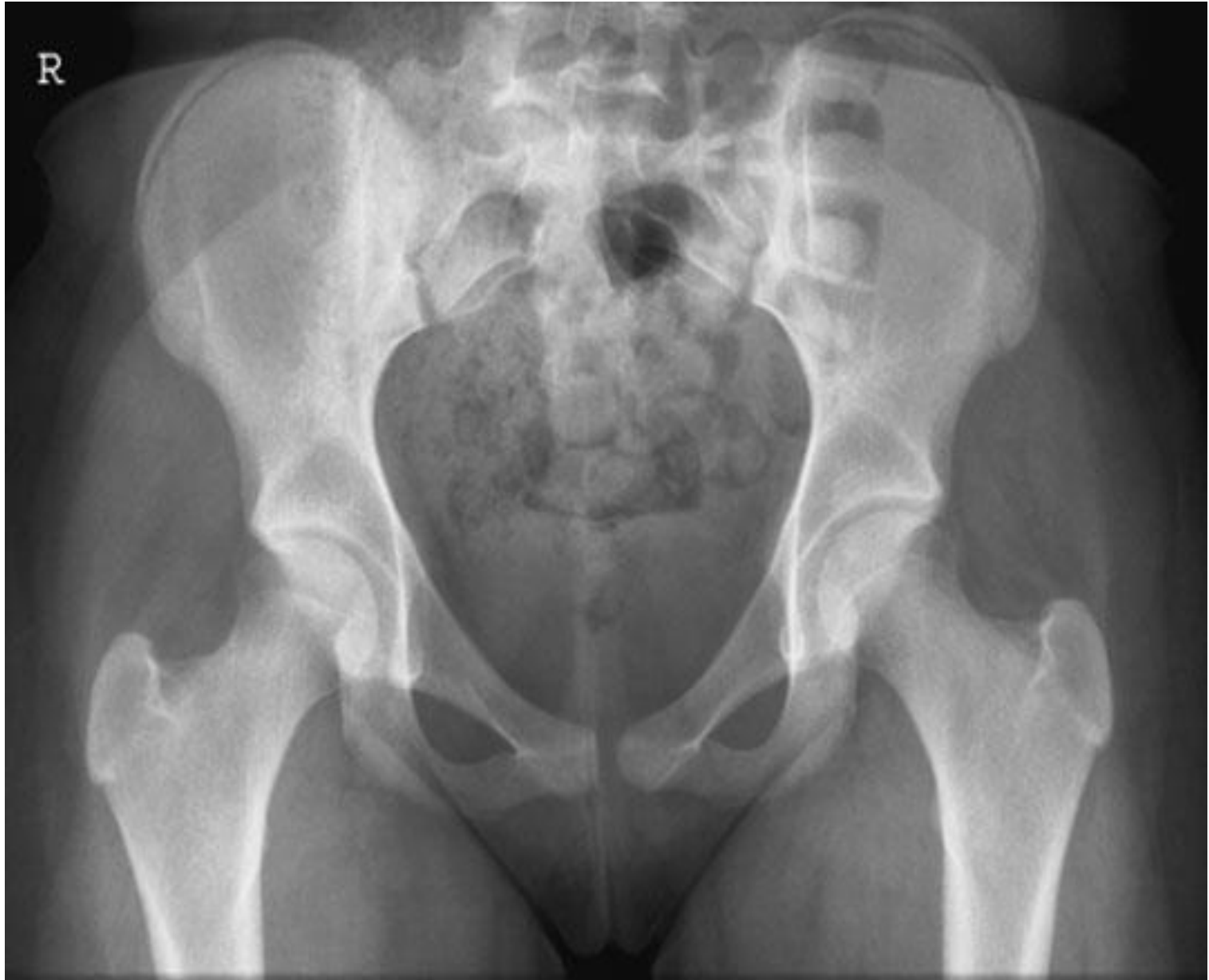- The patient **lies supine** and symmetrical on the X-ray table.
- The limbs are slightly abducted and **internally** rotated to bring the femoral **necks parallel** to the cassette.
- Sandbags and pads are placed against the ankle region to help maintain this position.



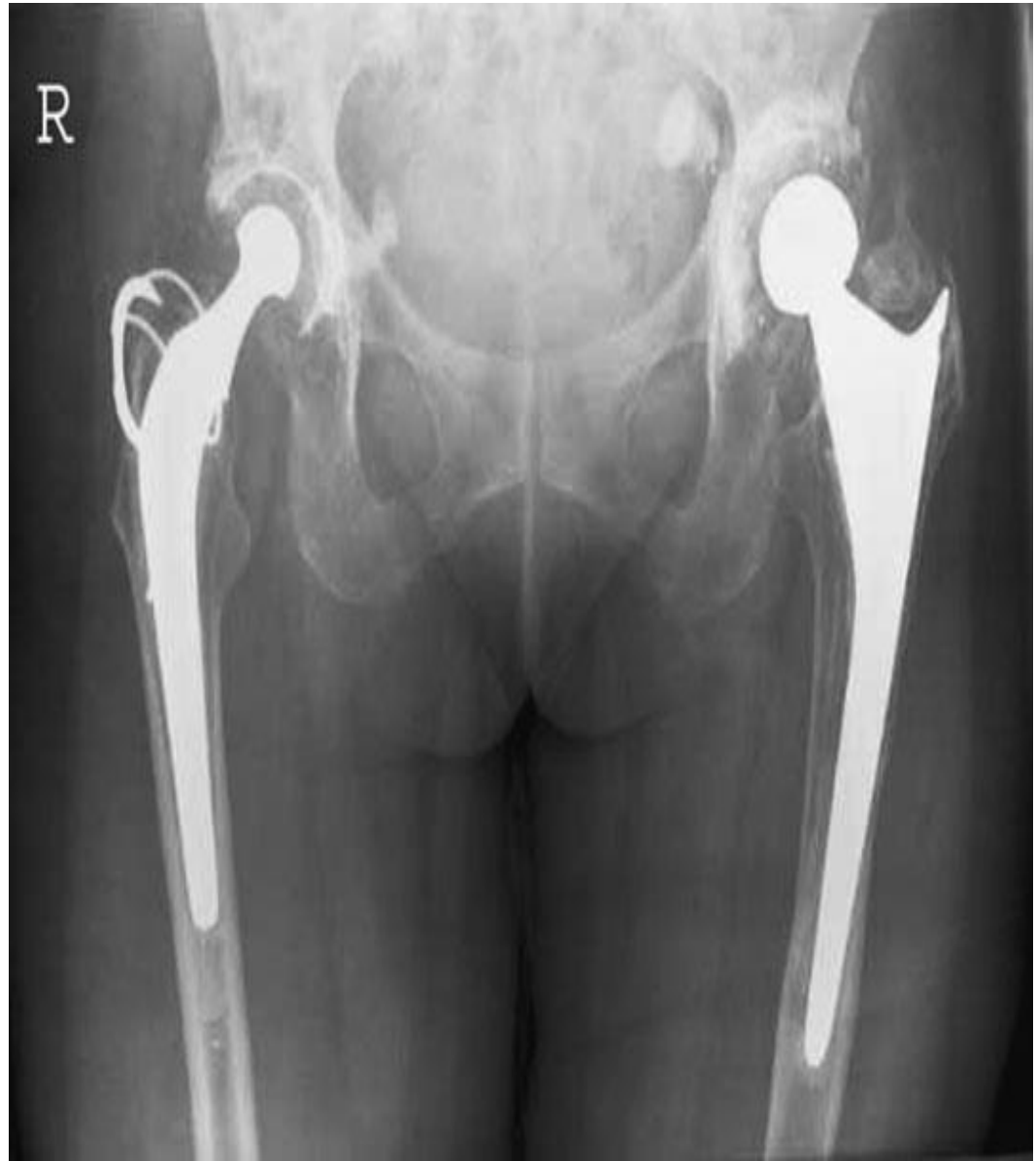Direction and centering of the X-ray beam

- Center in the midline, with a **vertical** central beam.
- The center of the cassette is placed midway between the **upper border** of the **symphysis** pubis and anterior superior iliac spine.

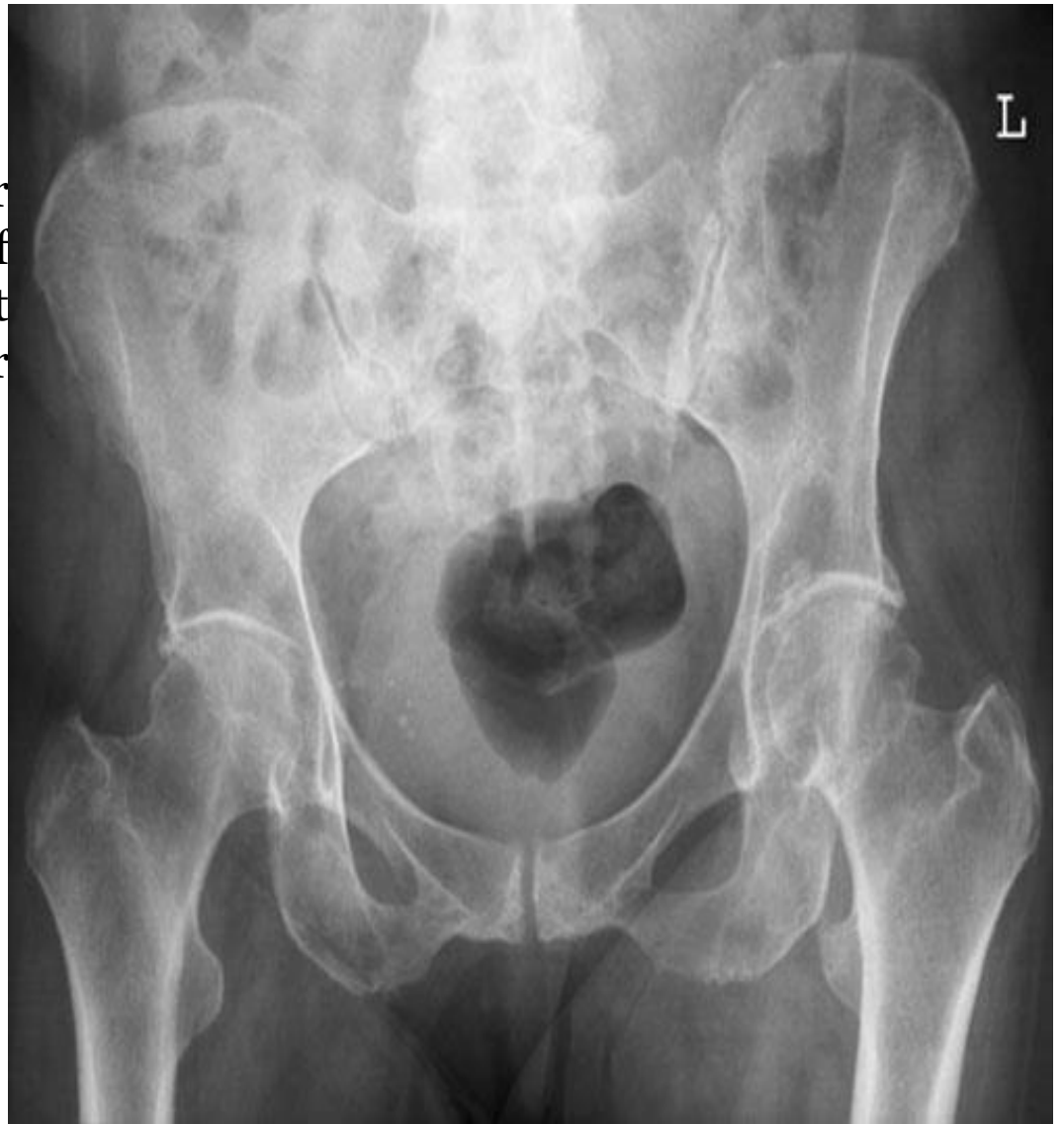



Antero-posterior radiograph
of both hips and upper
femora showing bilateral
prosthesis



Antero- posterior
radiograph showing fracture of
the neck of the left
femur



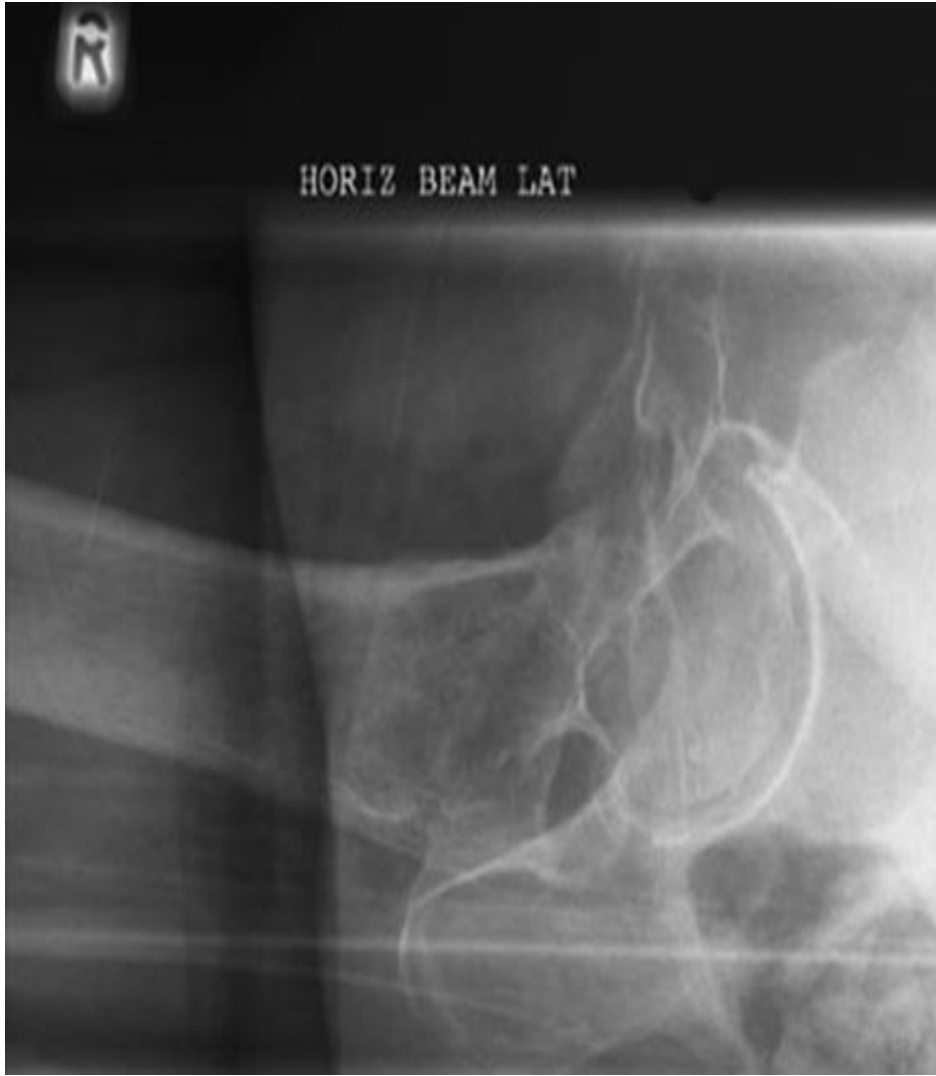hip joint-Lateral

Position of patient and cassette

- The patient lies **supine** on the X-ray table, with the affected leg extended
- The **unaffected limb** is then raised until the thigh is **vertical**, with the **knee flexed**.
- A (12 × 10inch) cassette is used.

Direction and centering of the X-ray beam

- Centre to the **head of femur**



lateral- both hips(frog's legs)

The frog-leg position is an essential posture for newborns

Position of patient and cassette

-The hips and knees are flexed and the limbs rotated laterally through approximately **60 degrees**. This movement separates the knees and brings the plantar aspect of the **feet** in **contact** with each other.

-The limbs are supported in this position by pads and sandbags.

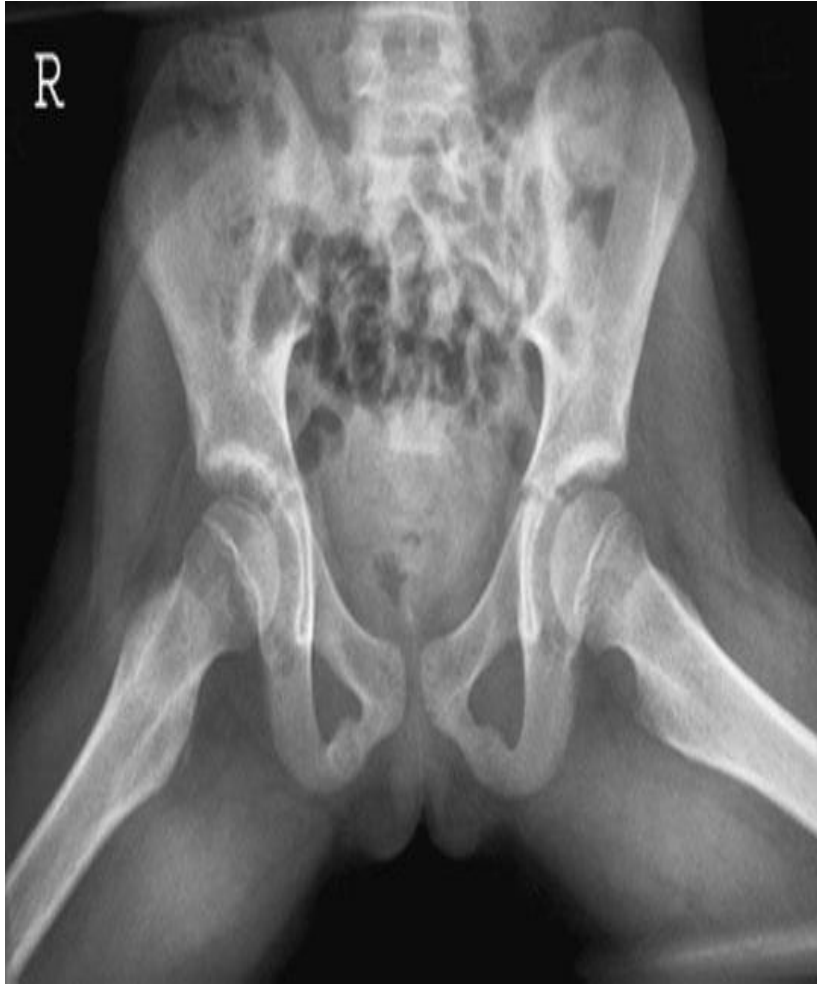Direction and centering of the X-ray beam

- Centre in the midline at the level of the **femoral head**.



Essential image characteristics

- The entirety of the bony pelvis is imaged from superior of the iliac crest to the proximal shaft of the femur
- The femoral heads and necks and trochanters should appear symmetric if both thighs are abducted equally



Anterior oblique('Judet's' projection)

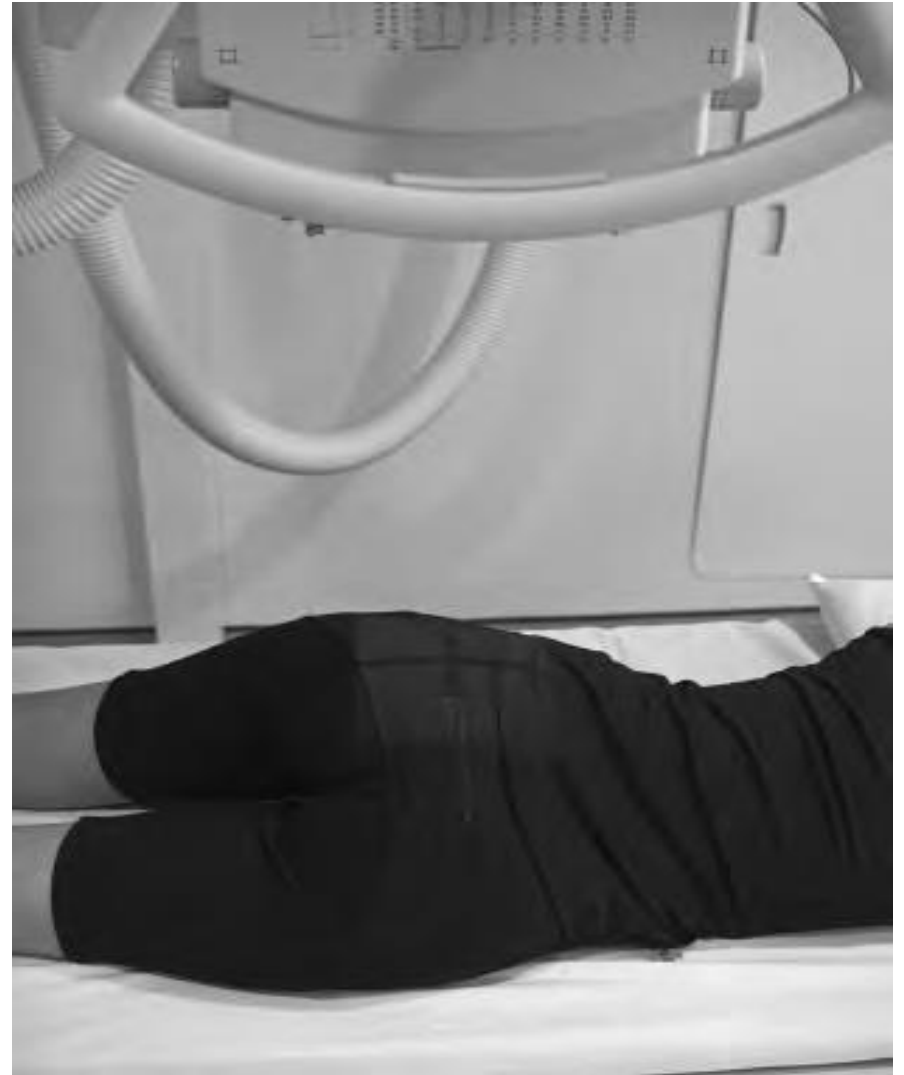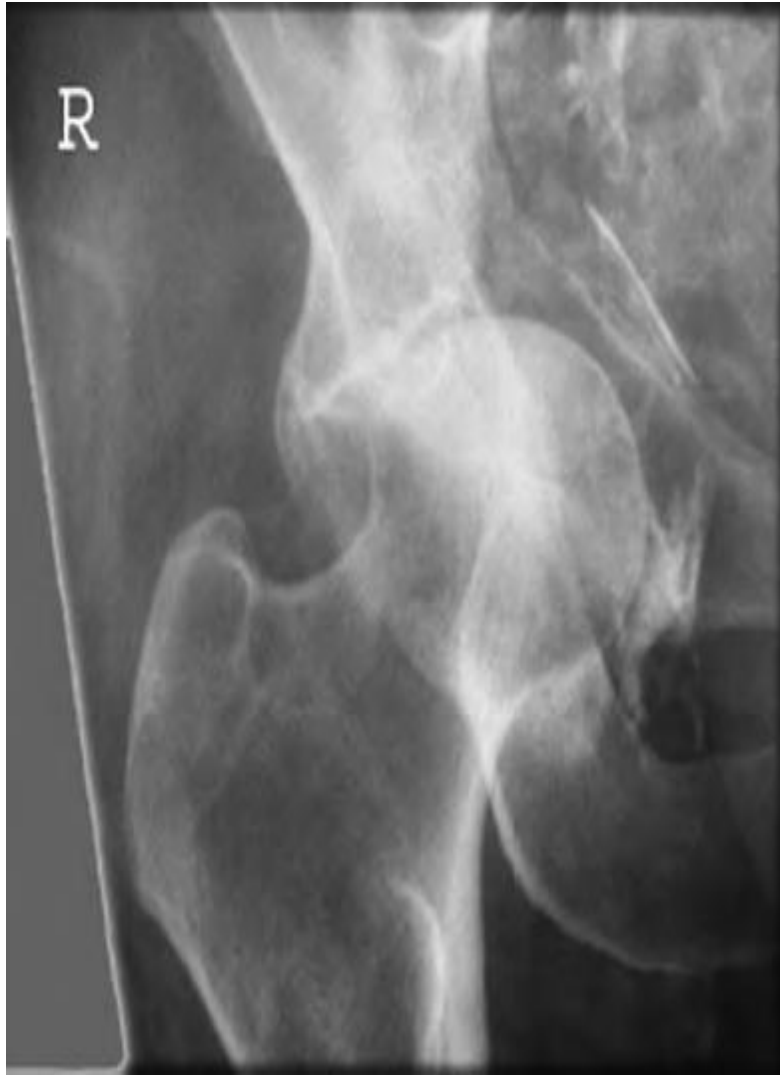Acetabulum and hip joint

Position of patient and image receptor

- The patient lies prone on the X-ray table.
- The trunk is then rotated approximately 45° onto the unaffected side and the affected side is raised and supported on non-opaque pads.
- In this position the rim of the acetabulum nearest the tabletop is approximately parallel to the image receptor.

Direction and location of the X-ray beam

- The collimated beam is centred just **distal to the coccyx** with the central beam **directed 12° towards the head**



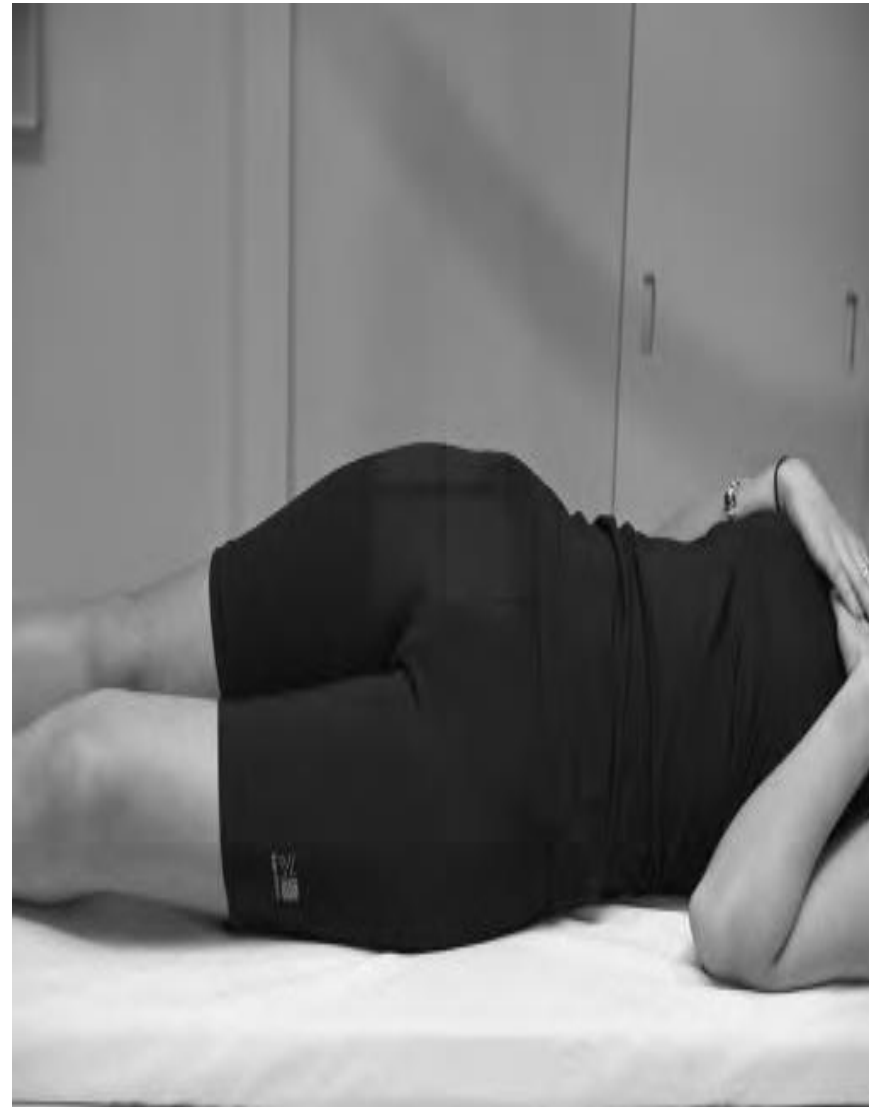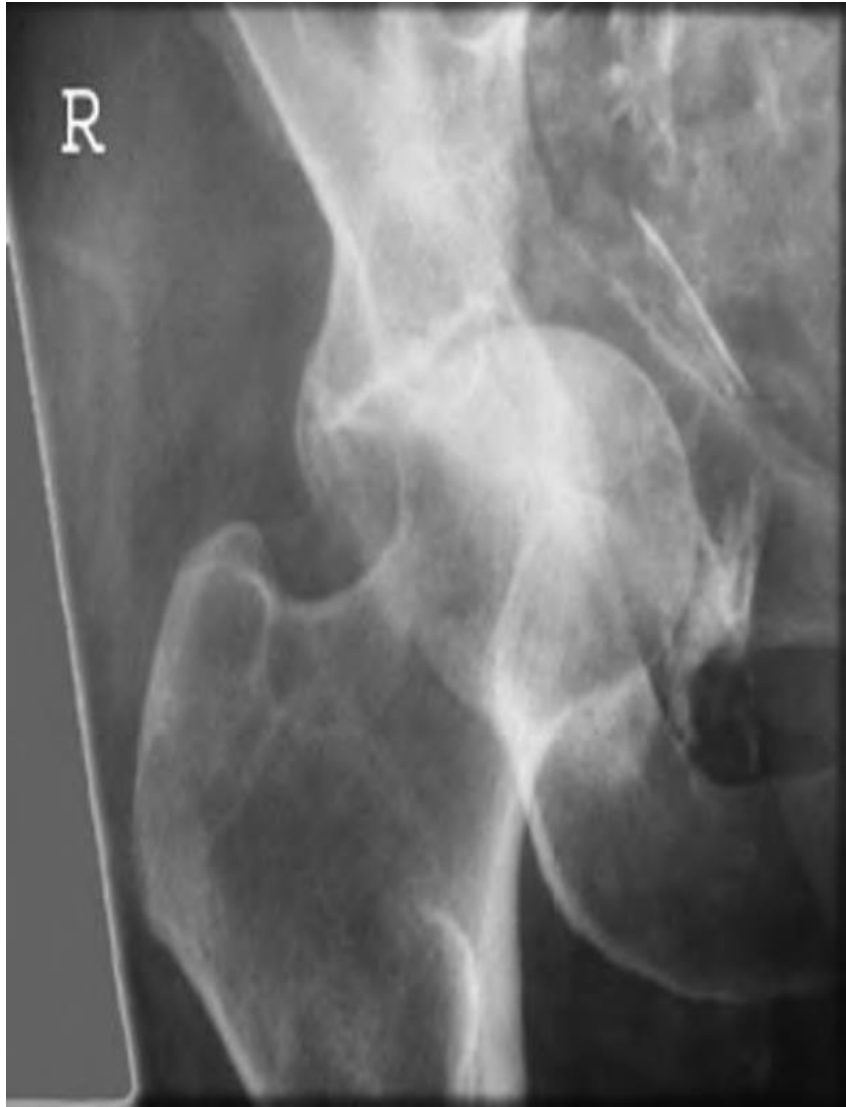Posterior oblique('reverse Judet's' projection(

Position of patient and image receptor

- The patient lies supine on the X-ray table.
- The AFFECTED SIDE is raised approximately 45° and supported on non-opaque pads.
- The image receptor is centred at the level of the femoral pulse.

Direction and location of the X-ray beam

- The collimated vertical beam is centred to the femoral pulse on the raised side with the central ray directed 12° towards the feet.



Thank
you!



